

Dermatología y Dermatopatología en tiempos de Pandemia

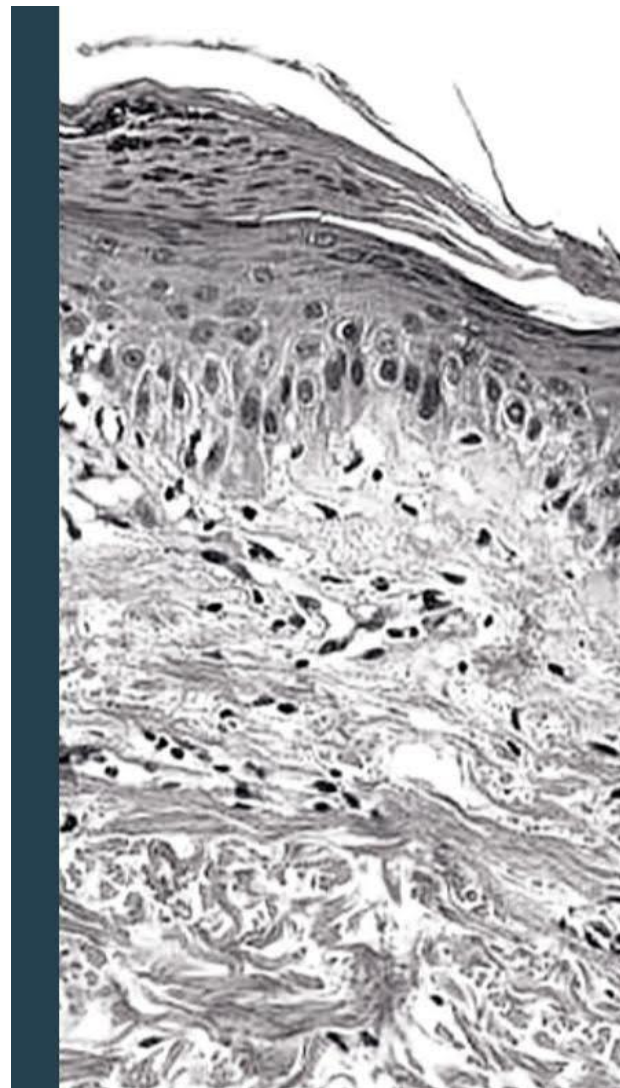
DR. JUAN CARLOS GARCÉS

Hospital Oncológico Nacional Dr. Juan Tanca Marengo

Hospital Luis Vernaza

Hospital Clínica Kennedy

Guayaquil, Ecuador



SCHAP Sociedad Chilena de
Anatomía Patológica

Modalidad online

JORNADAS DE ACTUALIZACIÓN 2020

CLAVES HISTOPATOLÓGICAS EN DERMATOPATOLOGÍA NO NEOPLÁSICA

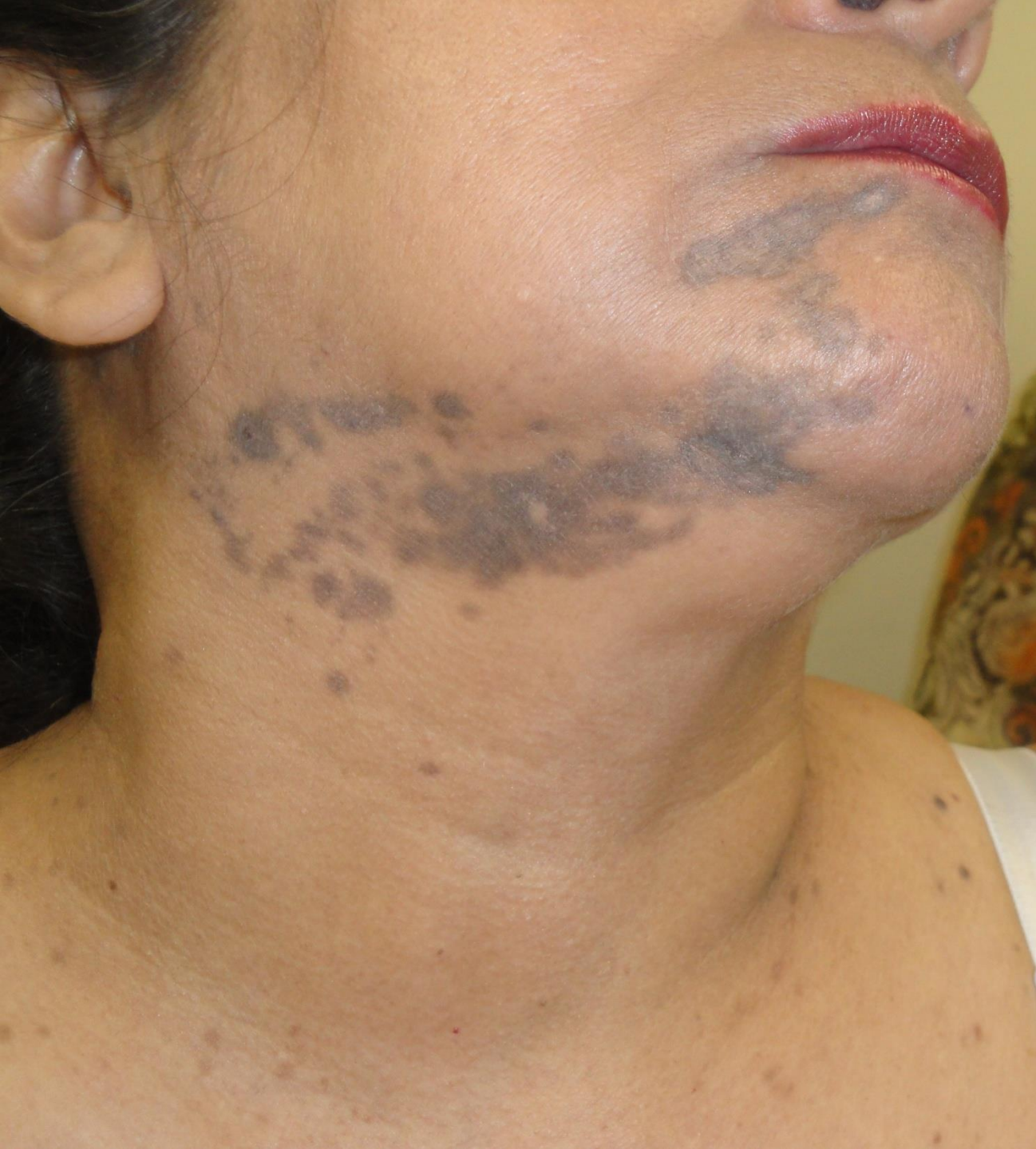22 julio 2020 - 19:00 hrs
Registro en www.schap.cl

Dermatitis de Interfaz



Fotografías clínicas cortesía

Dr Enrique Loayza



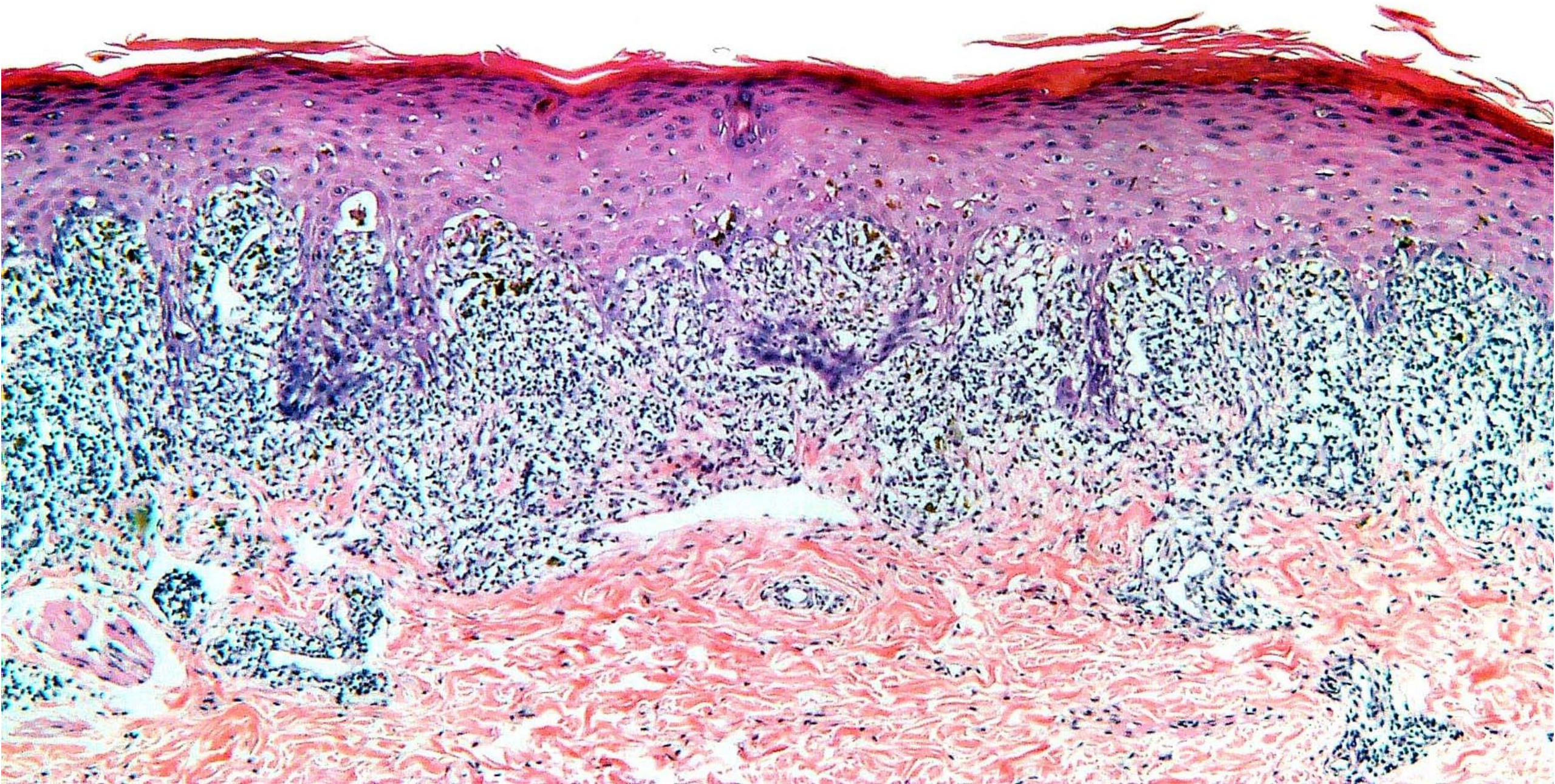
55 años

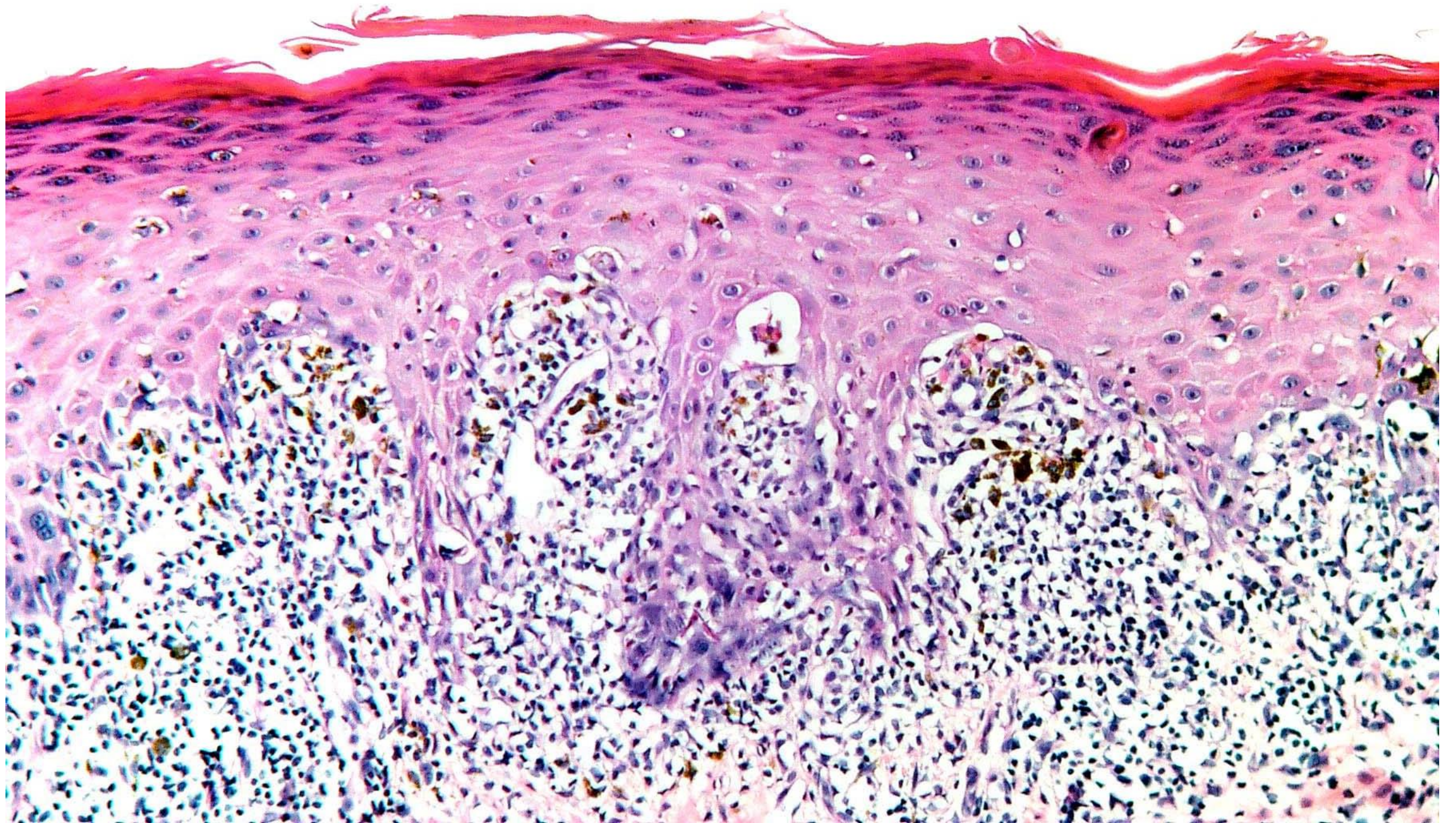
6 meses de evolución

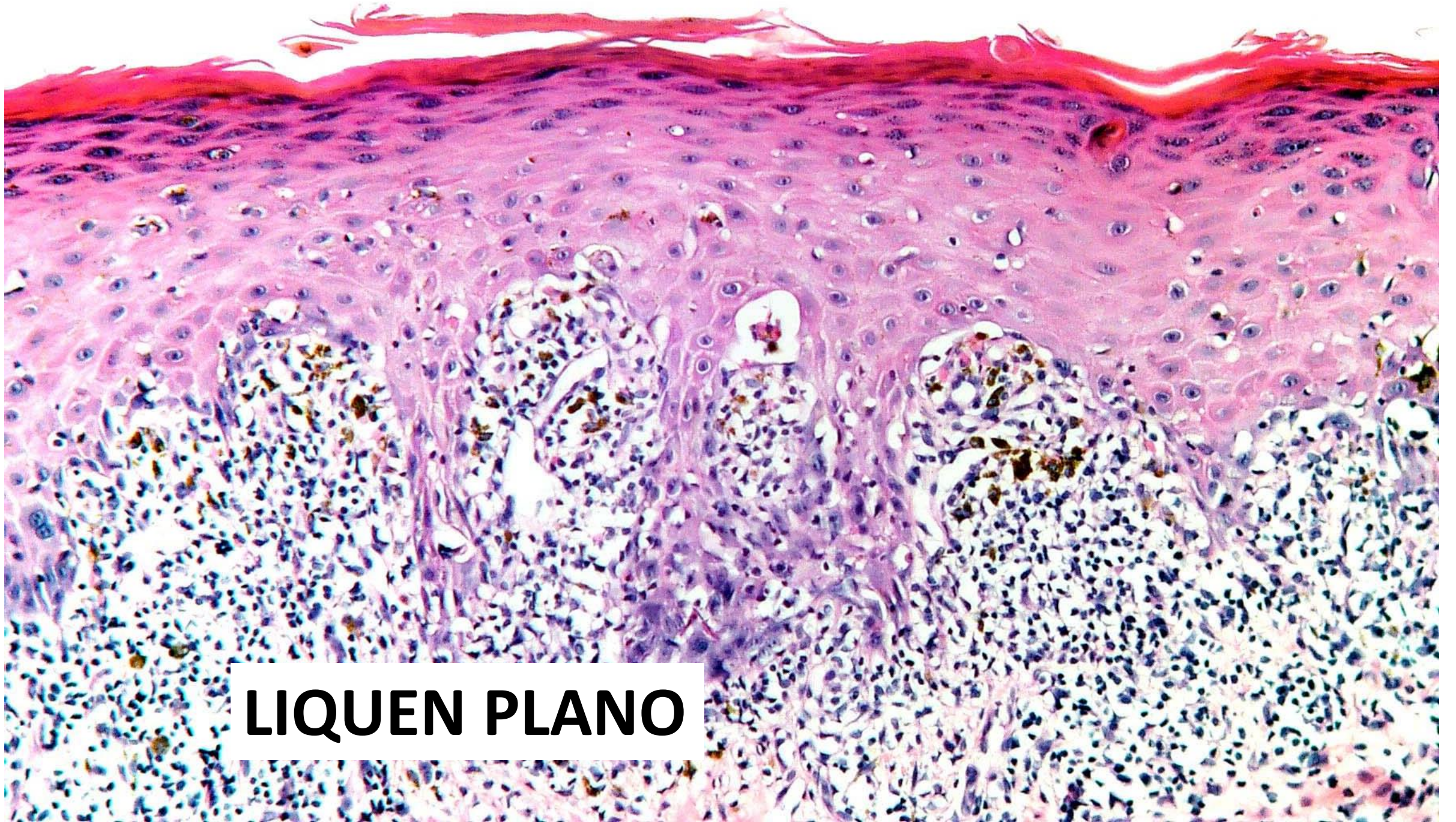Máculas pigmentadas, azul
grisáceas, algo marronáceas

Algunas aisladas

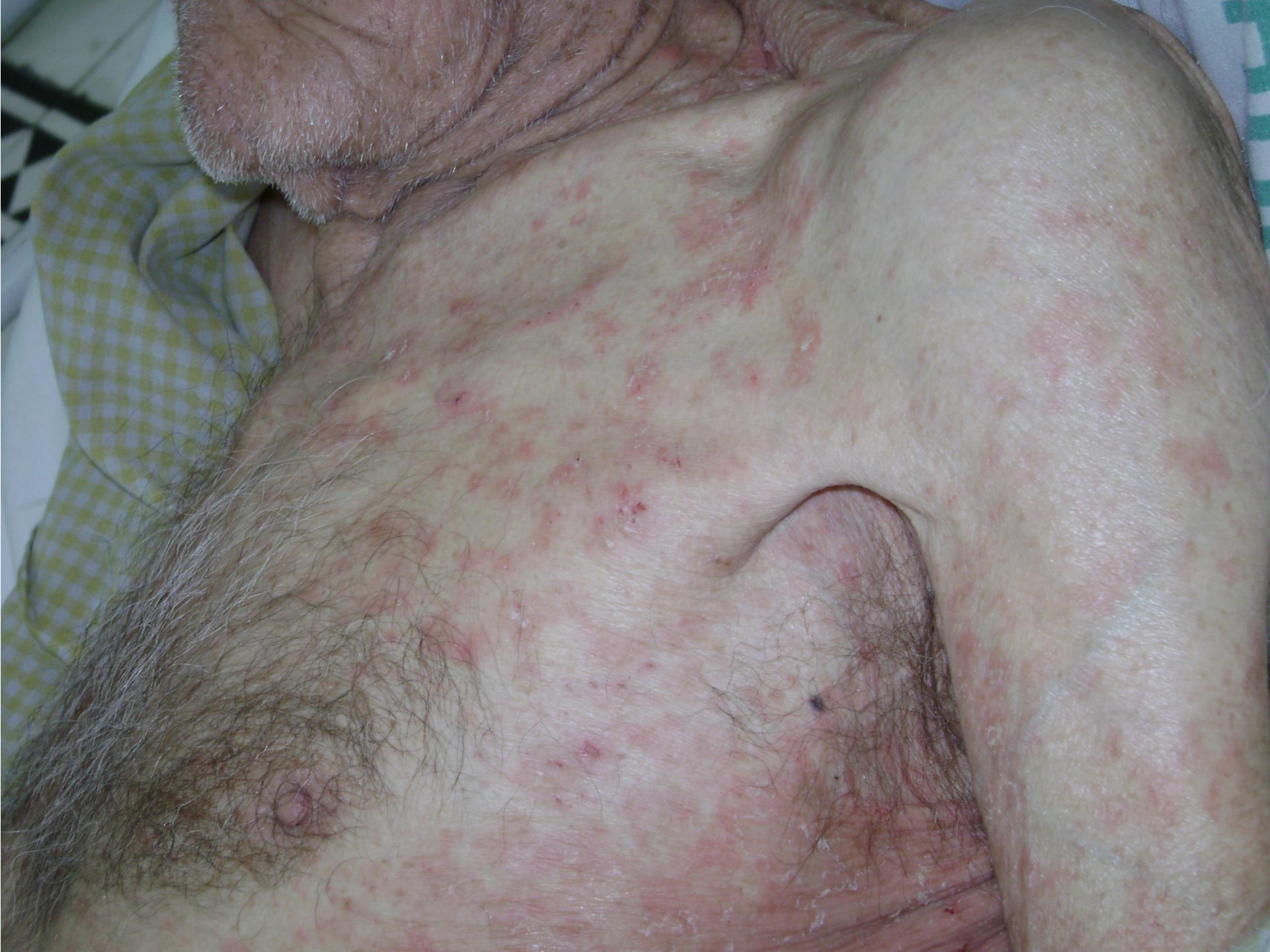Otras confluyendo y
siguiendo líneas de Blaschko

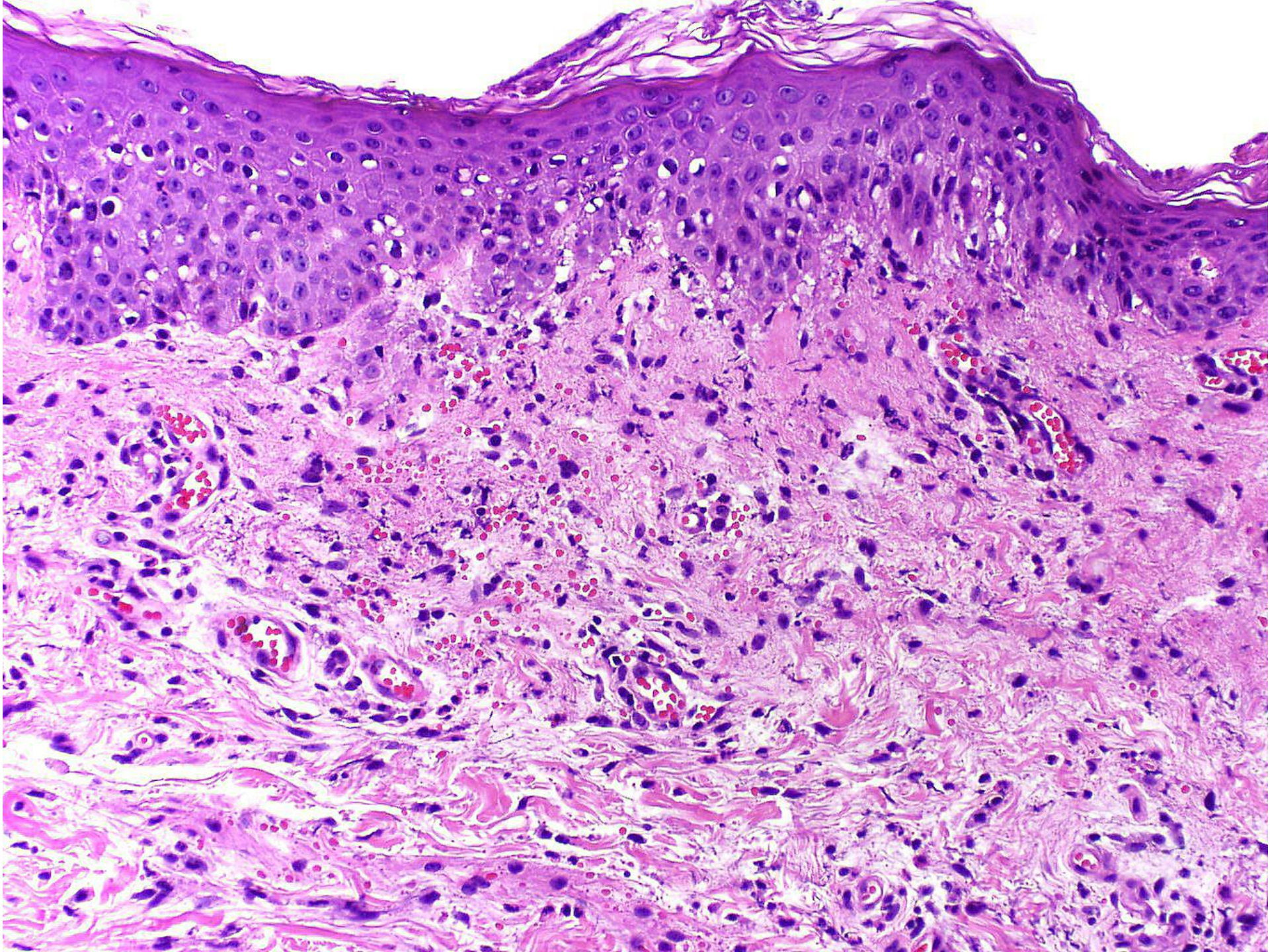


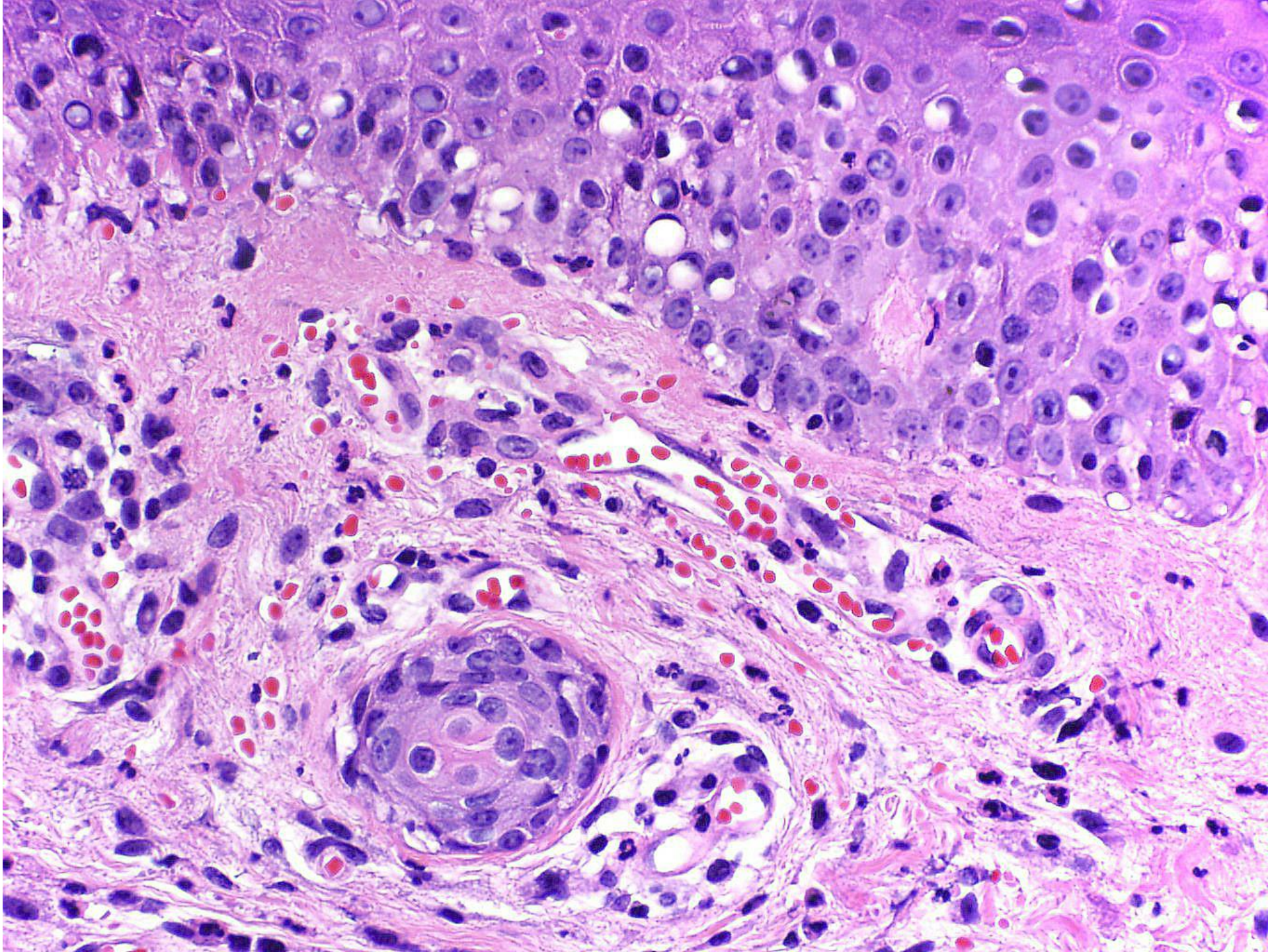


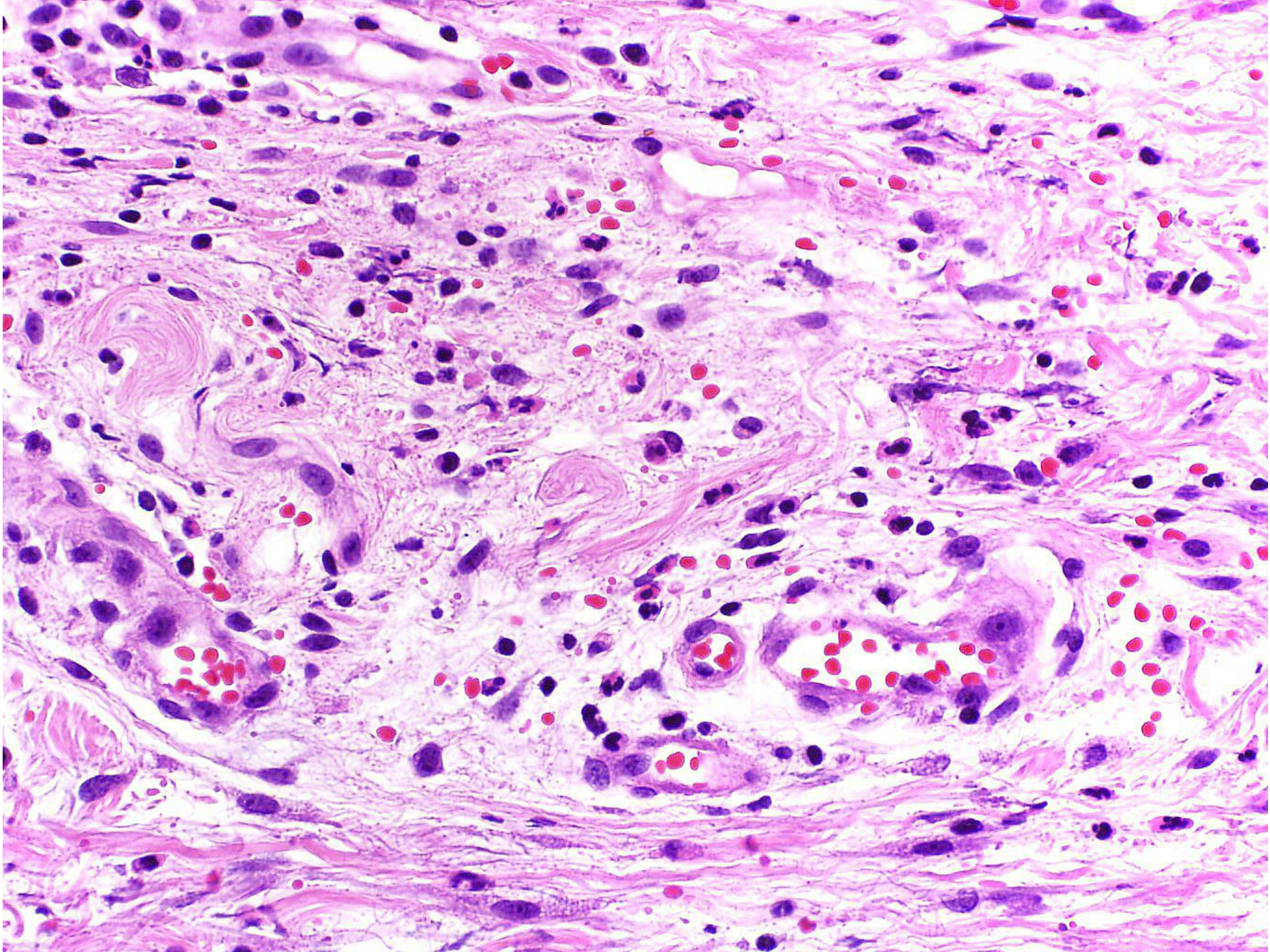


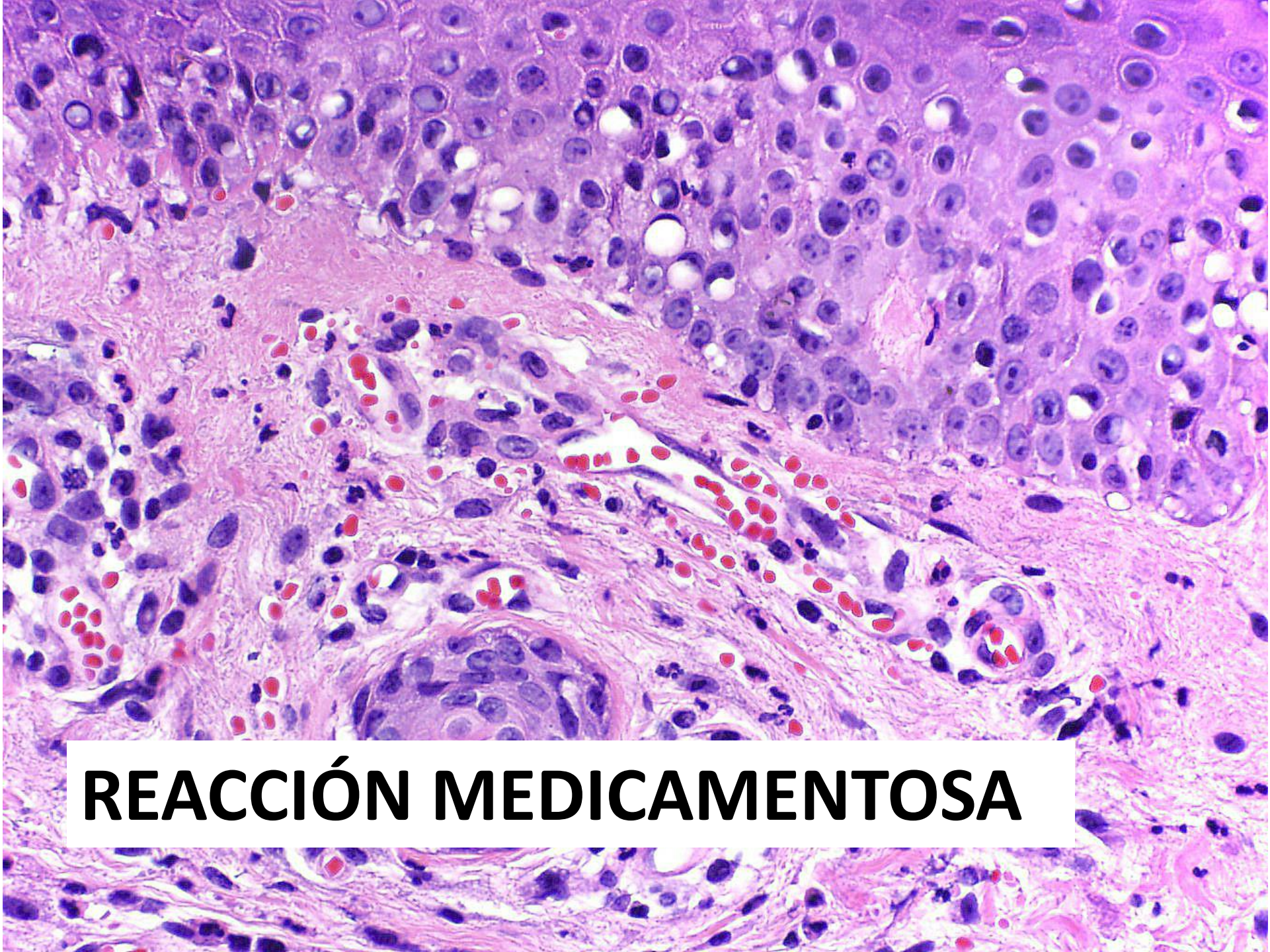
LIQUEN PLANO



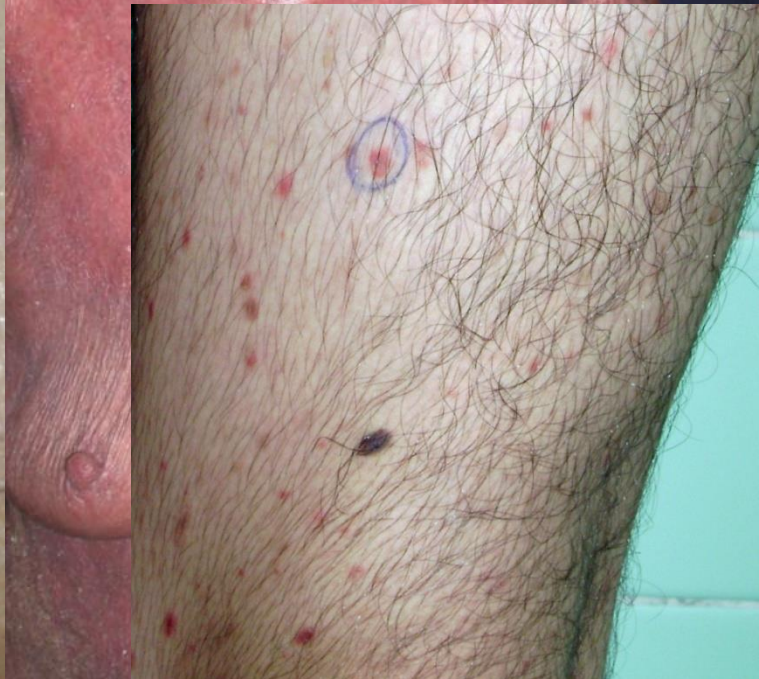
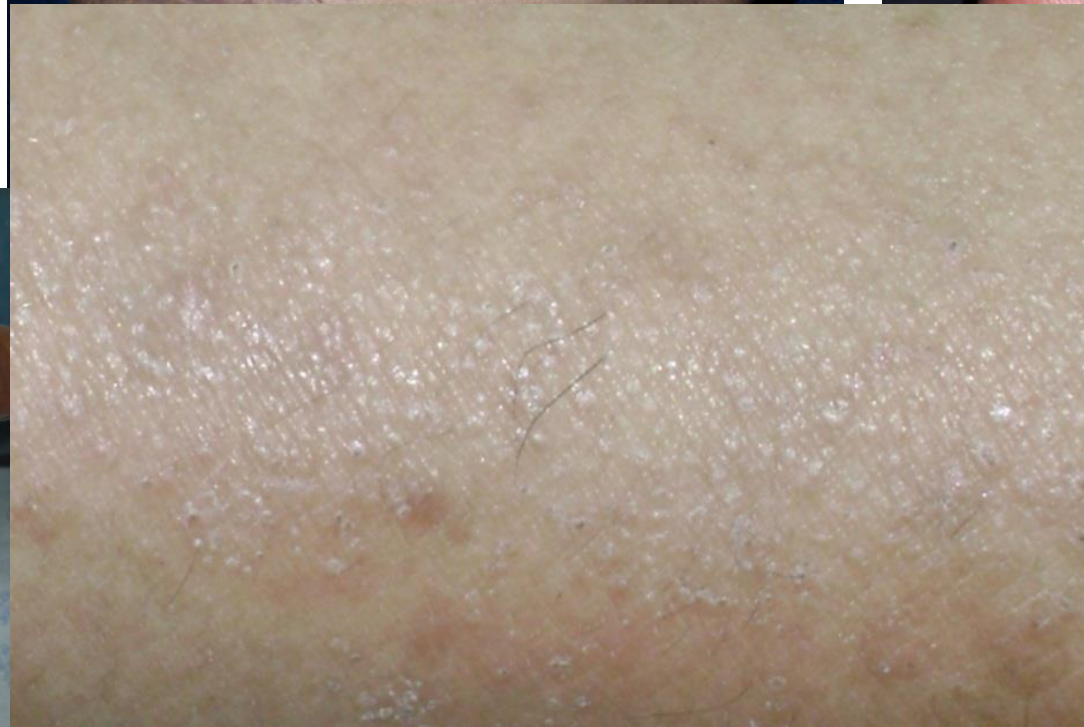
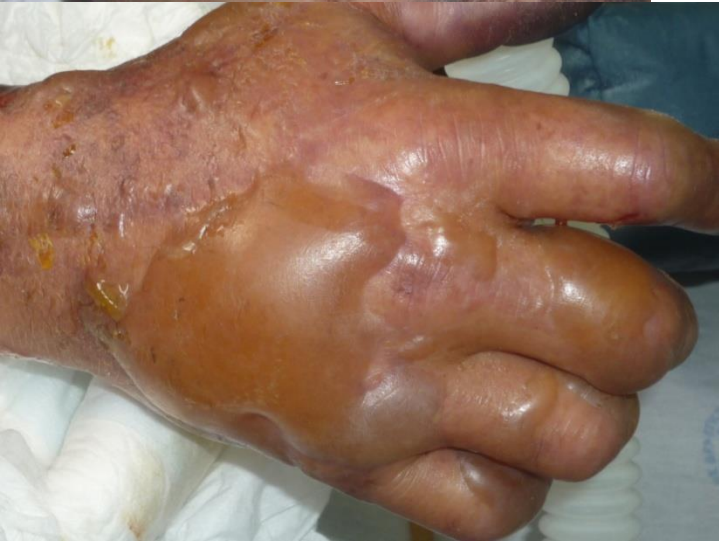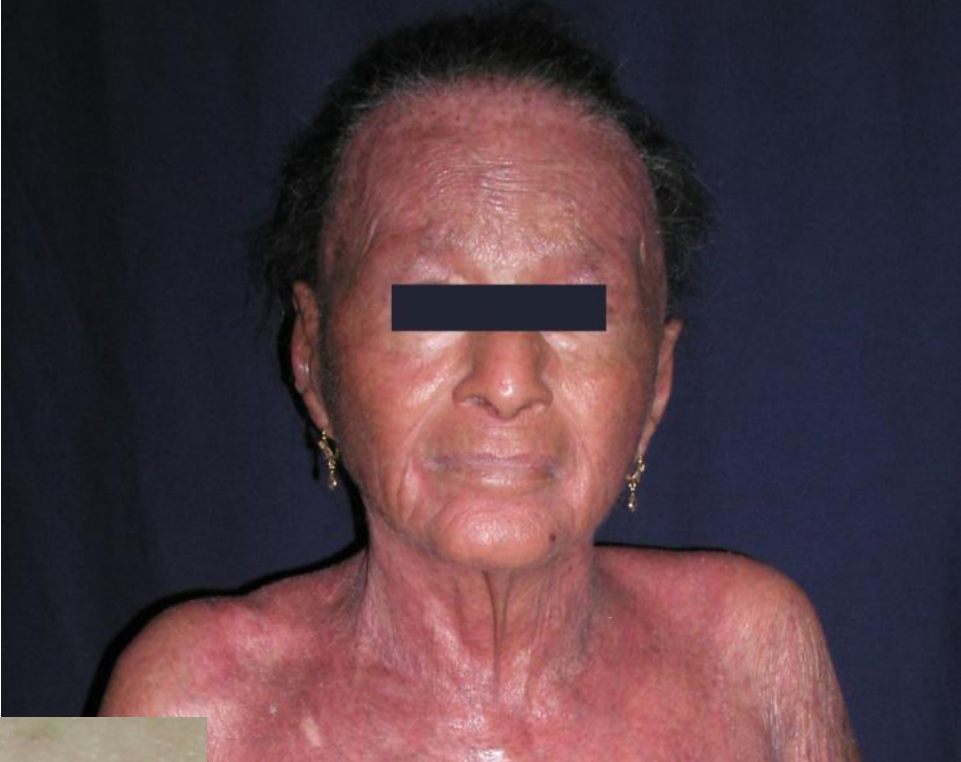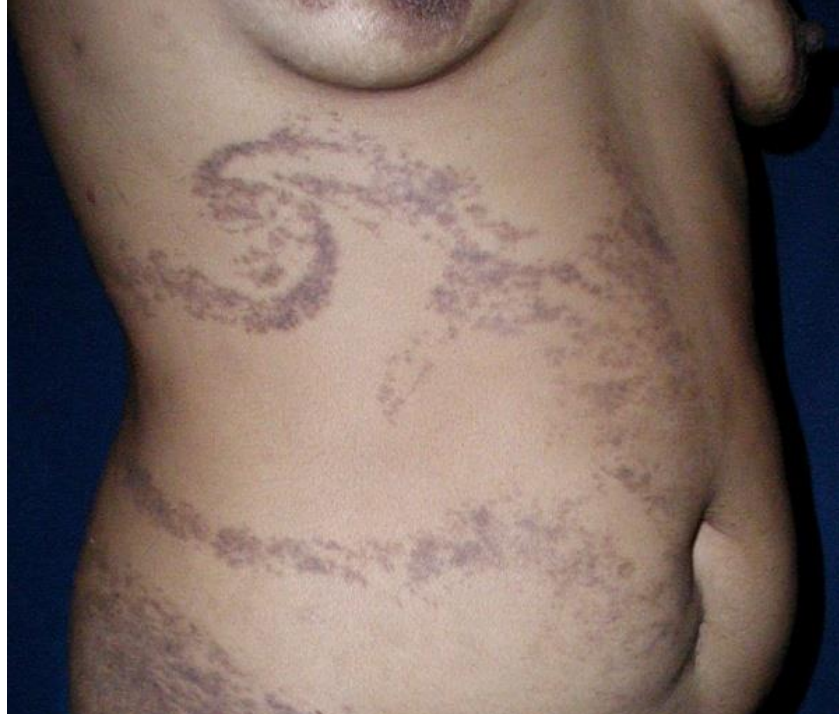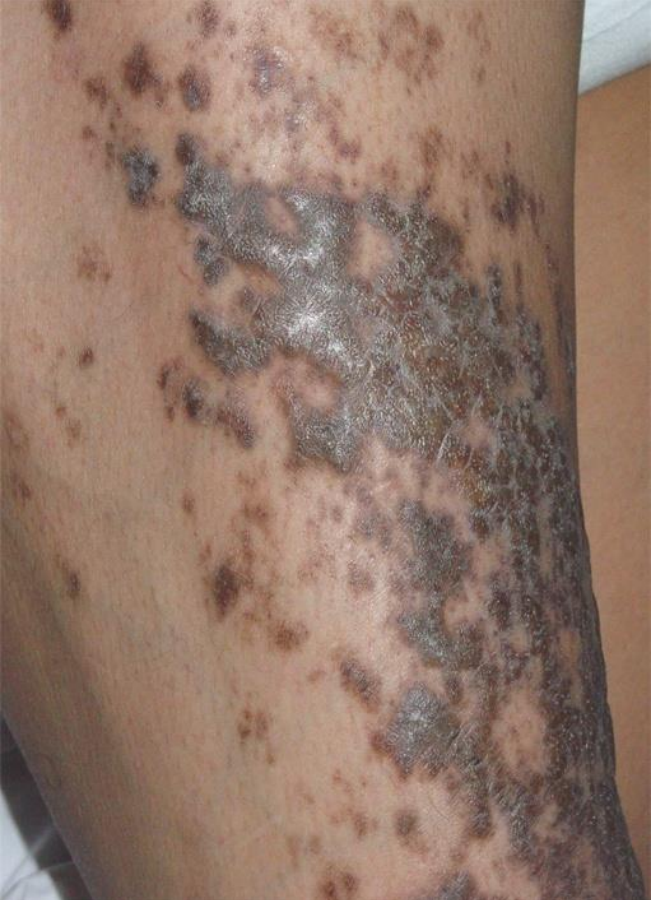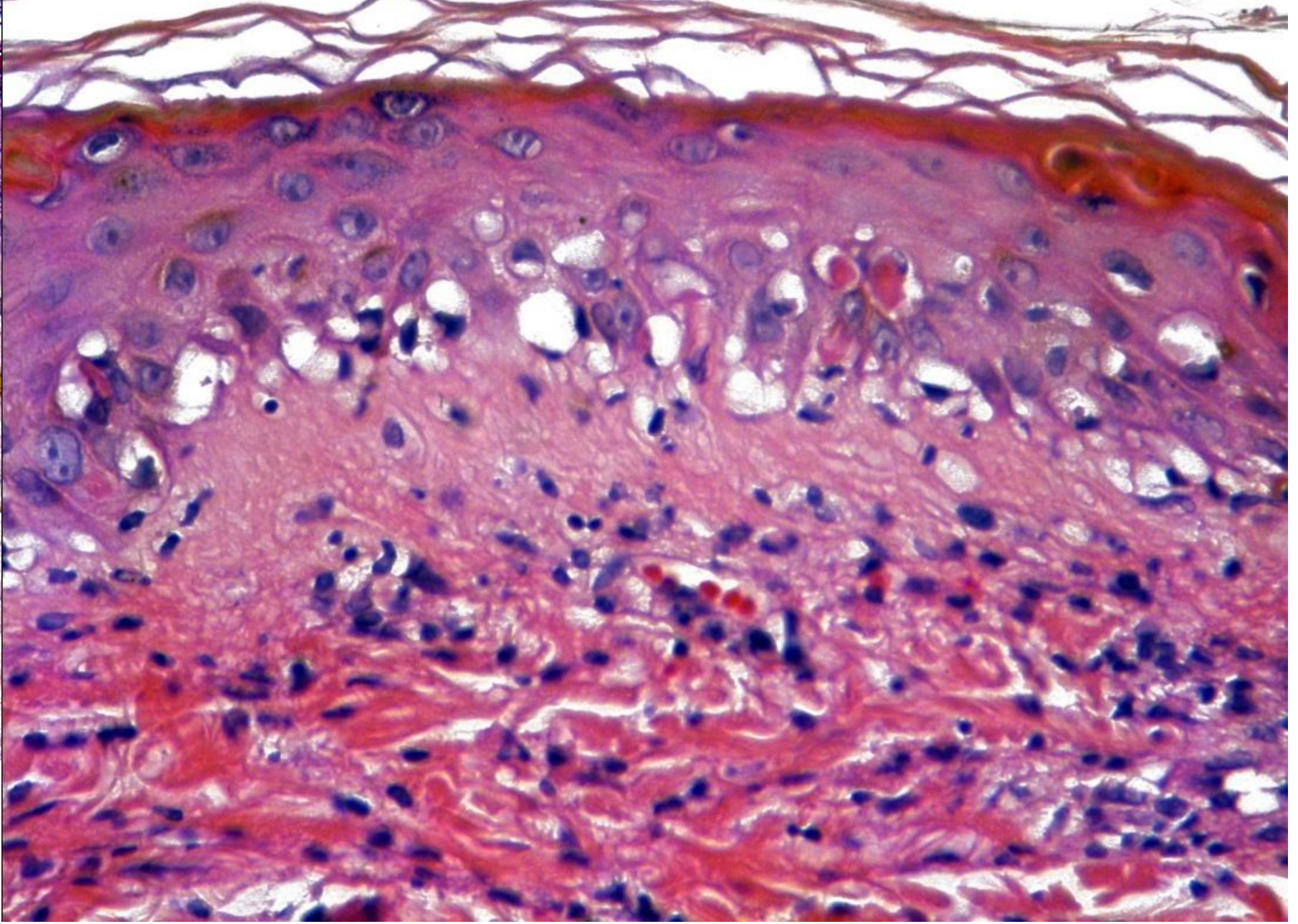
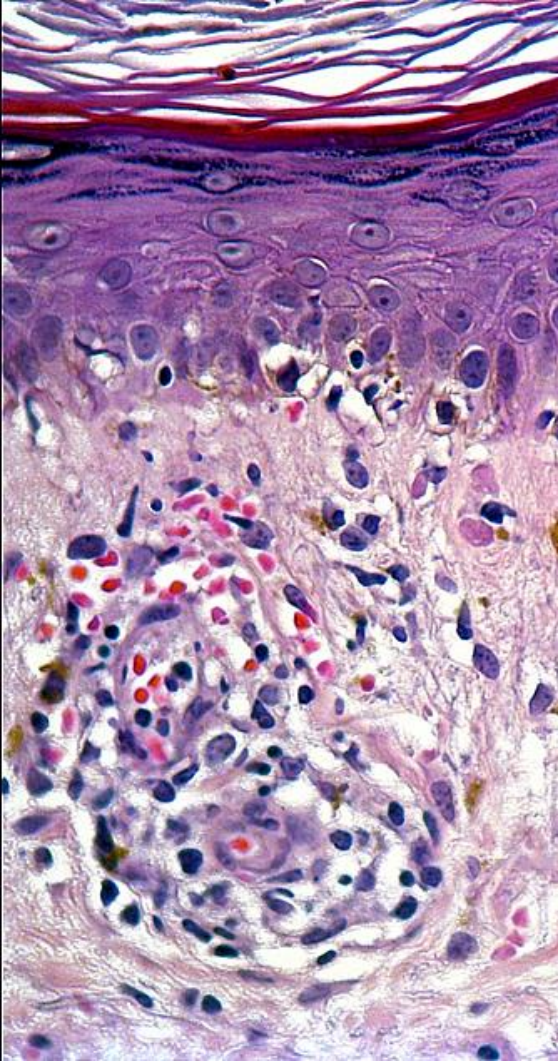


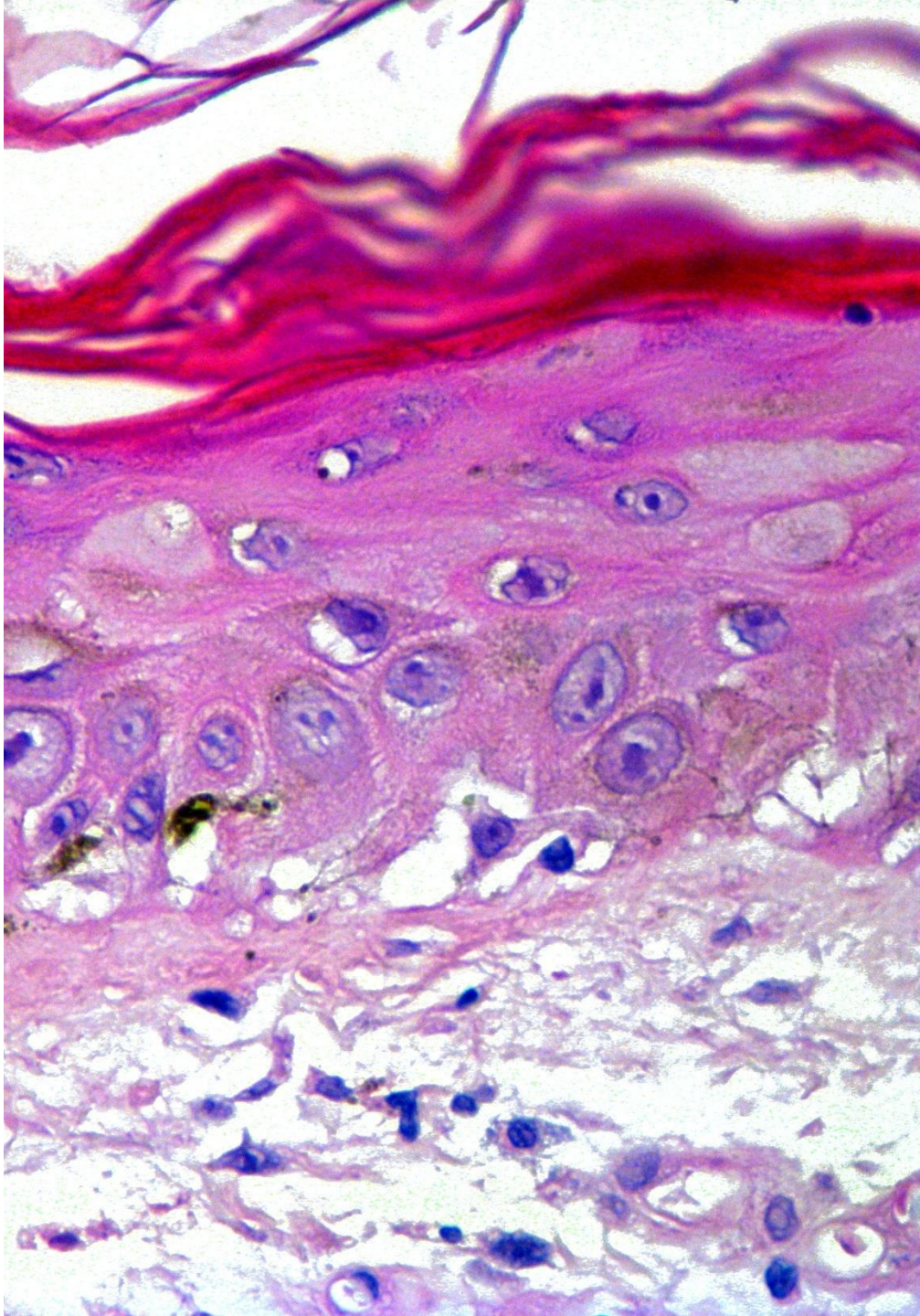




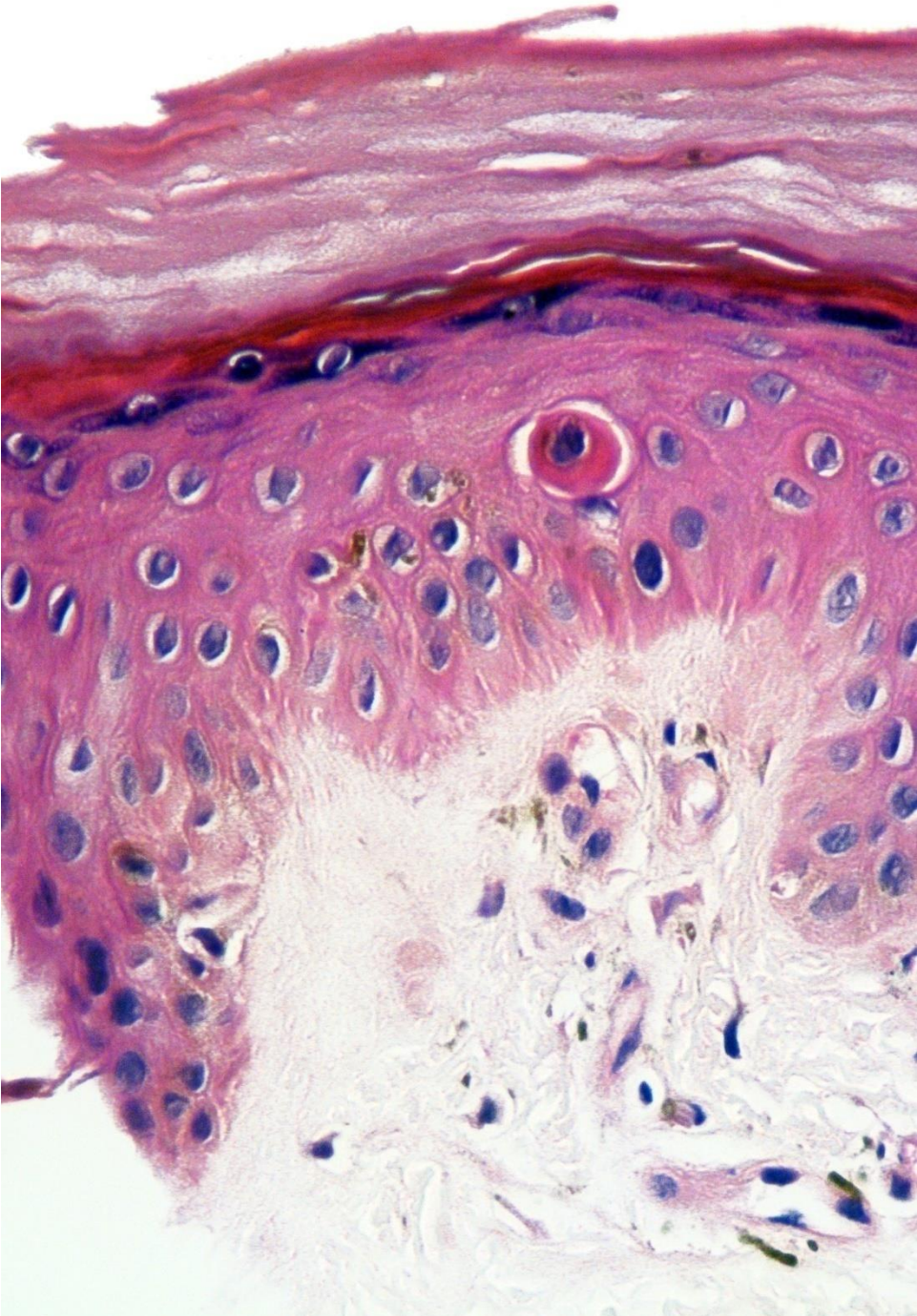
REACCIÓN MEDICAMENTOSA





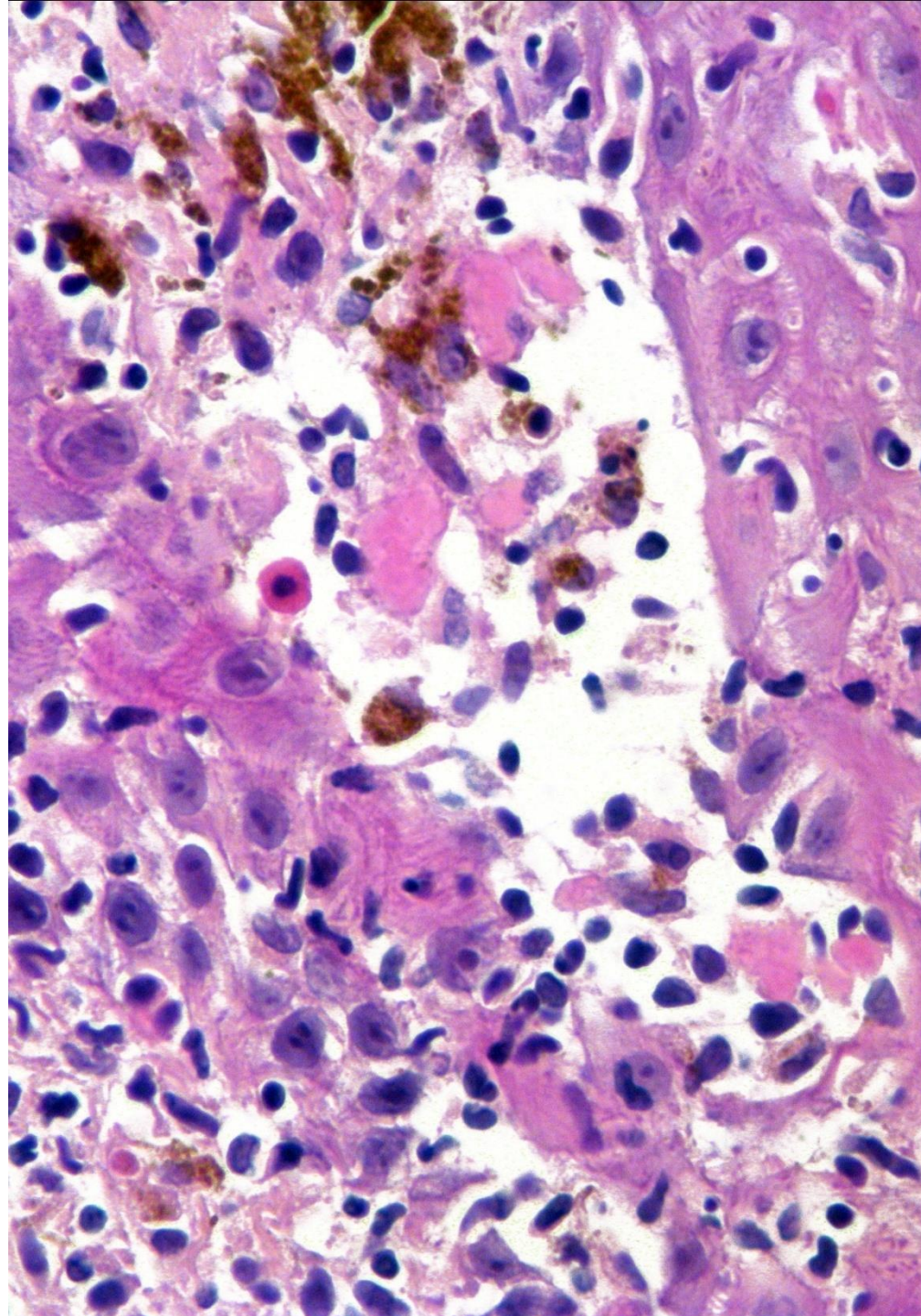


- Cambio vacuolar
- Degeneración vacuolar
- Degeneración liqüefactiva
- Degeneración hidrópica



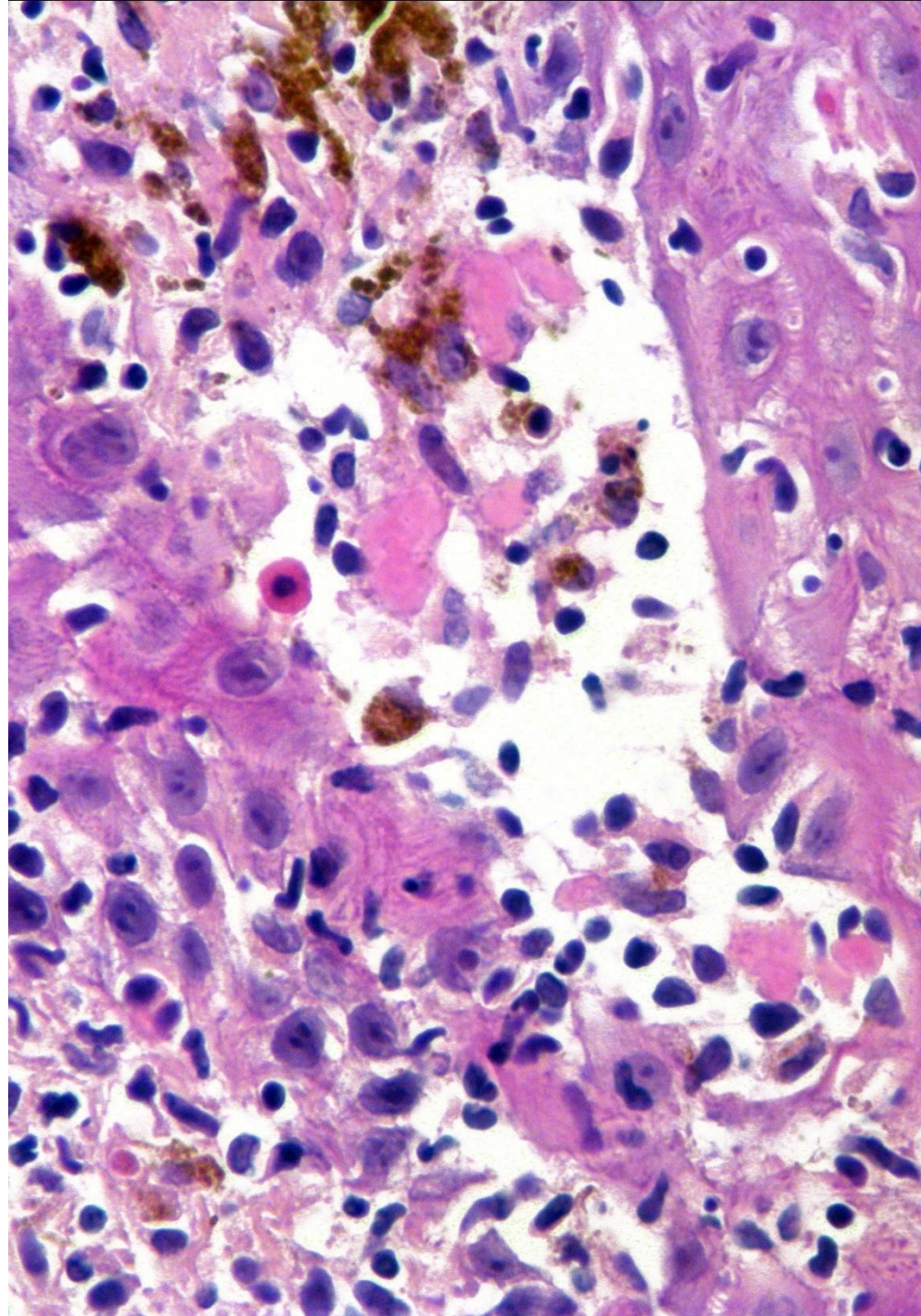
APOPTOSIS

- Constricción celular
- Condensación de la cromatina
- Fragmentación
- Fagocitosis



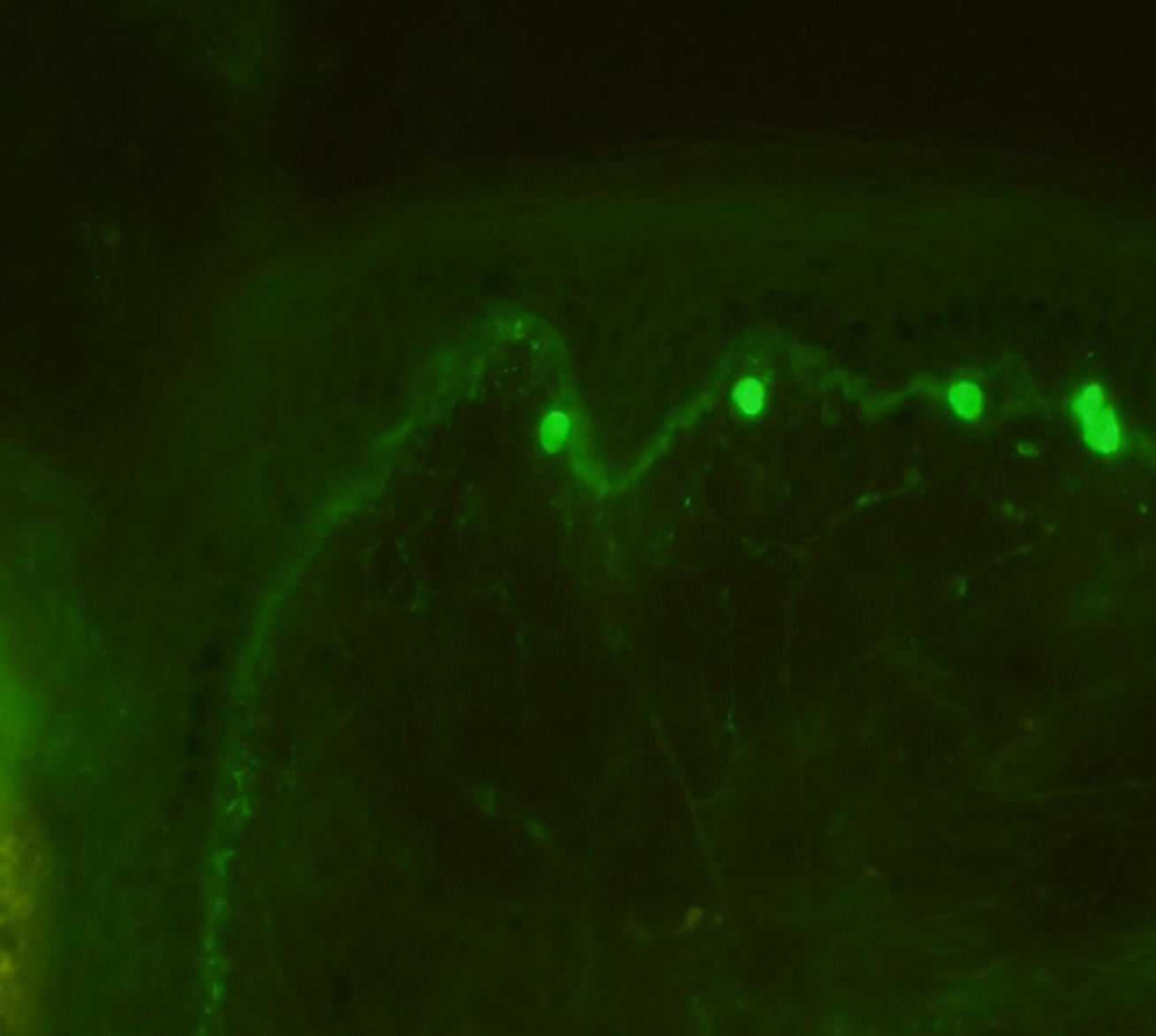
APOPTOSIS

- Constricción celular
- Condensación de la cromatina
- Fragmentación
- Fagocitosis

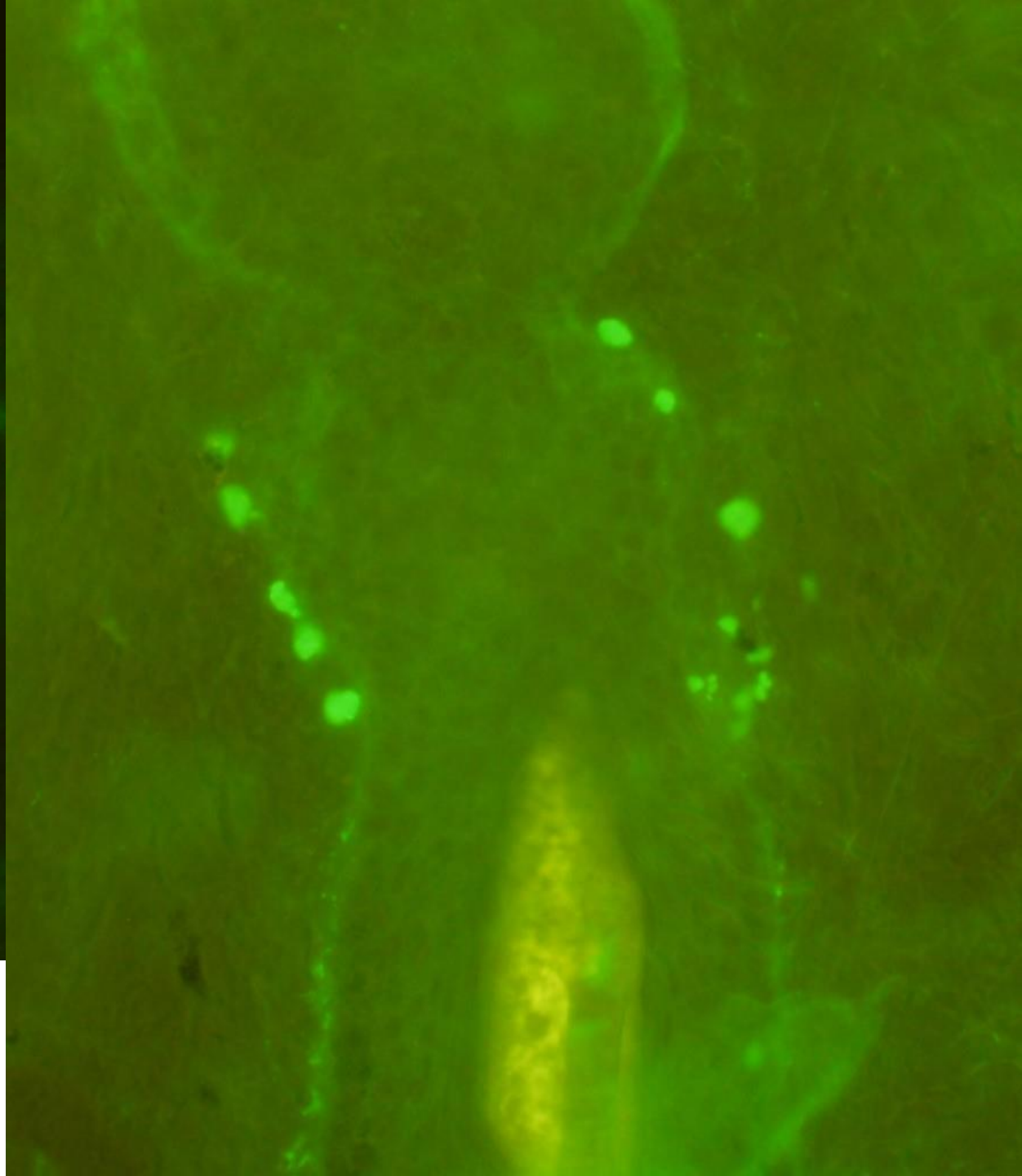


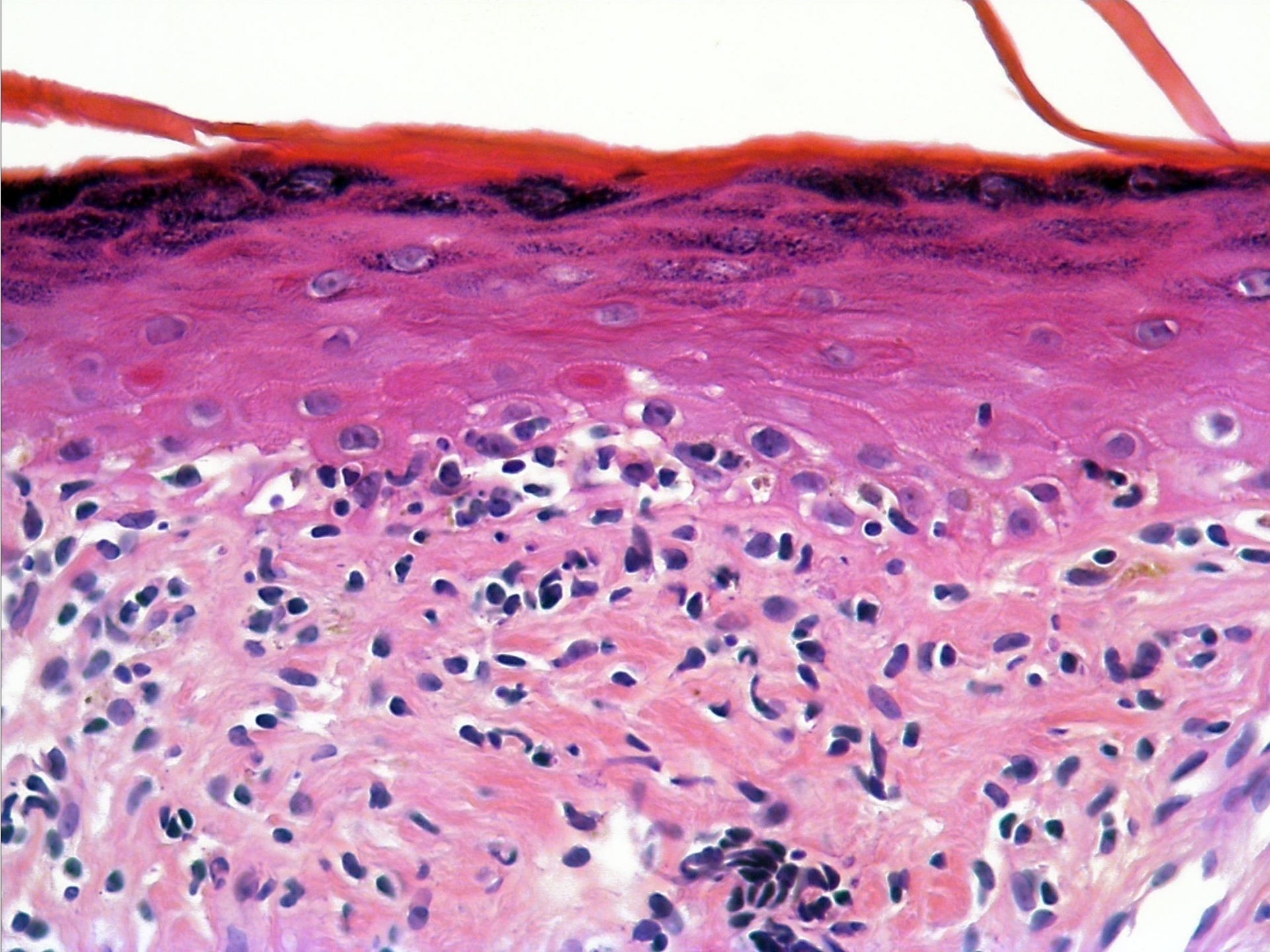
APOPTOSIS

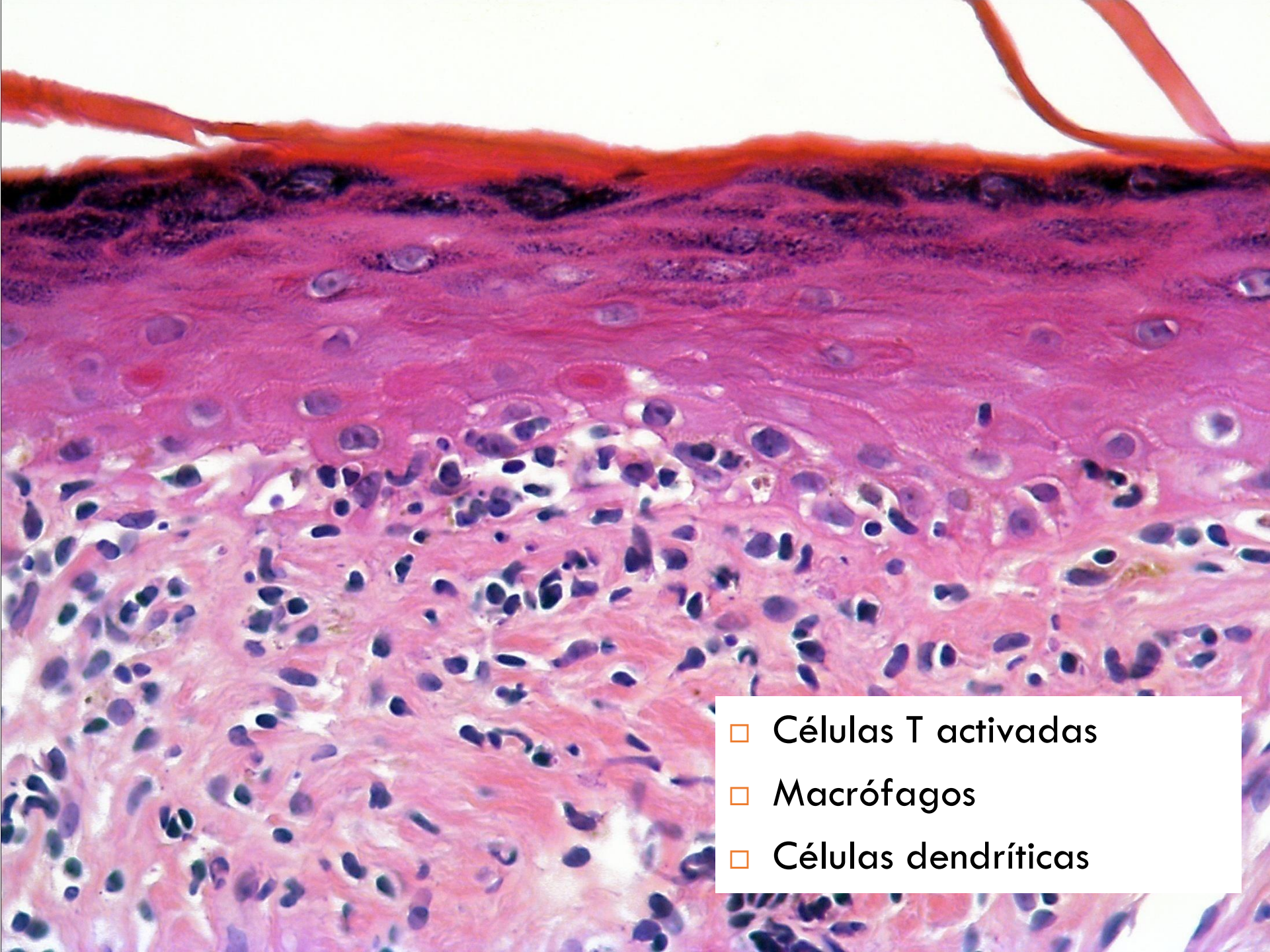
- Queratinocitos apoptoicos.
- Cuerpos de Civatte.
- Cuerpos citoides.
- Cuerpos coloides.
- Disqueratocitos



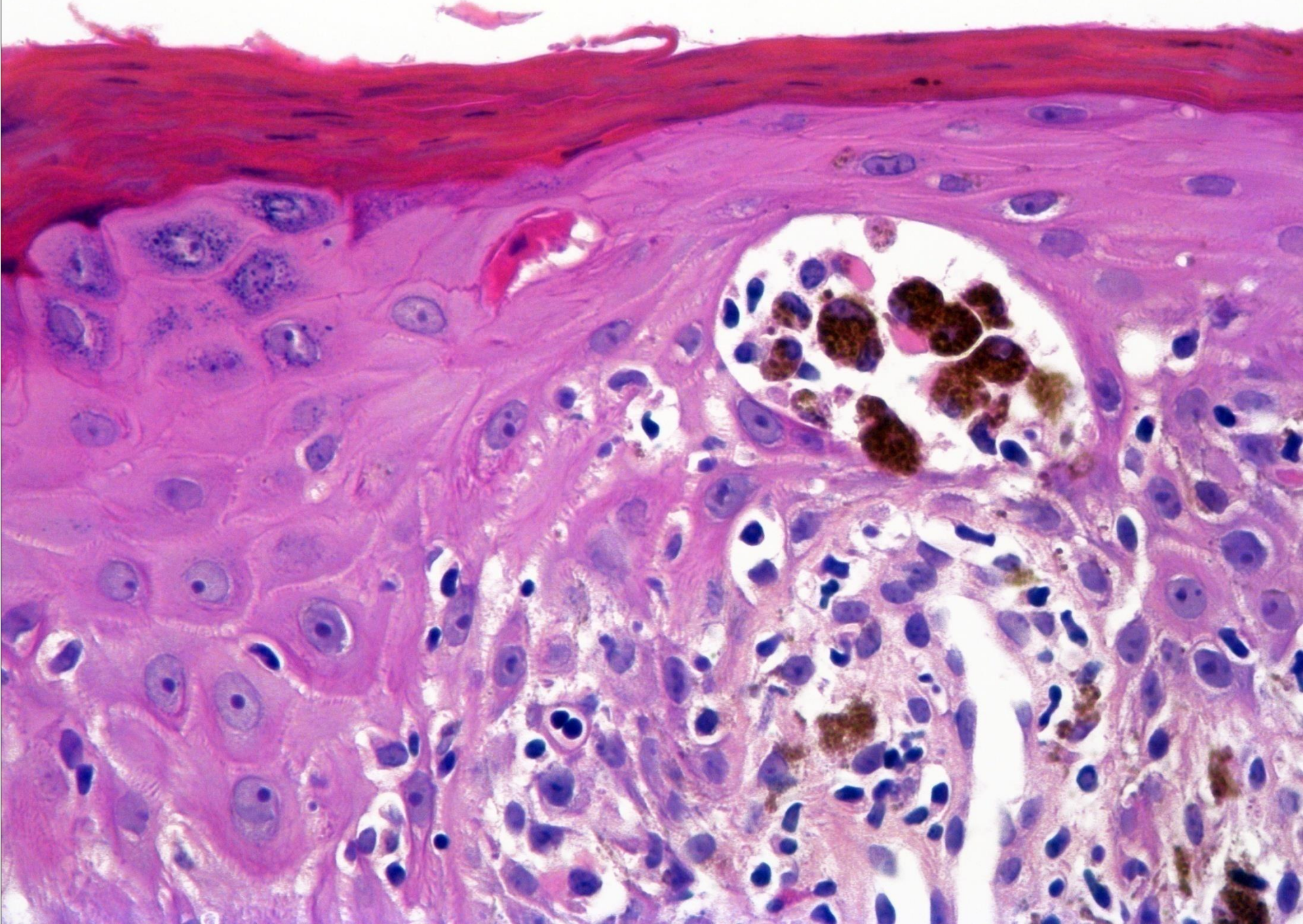
IgM

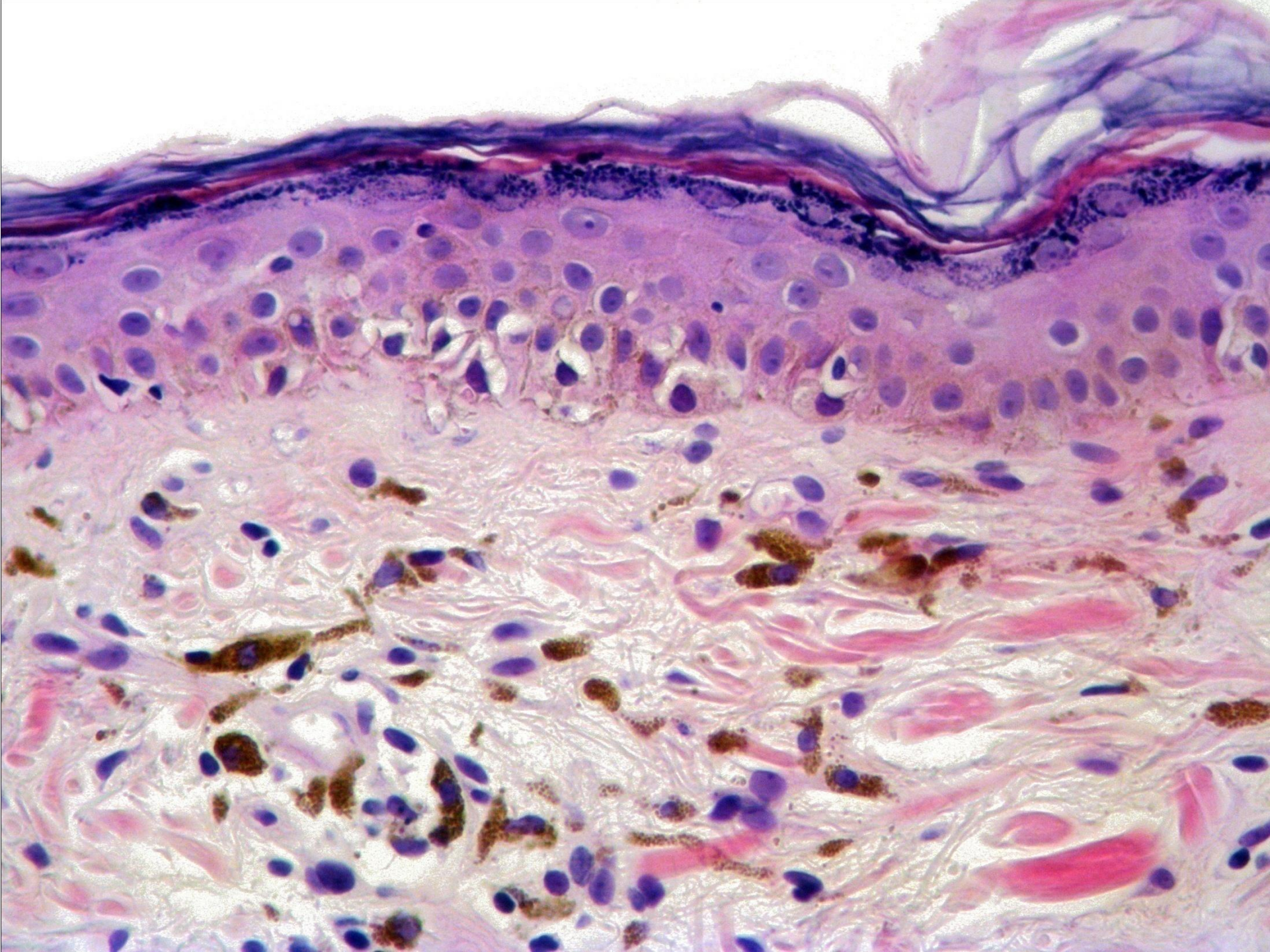


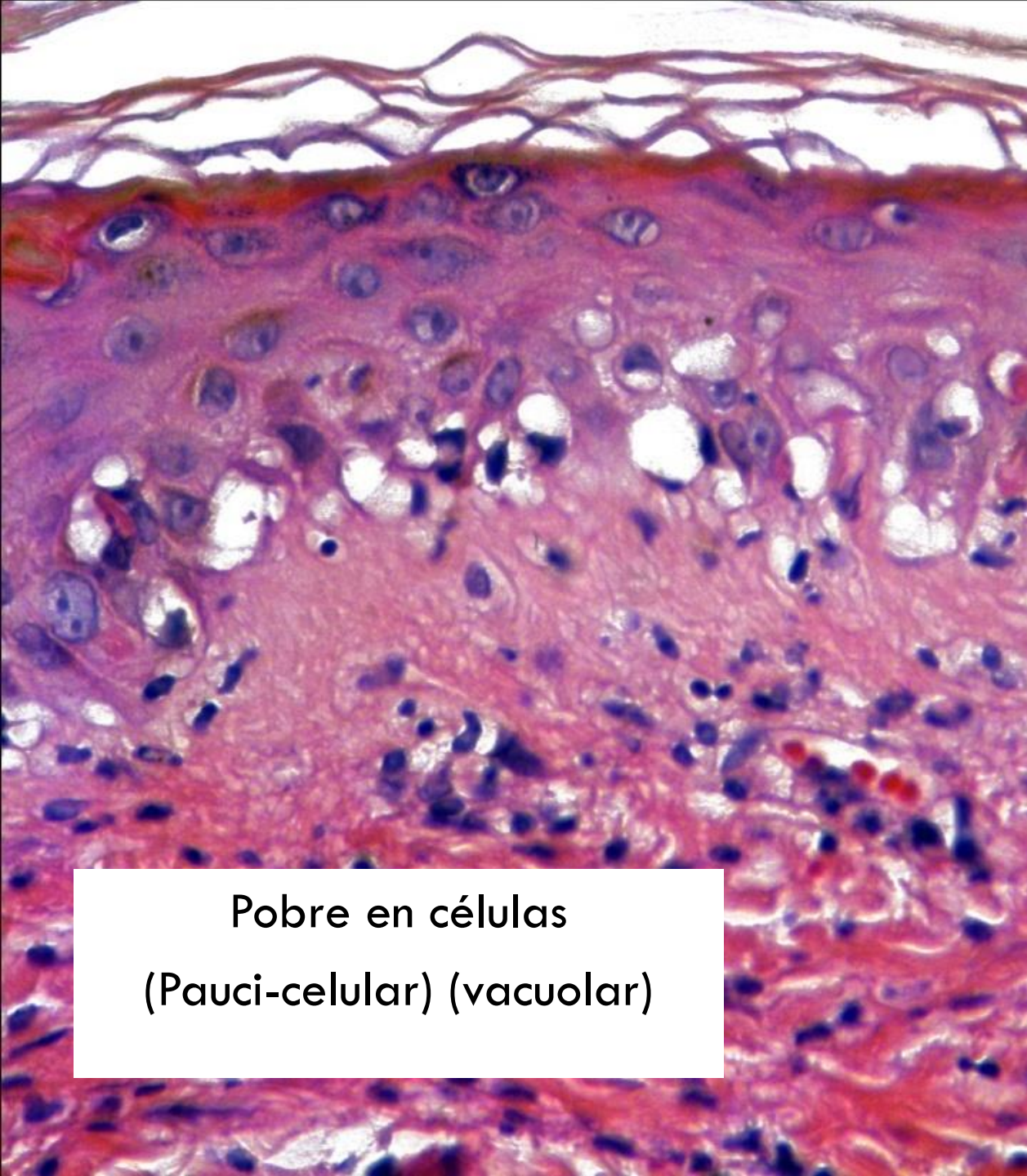




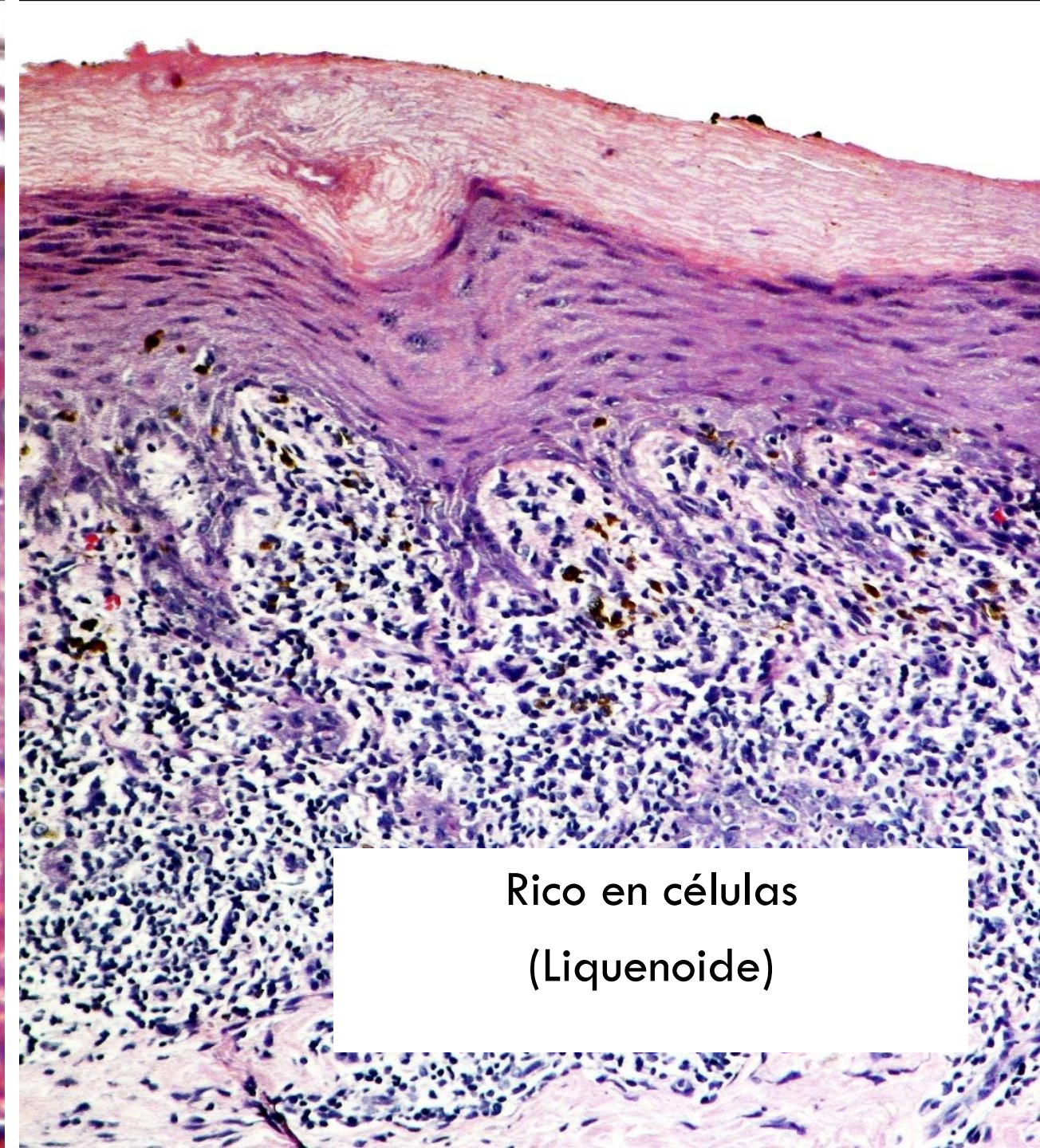
- Células T activadas
- Macrófagos
- Células dendríticas







Pobre en células
(Pauci-celular) (vacuolar)



Rico en células
(Liquenoide)

Interface Dermatitis

A. Neil Crowson, MD; Cynthia M. Magro, MD; Martin C. Mihm, Jr, MD

(*Arch Pathol Lab Med.* 2008;132:652–666)

Prototipos

Pobre en células

Eritema multiforme
Enfermedad de tejido conectivo
LES
Dermatomiositis
EMTC
Enfermedad de injerto contra huésped
Exantema viral morbiliforme
Reacción medicamentosa morbiliforme

Rico en células

Desórdenes liquenoides
idiopáticos
Liquen plano
Liquen estriado
Liquen Nítido
Enfermedad de tejido
conectivo
Lupus Discoide
LES anti RO
EMTC
Púrpura liquenoide
Reacción liquenoide a drogas
y Eritema pigmentado fijo

Interface Dermatitis

A. Neil Crowson, MD; Cynthia M. Magro, MD; Martin C. Mihm, Jr, MD

(*Arch Pathol Lab Med.* 2008;132:652–666)

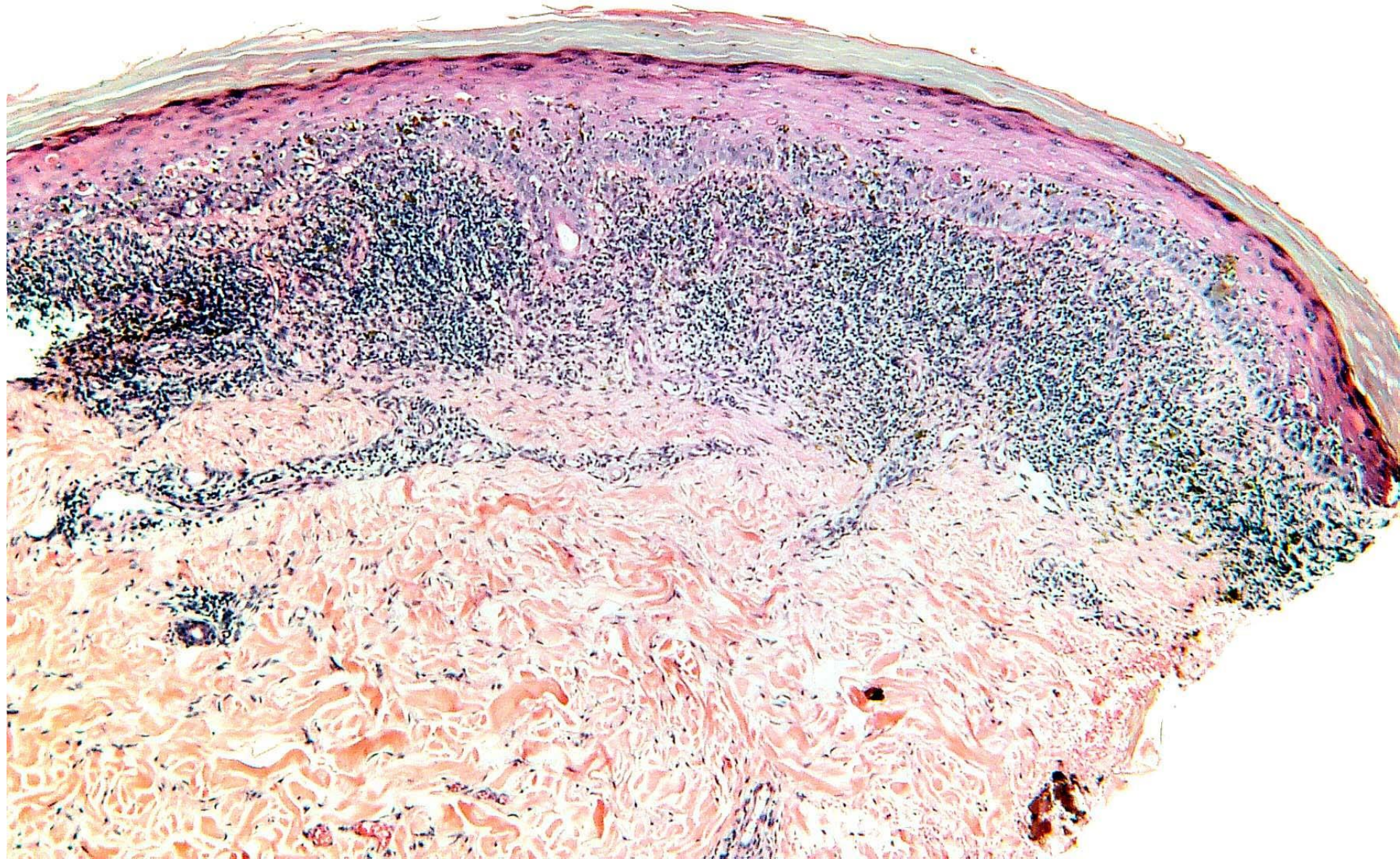
Prototipos

Pobre en células

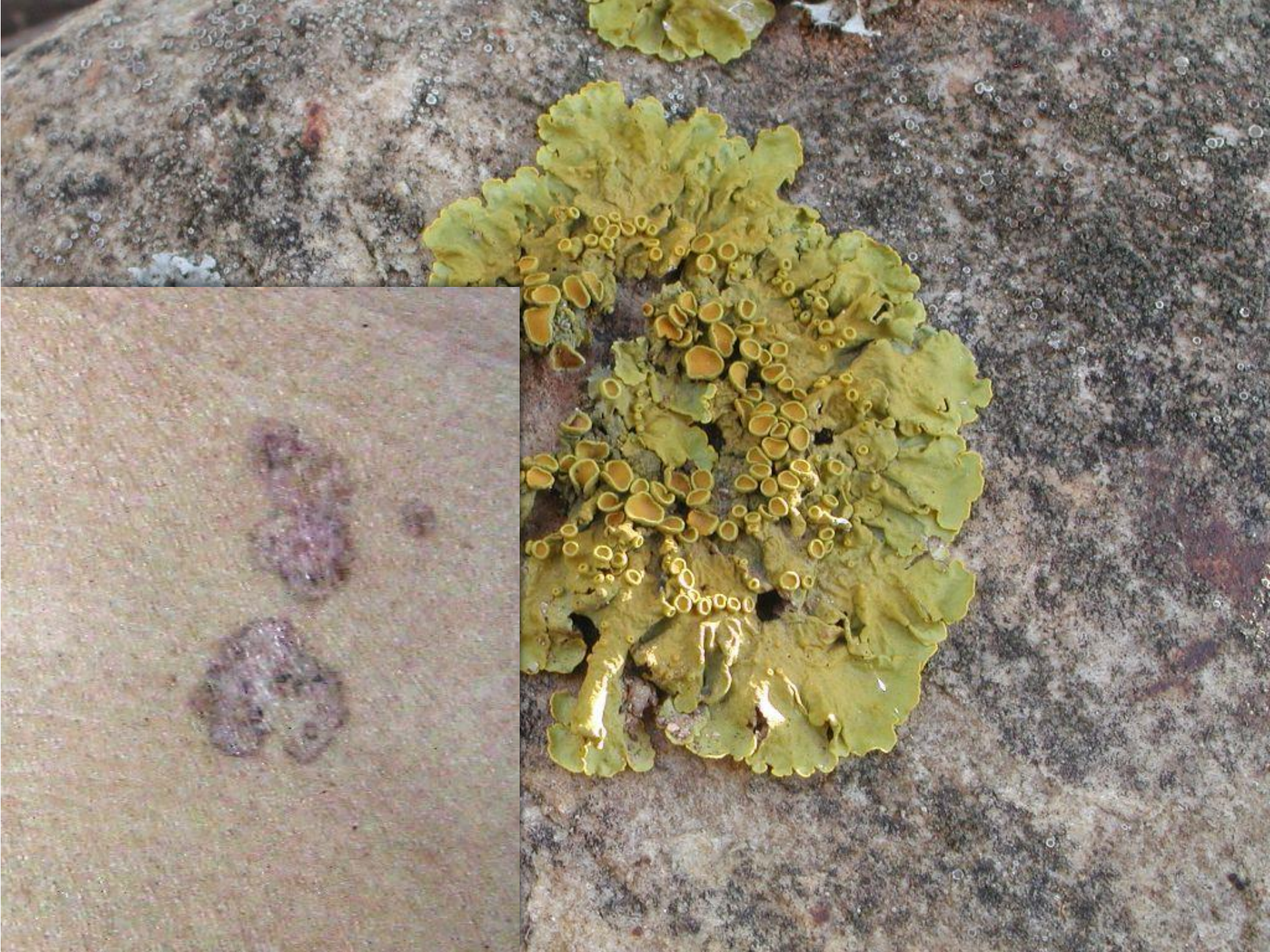Eritema multiforme
Enfermedad de tejido conectivo
LES
Dermatomiositis
EMTC
Enfermedad de injerto contra huésped
Exantema viral morbiliforme
Reacción medicamentosa morbiliforme

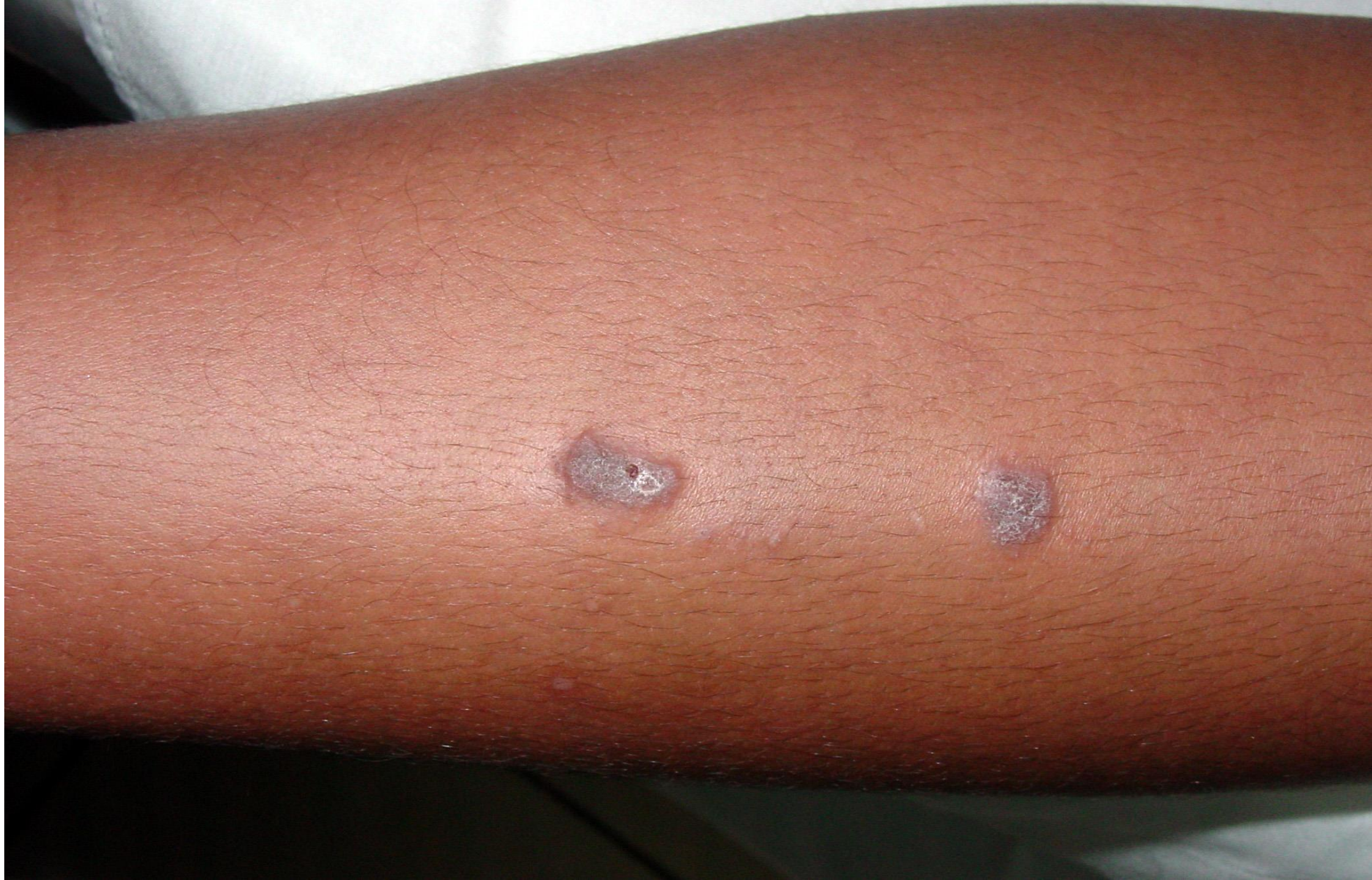Rico en células

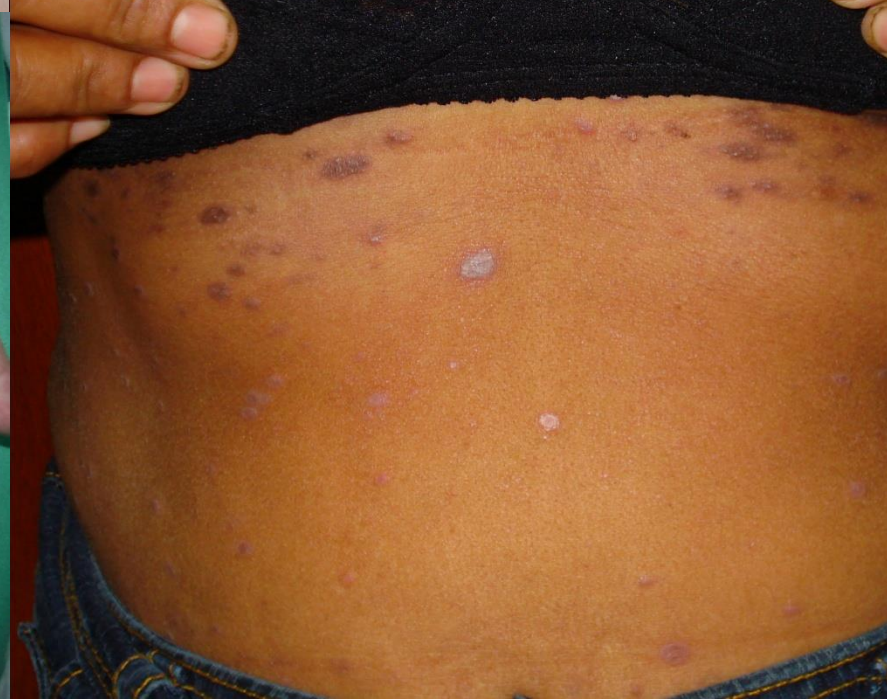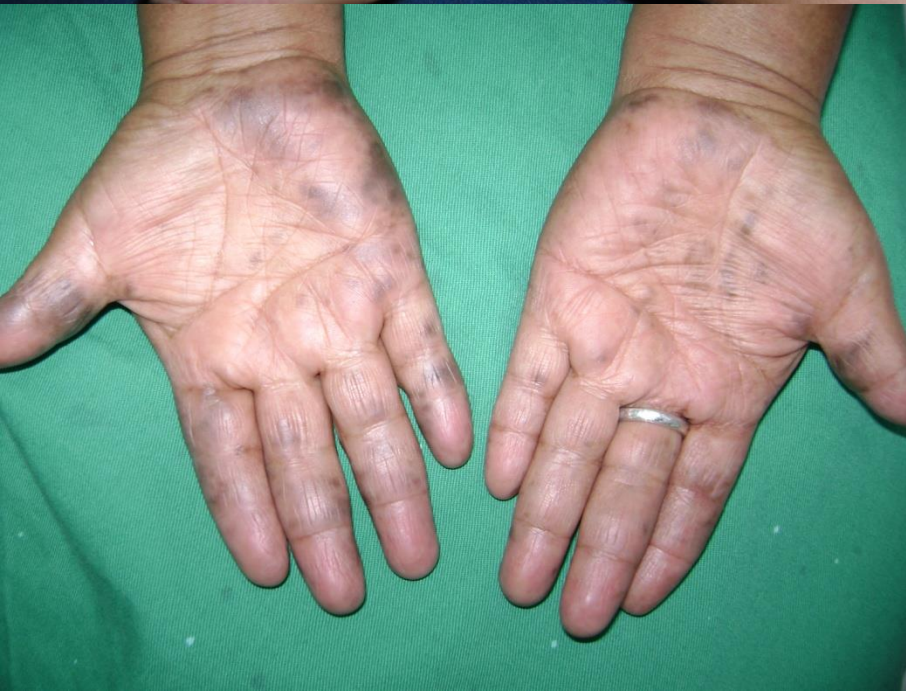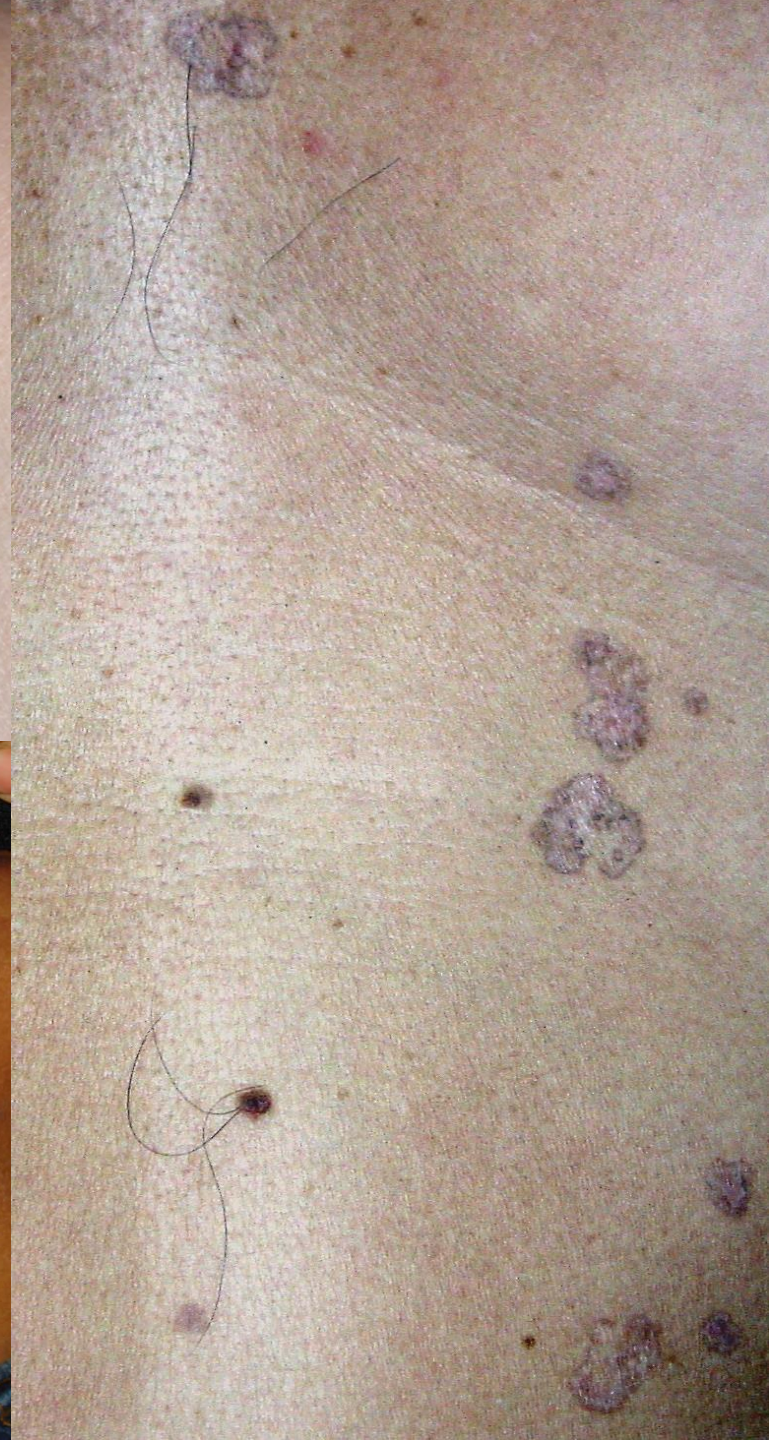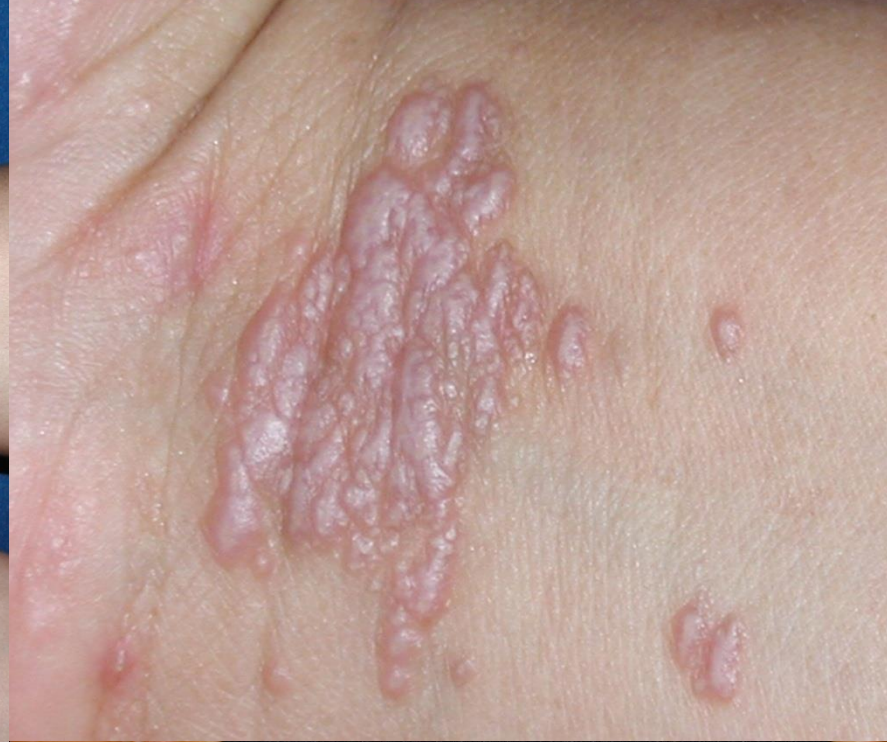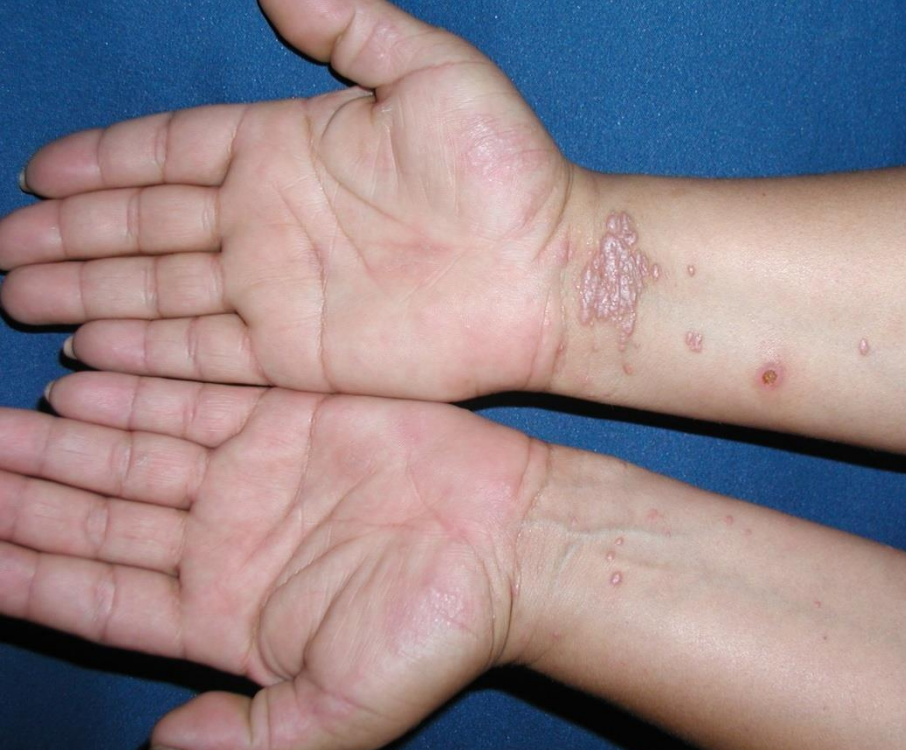Desórdenes liquenoides
idiopáticos
Liquen plano
Liquen estriado
Liquen Nítido
Enfermedad de tejido
conectivo
Lupus Discoide
LES anti RO
EMTC
Púrpura liquenoide
Reacción liquenoide a drogas
y Eritema pigmentado fijo



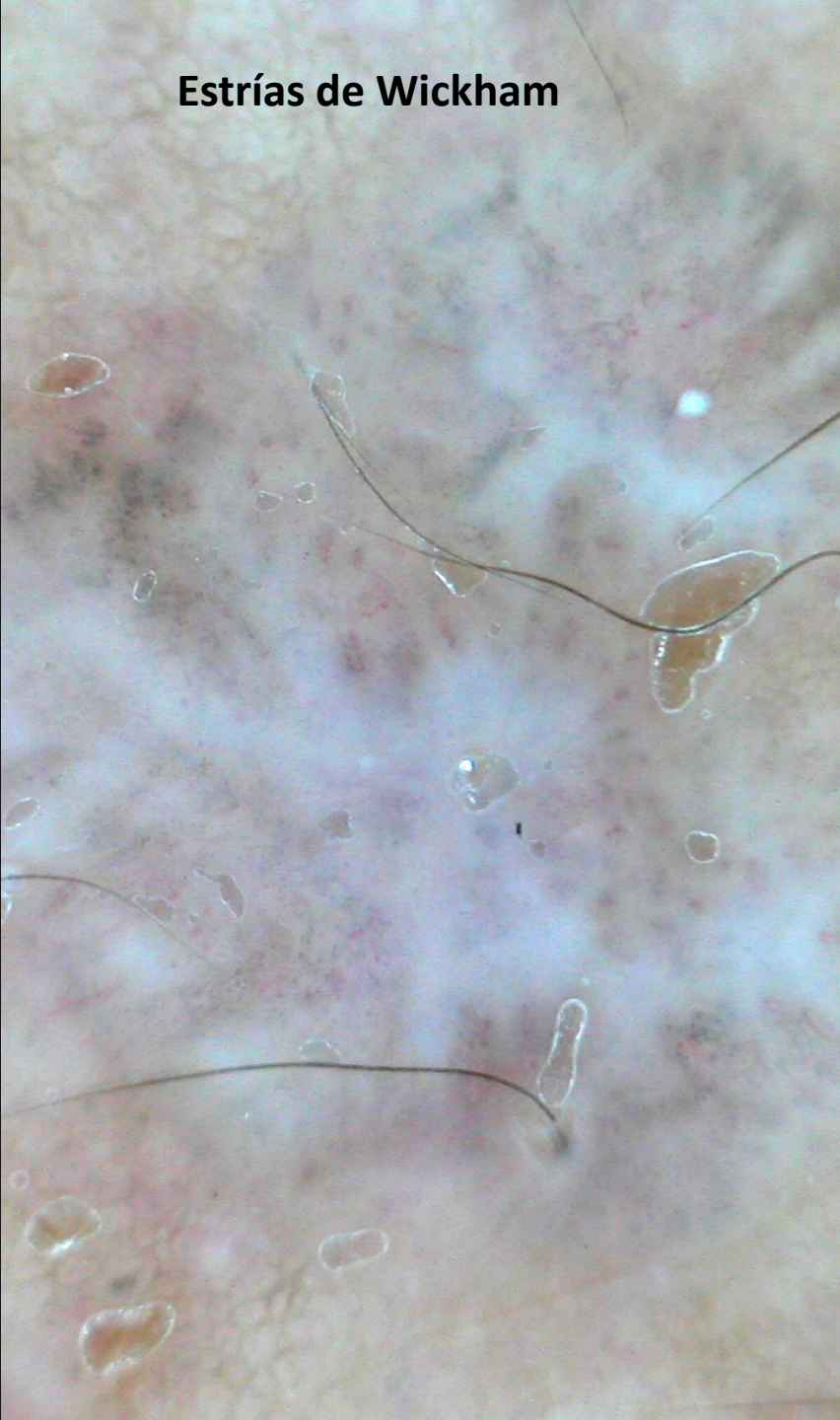




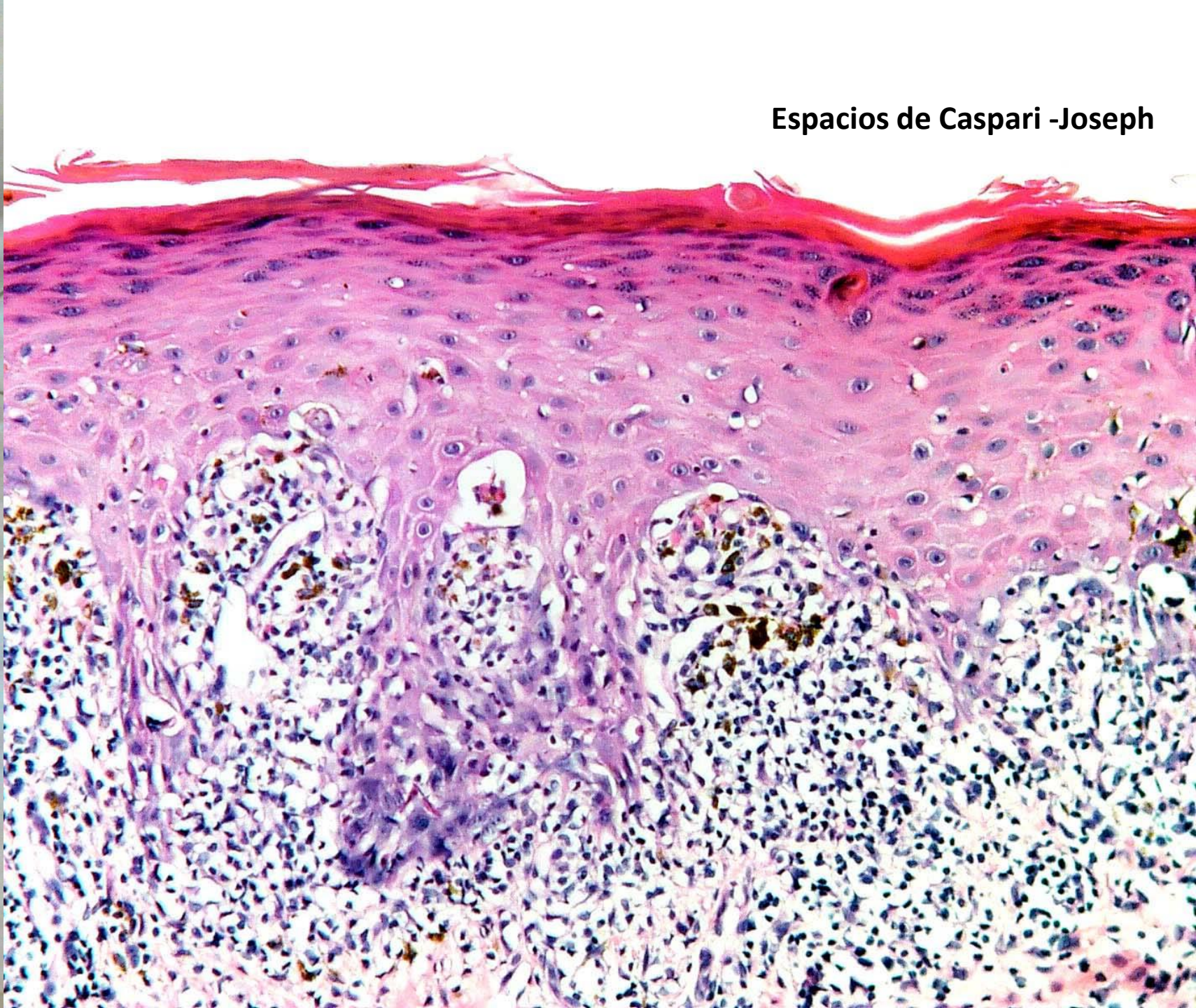


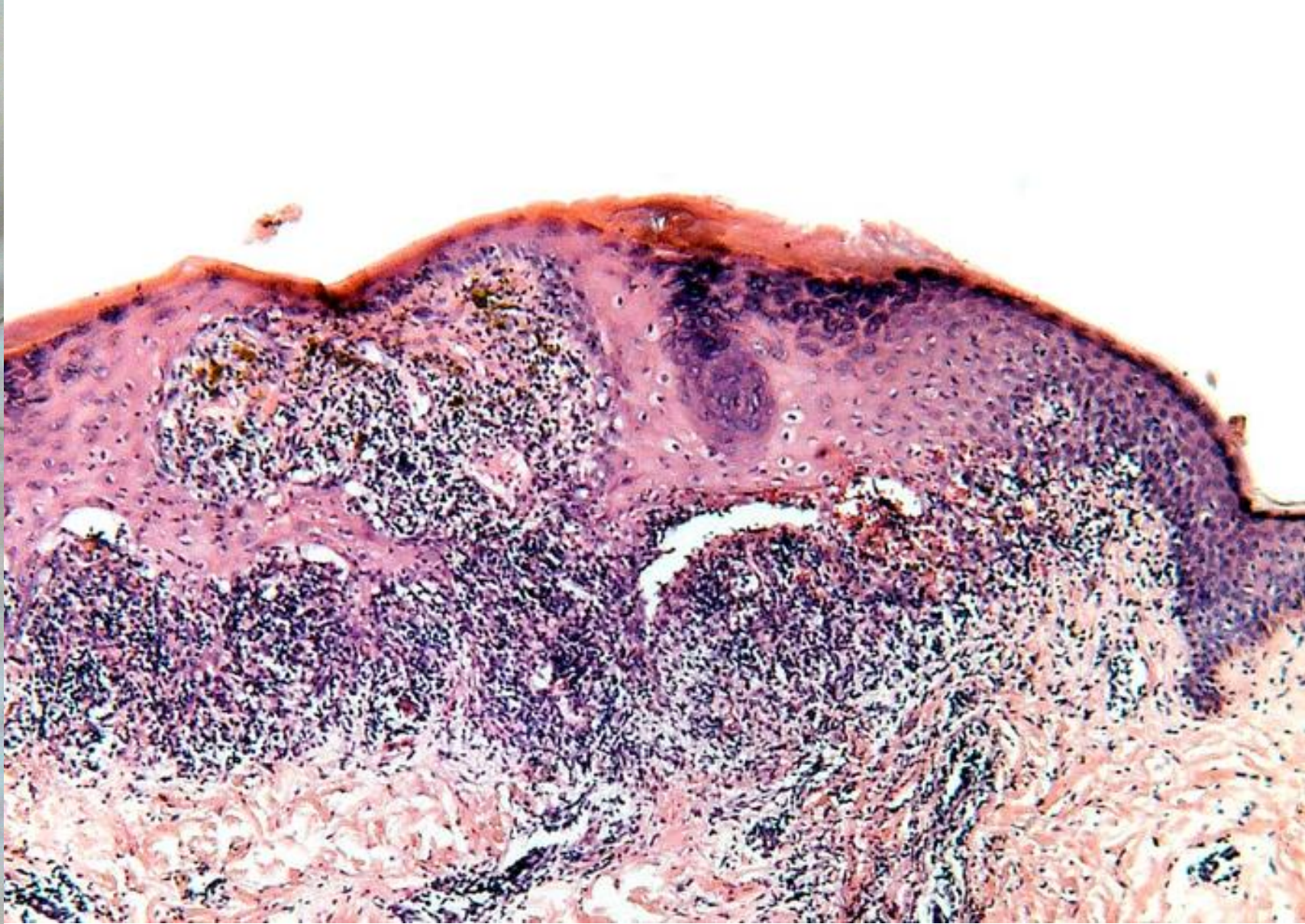
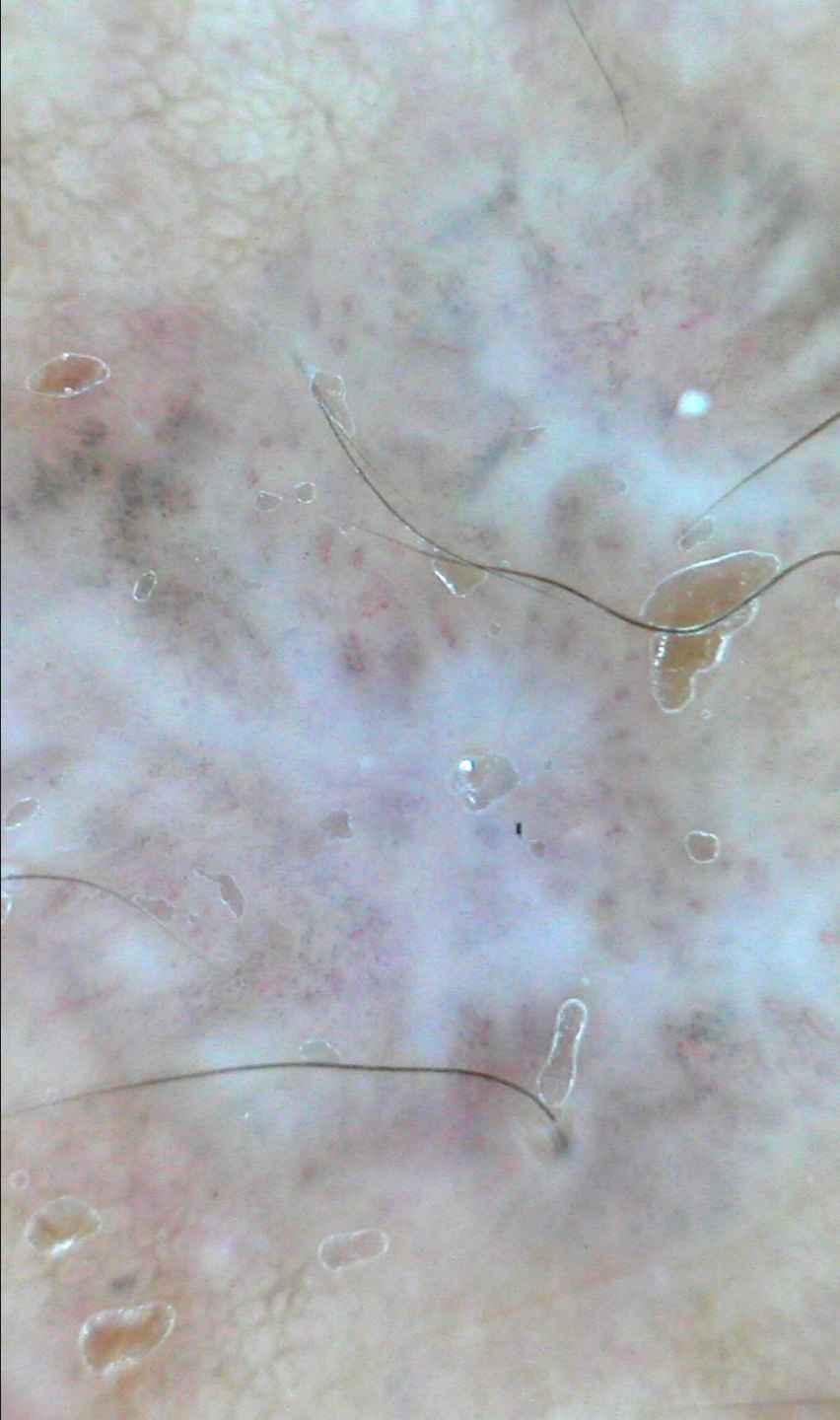


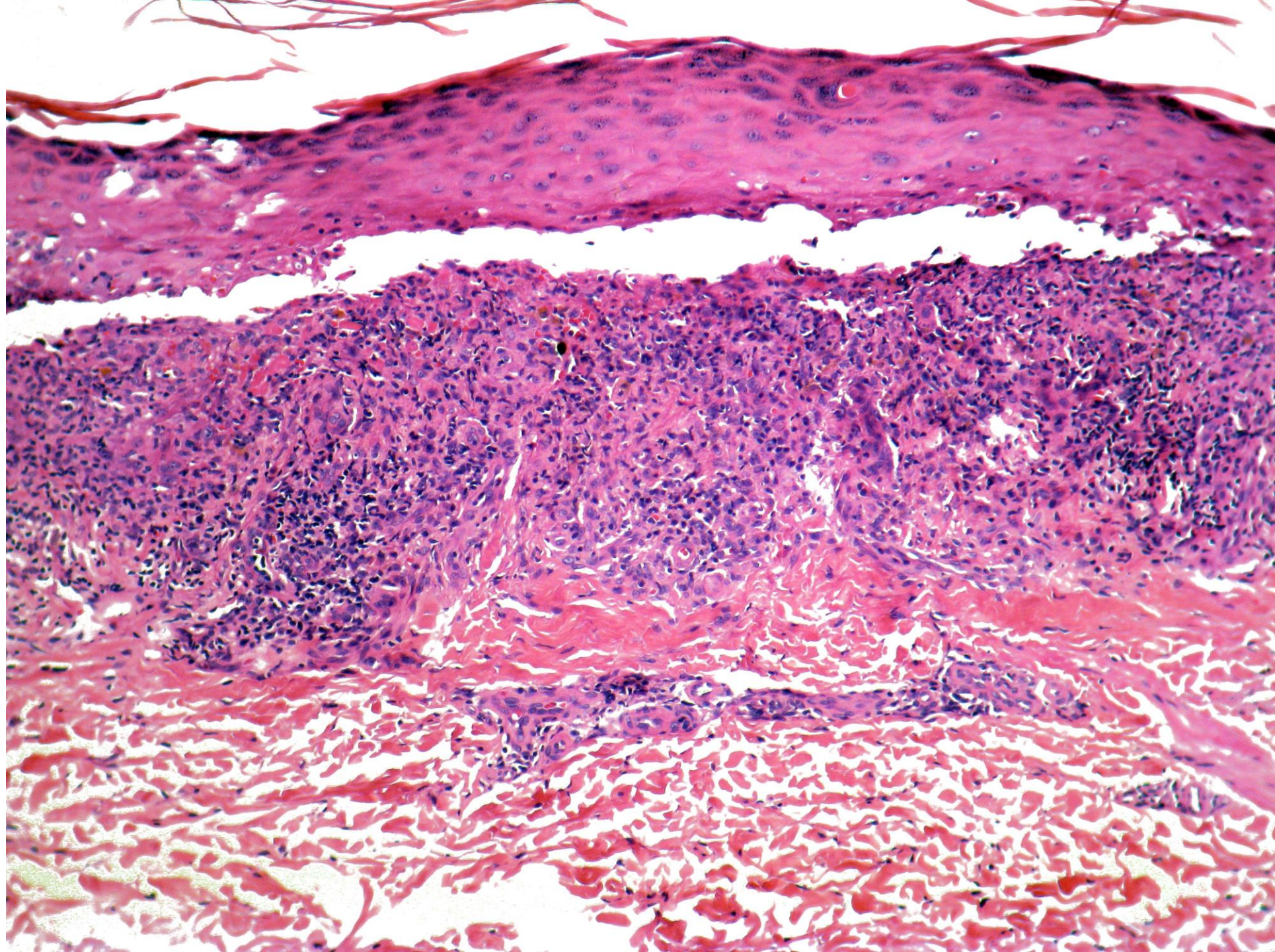
Estrías de Wickham

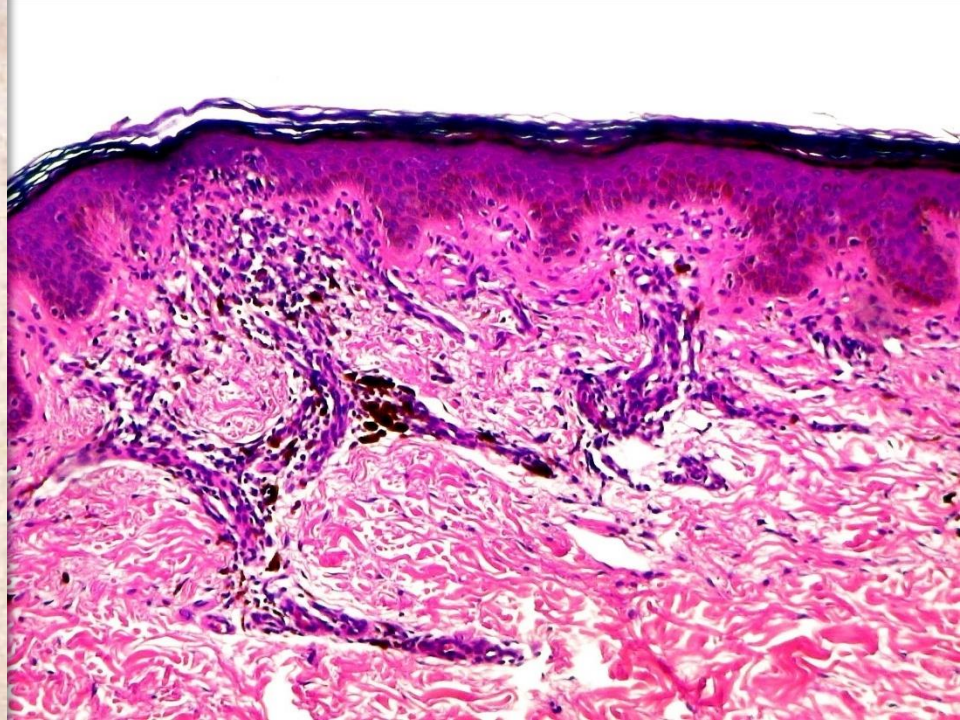
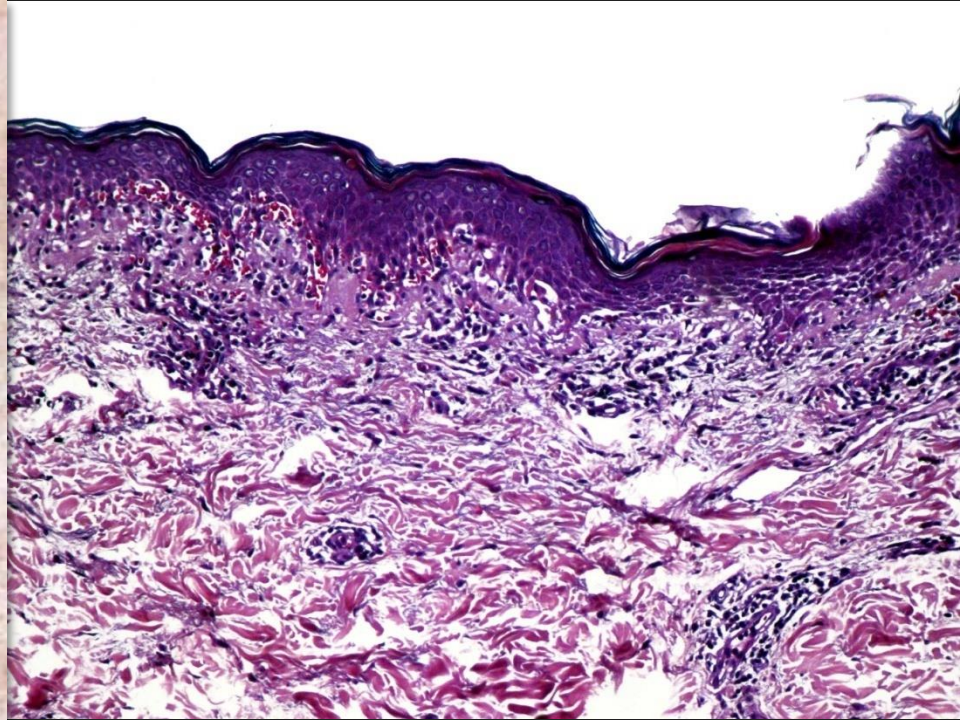
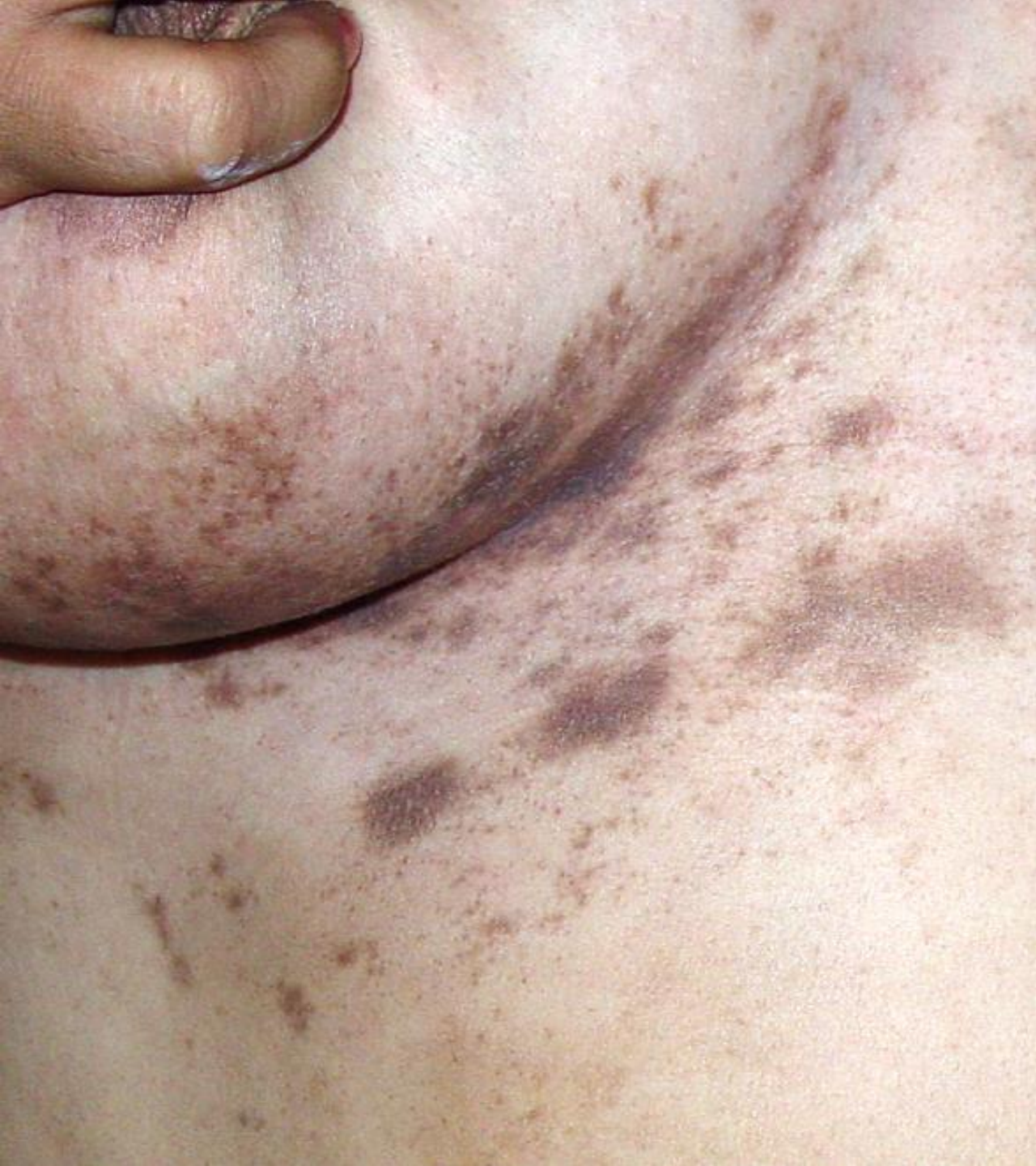

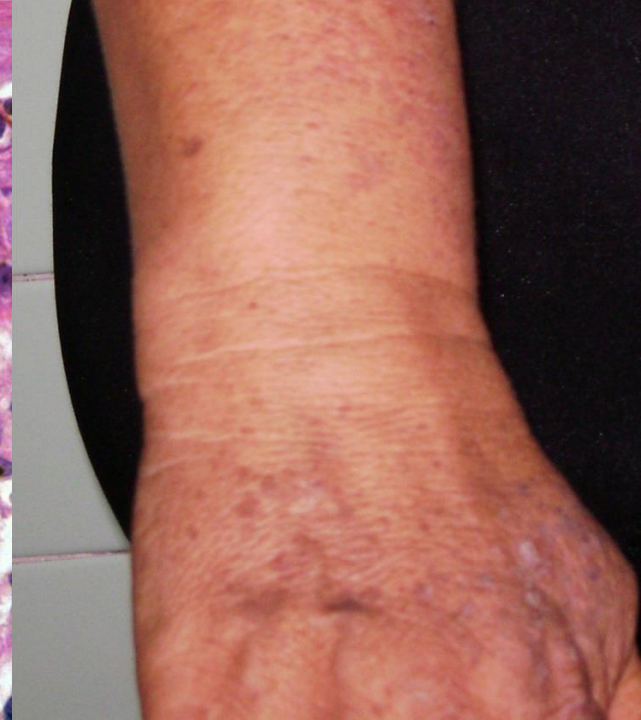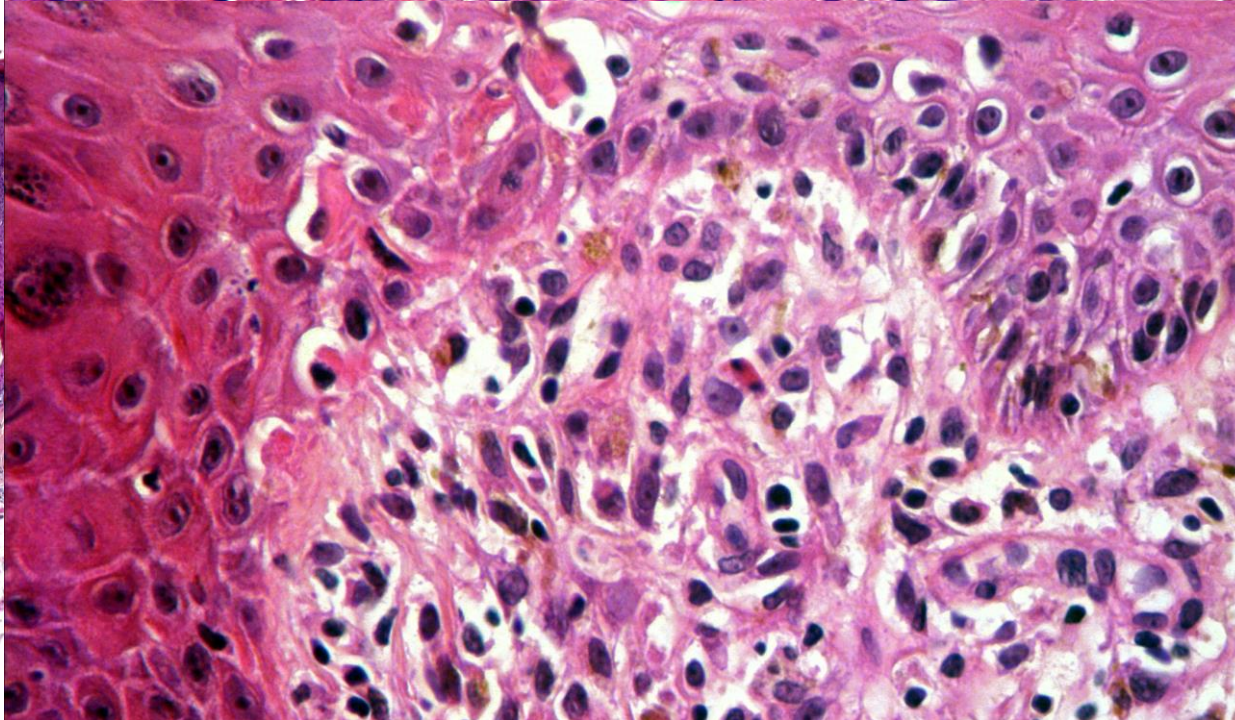
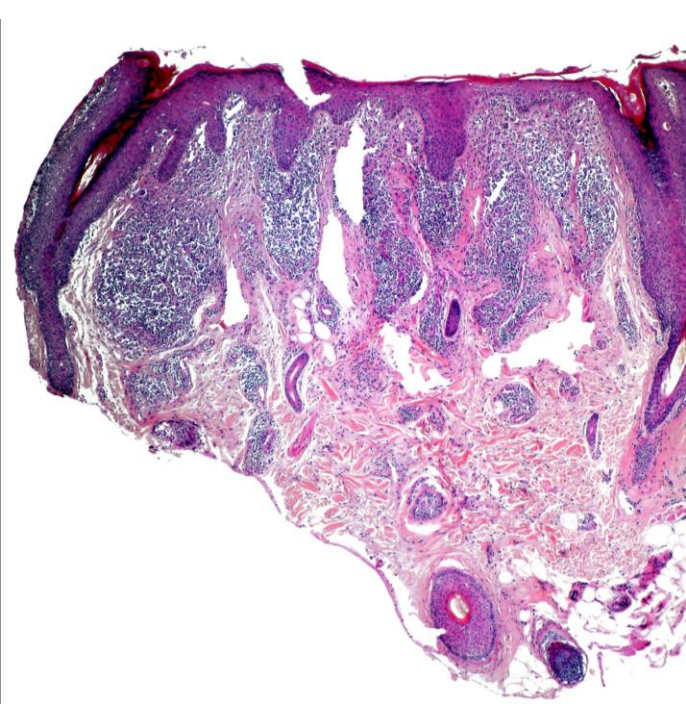
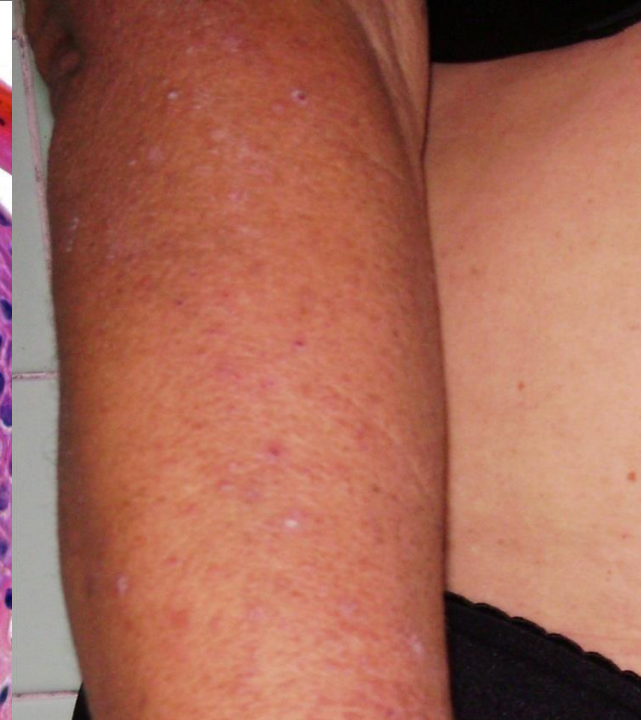
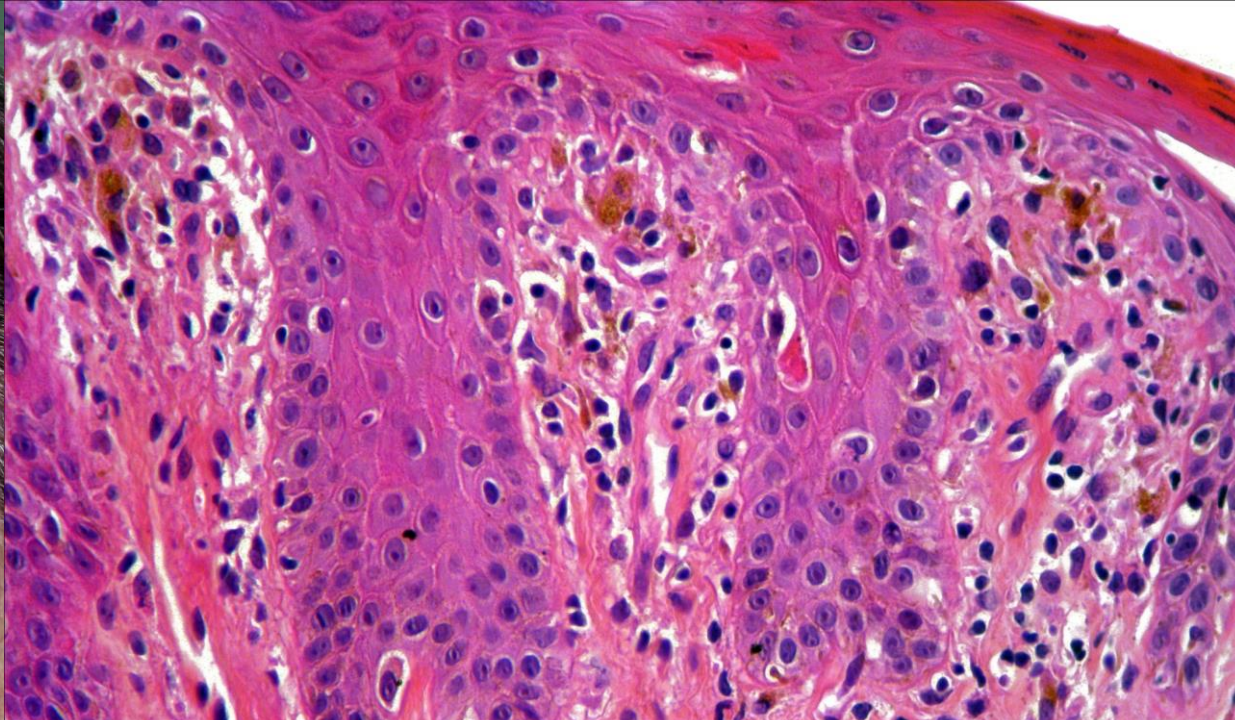
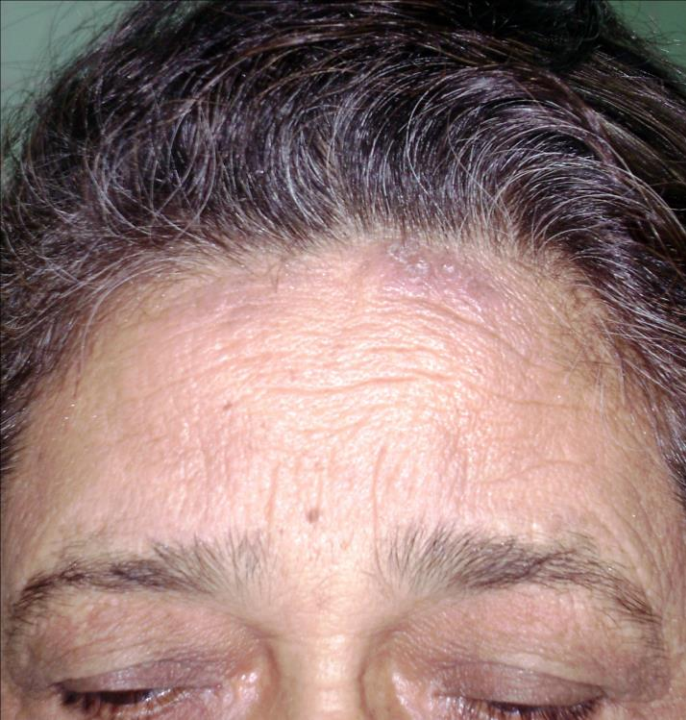Espacios de Caspari -Joseph

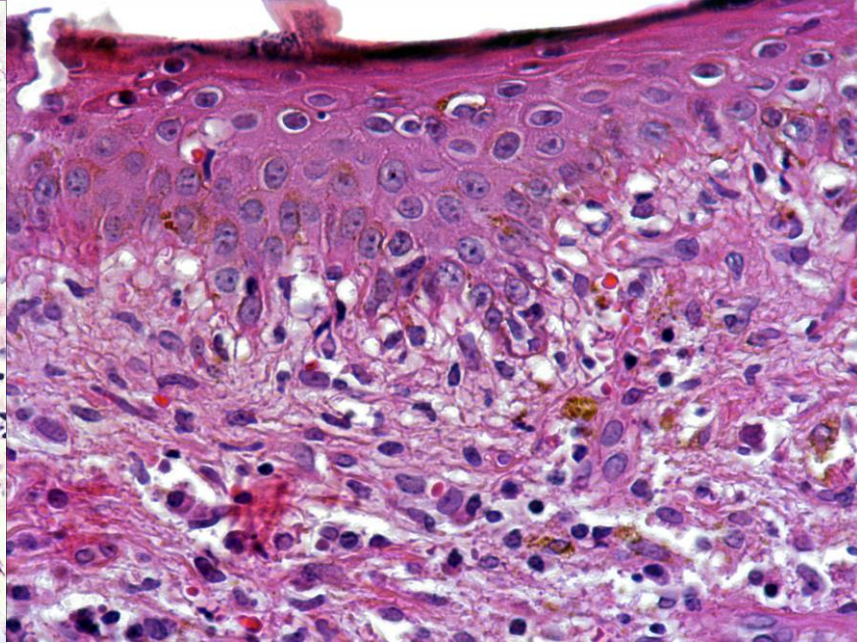
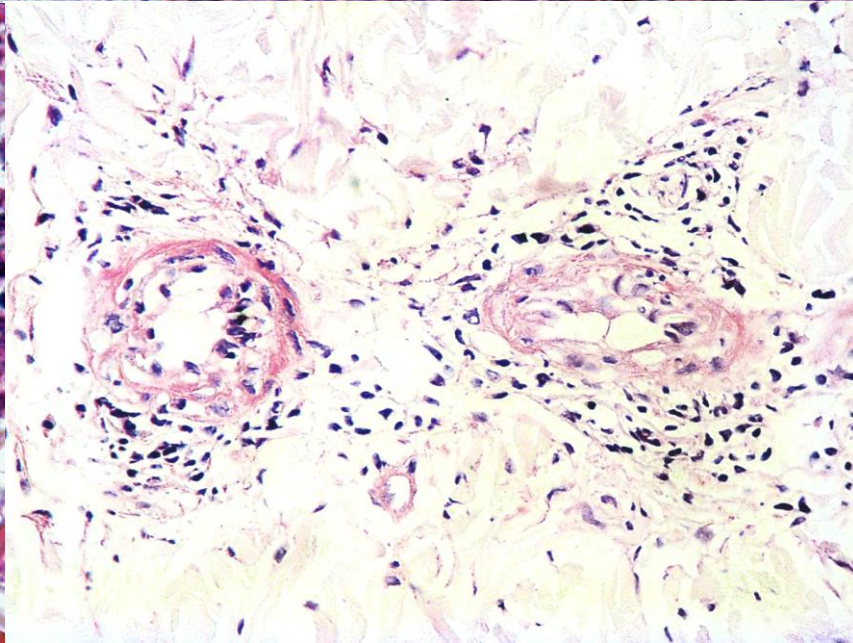
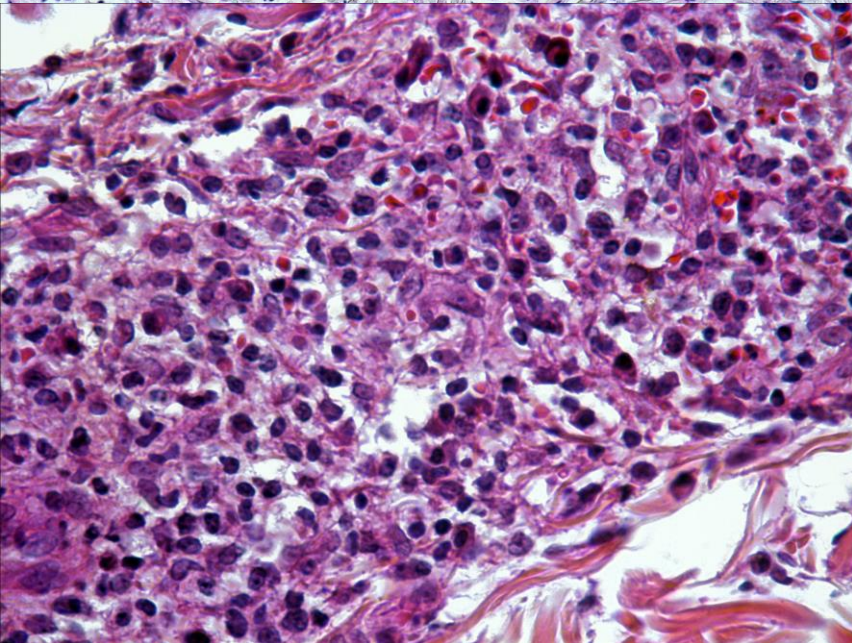
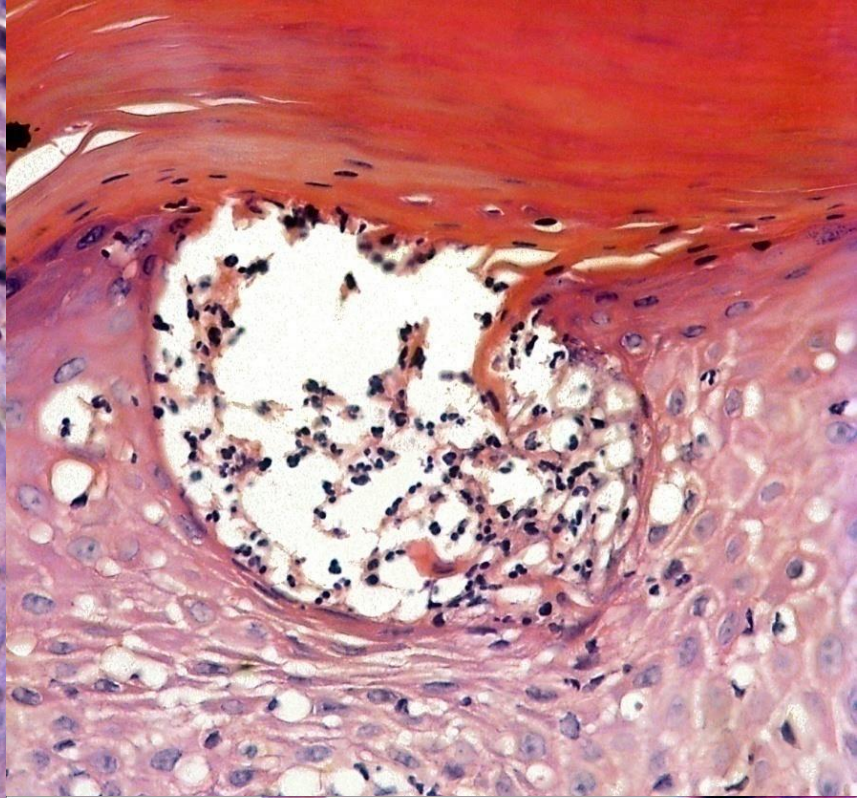
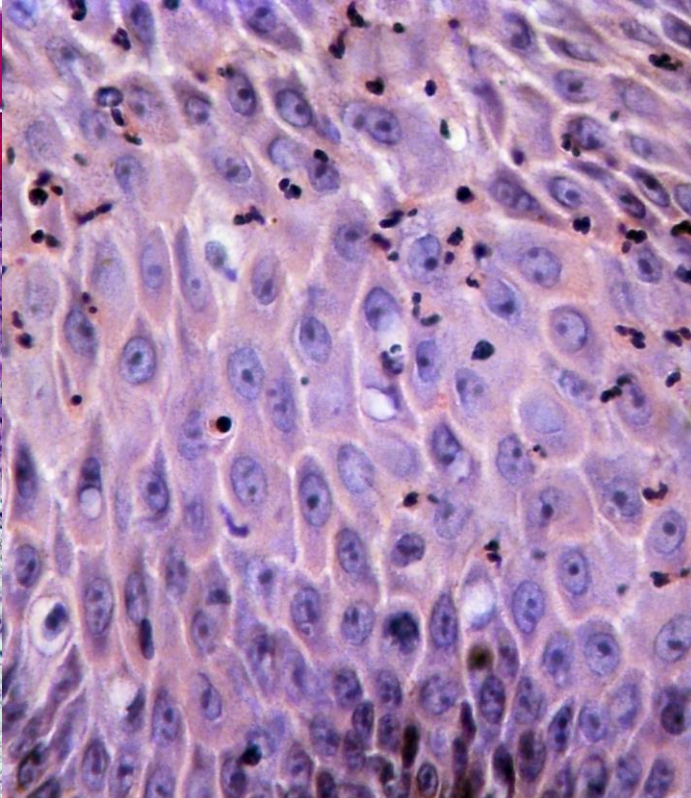
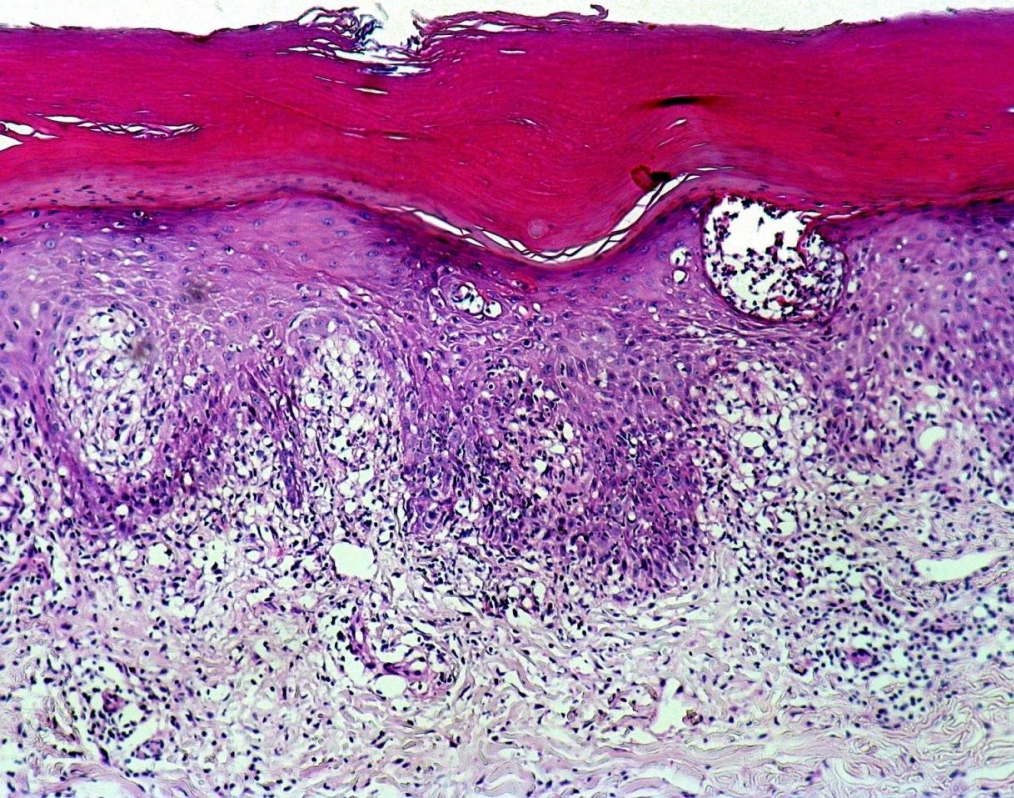


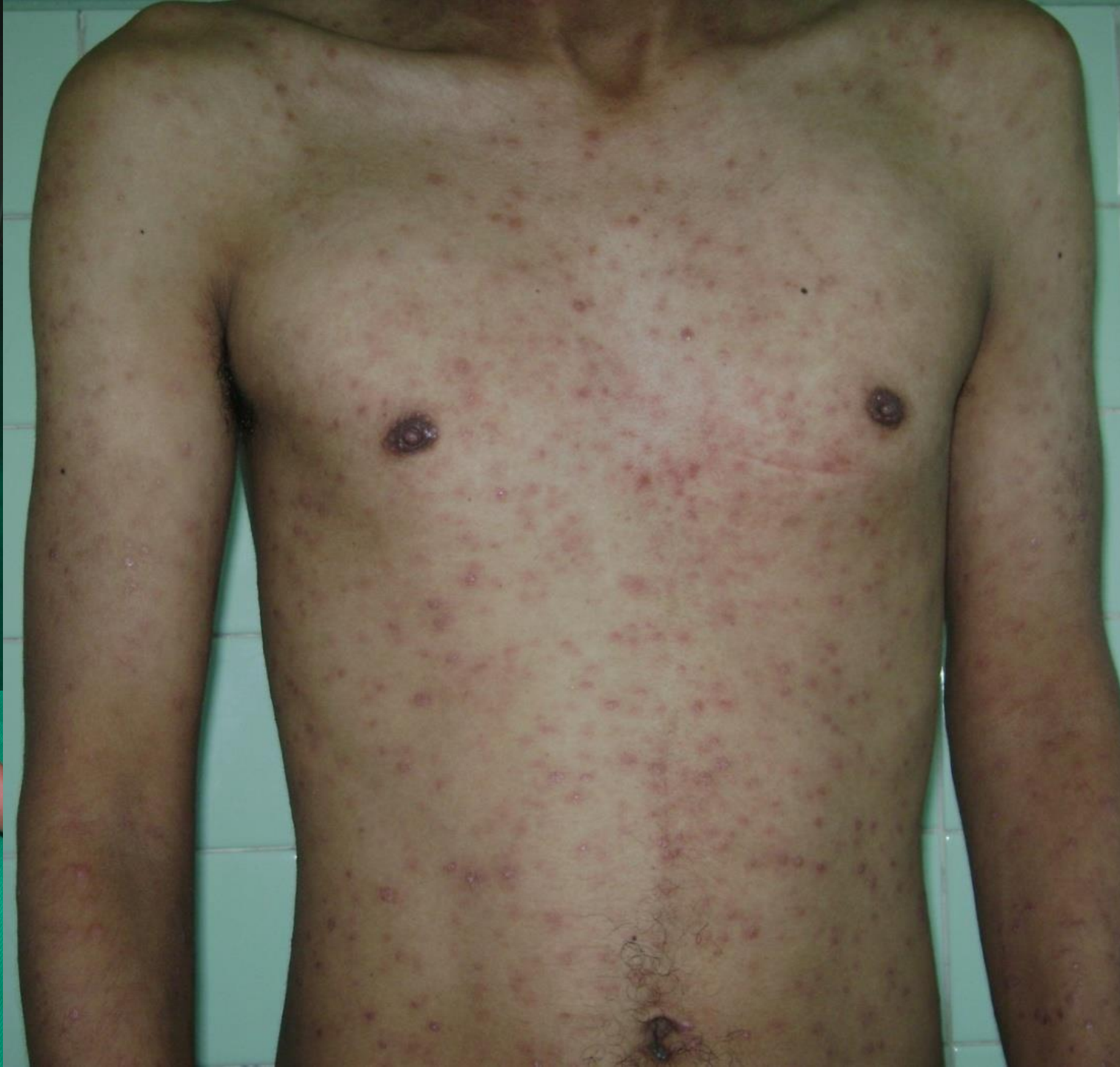
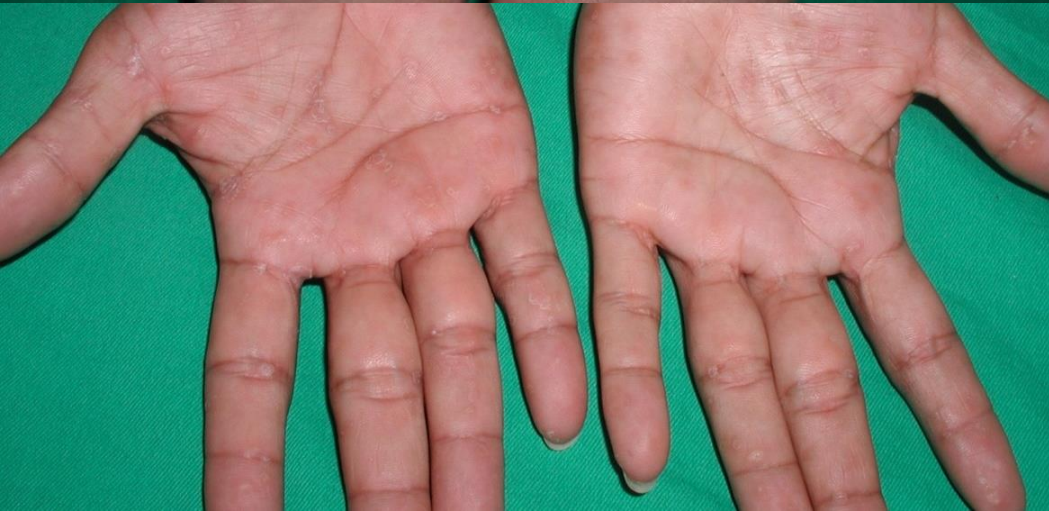
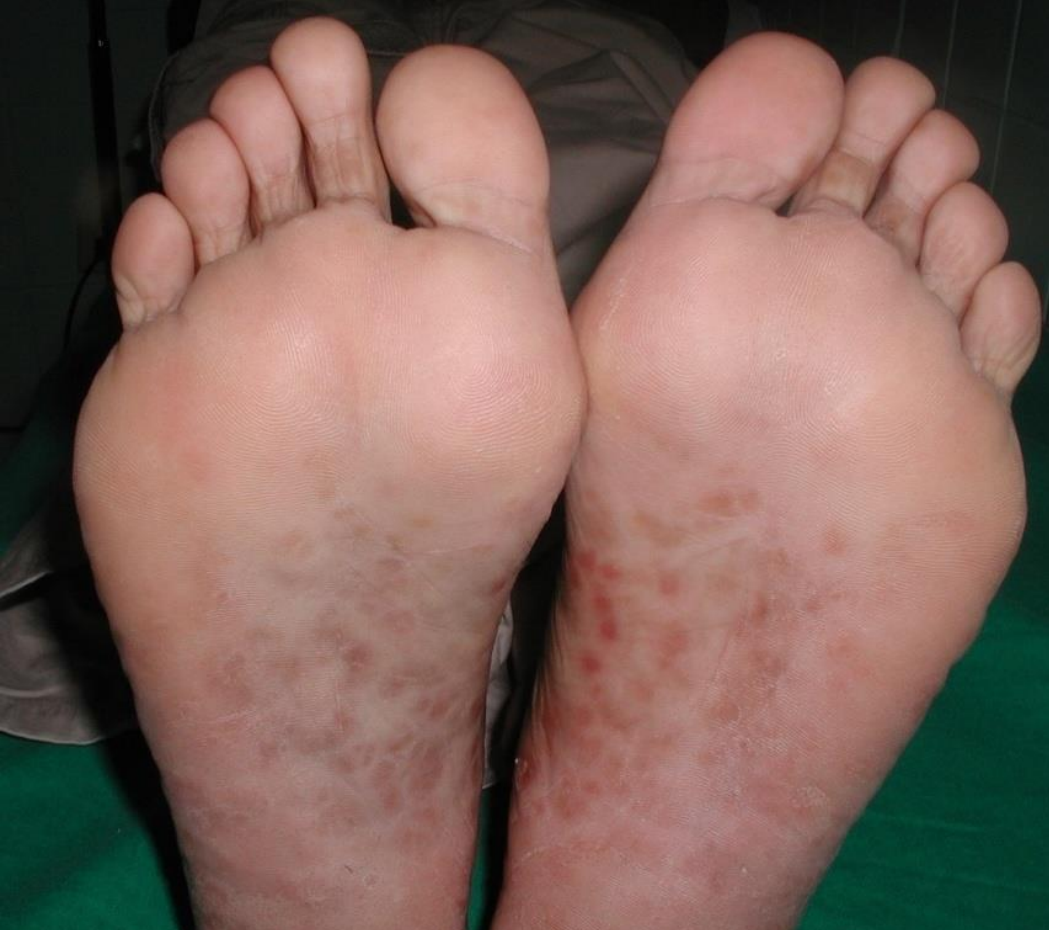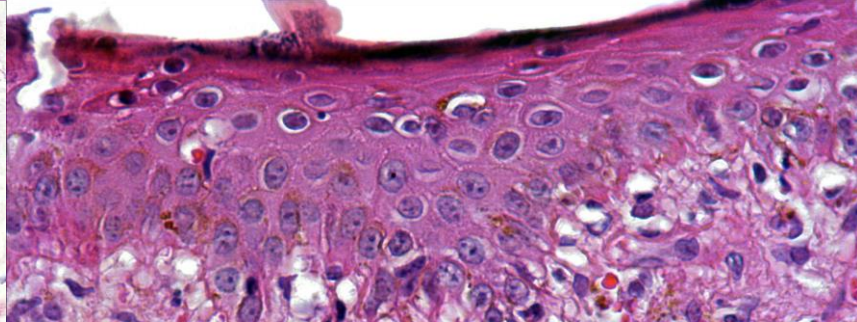
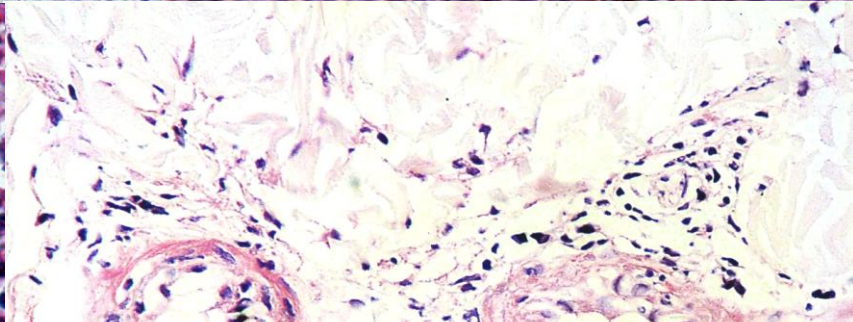
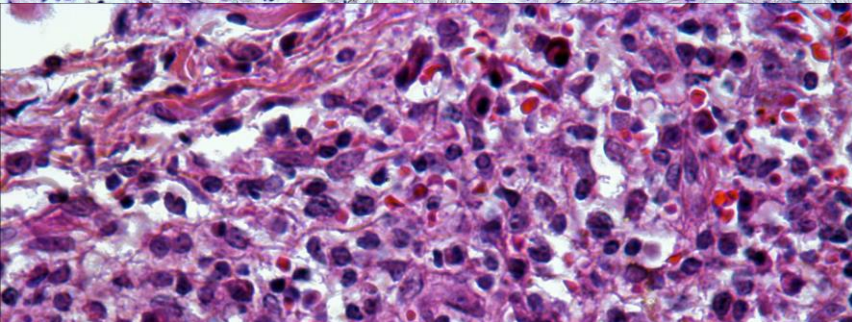
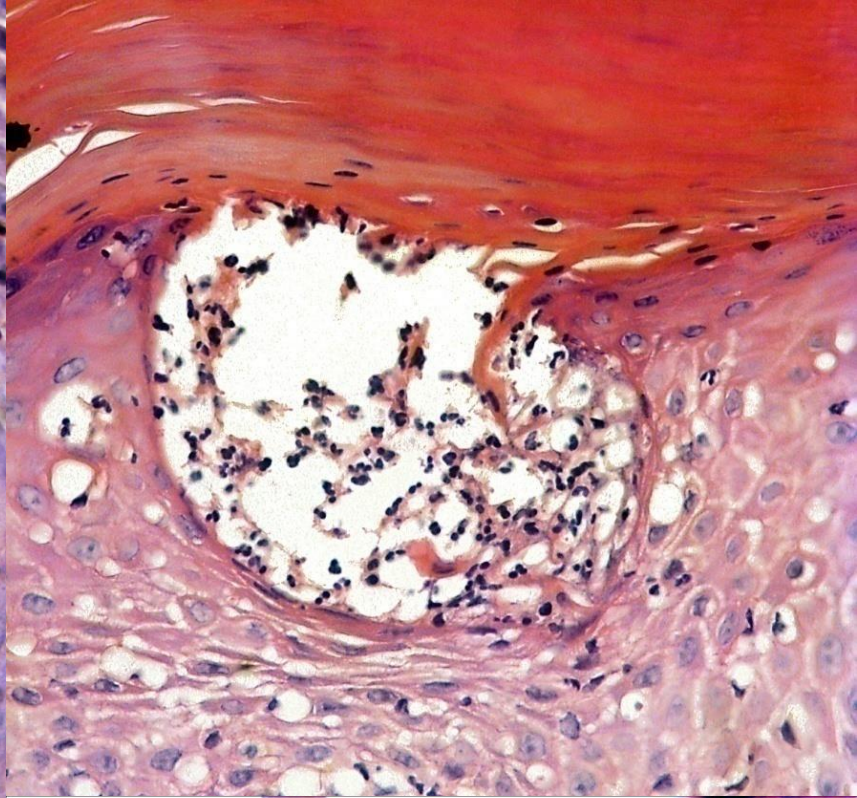
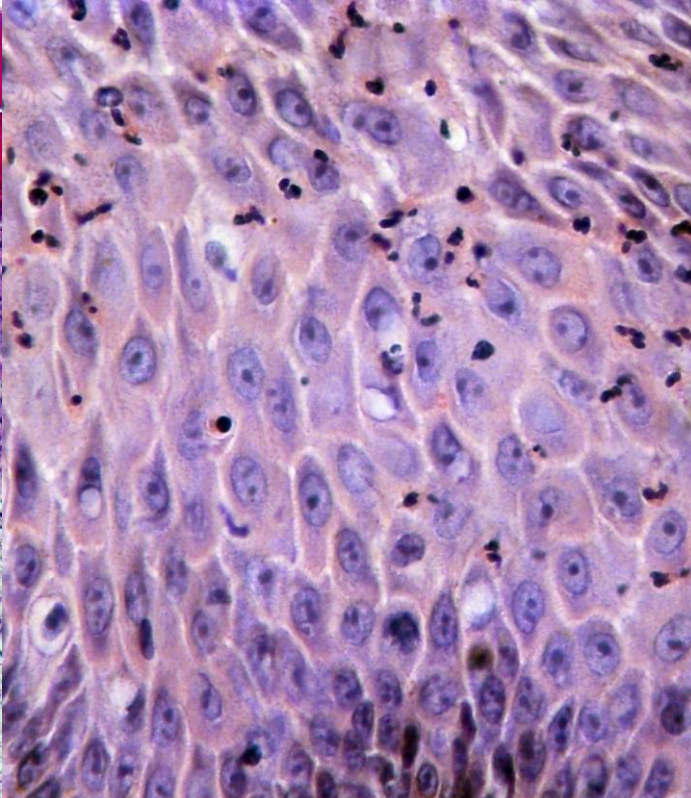
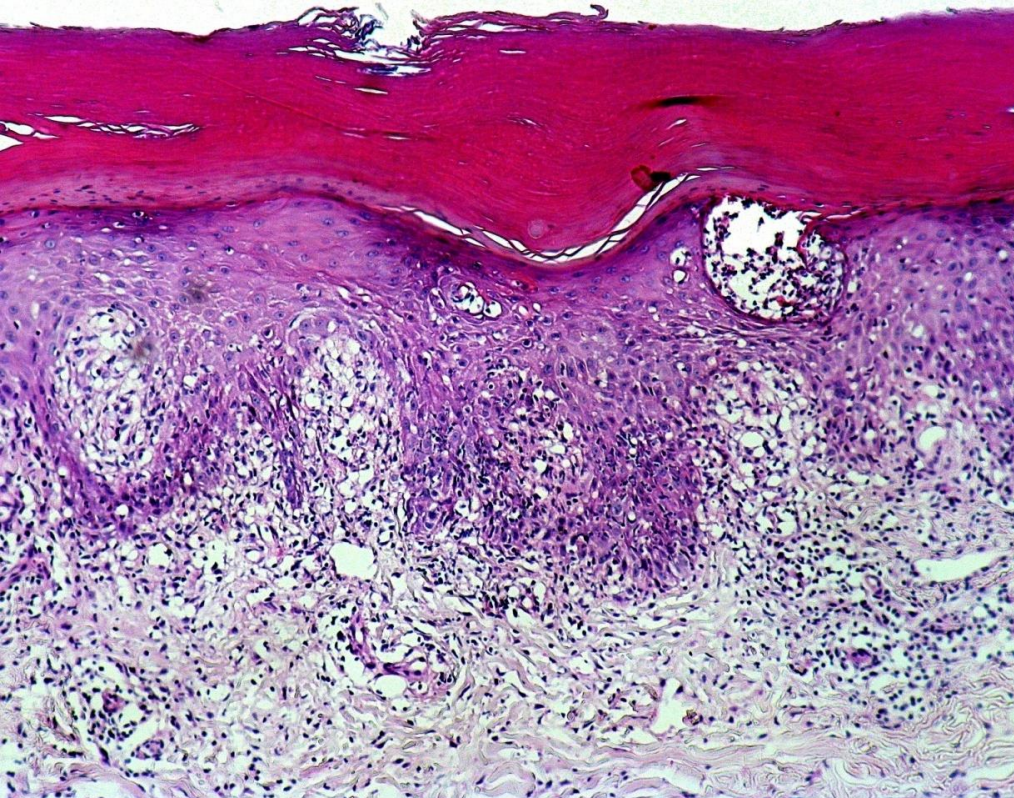




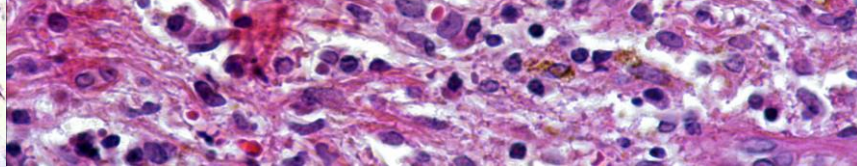
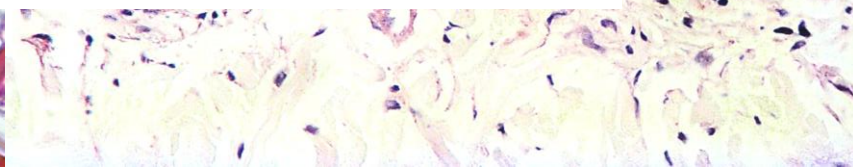
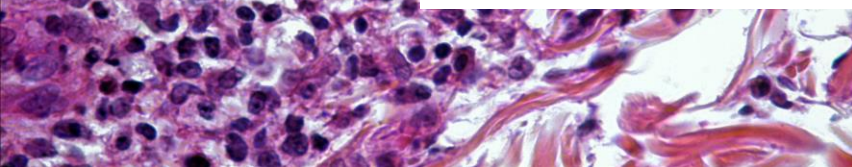


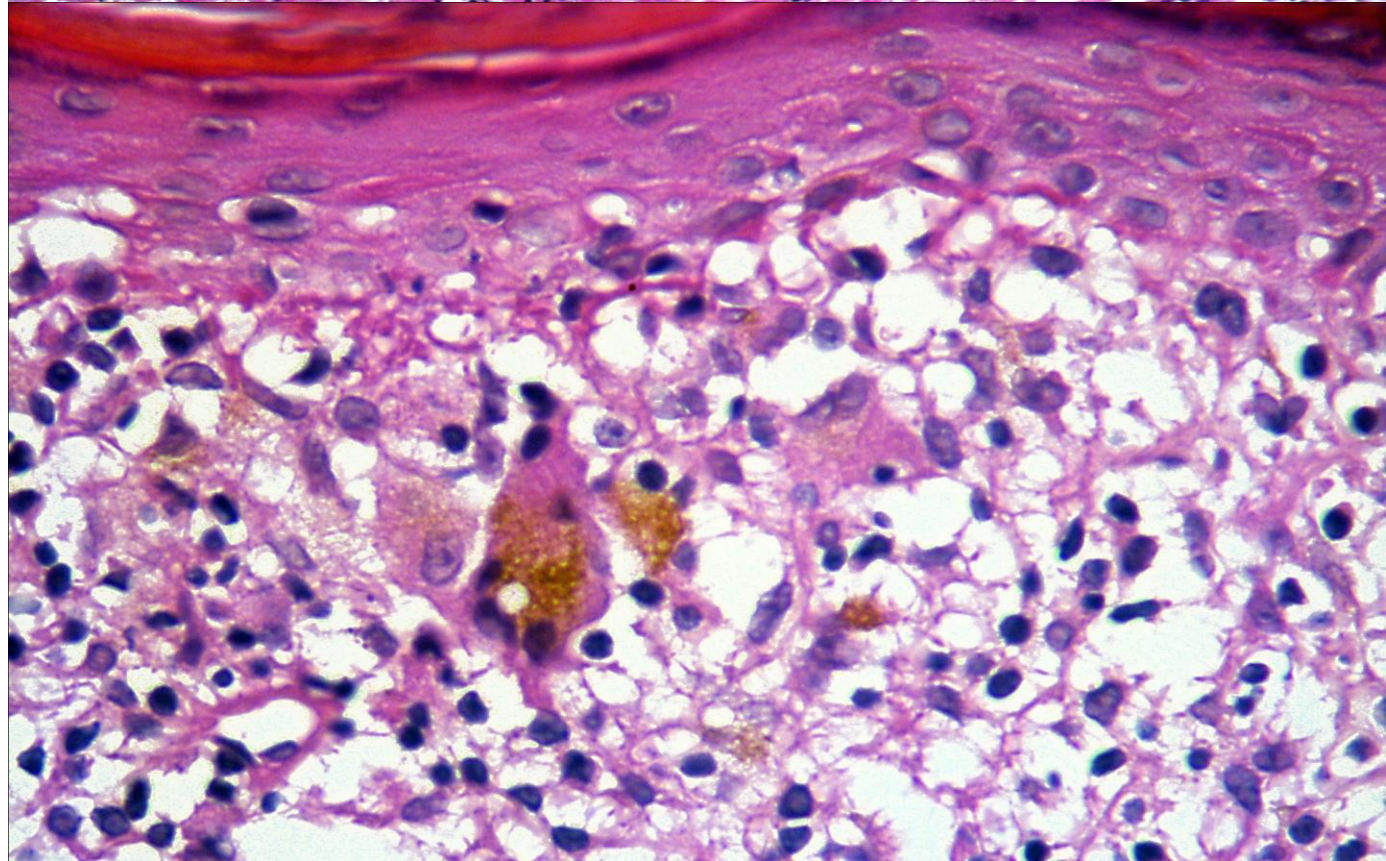
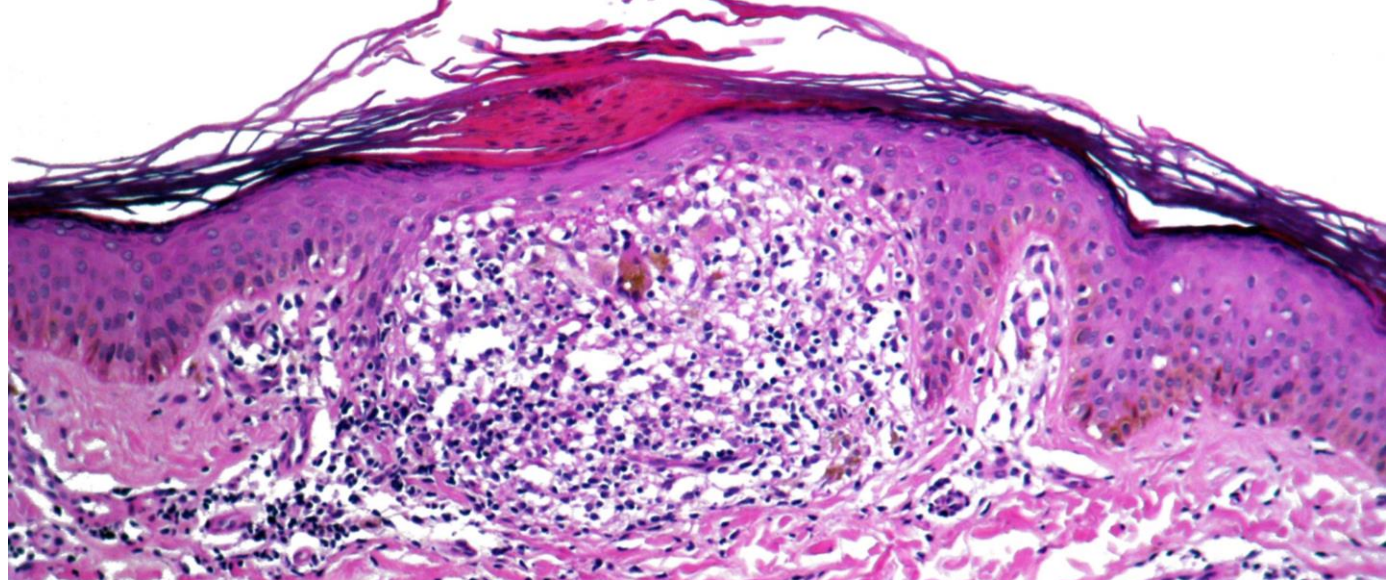
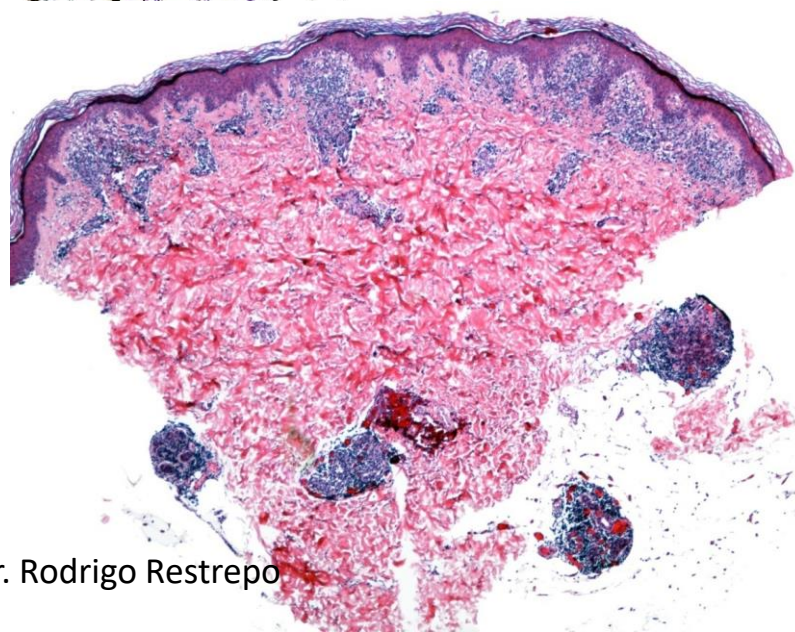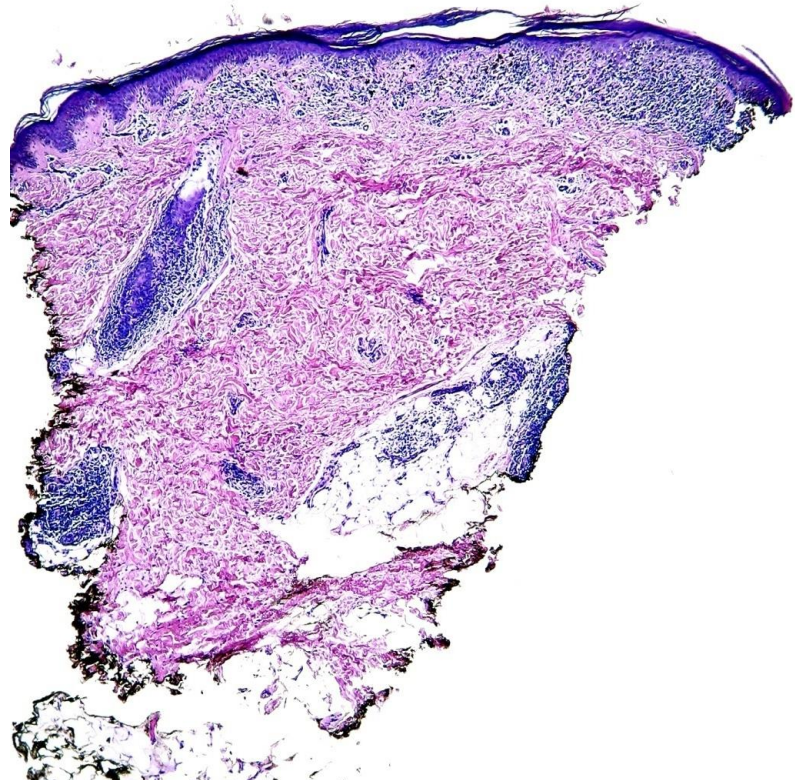


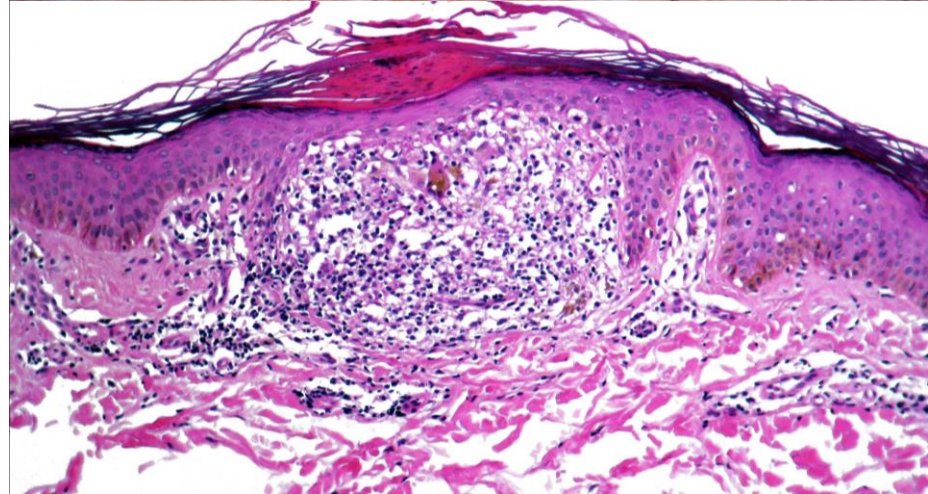
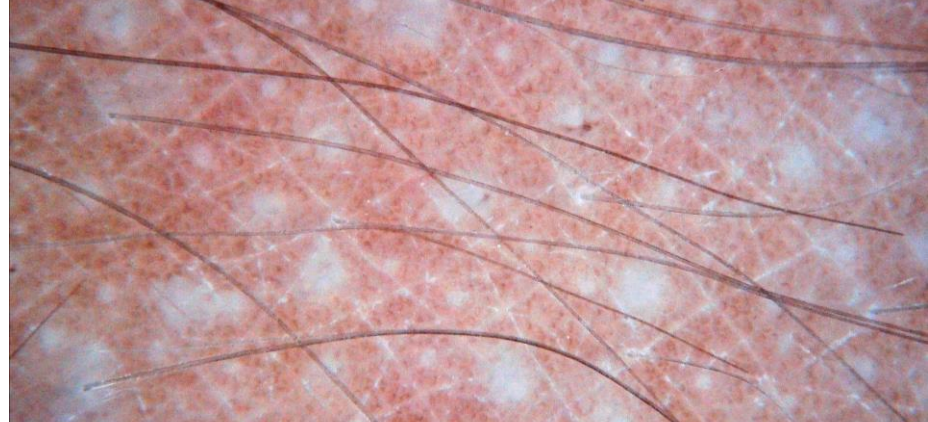
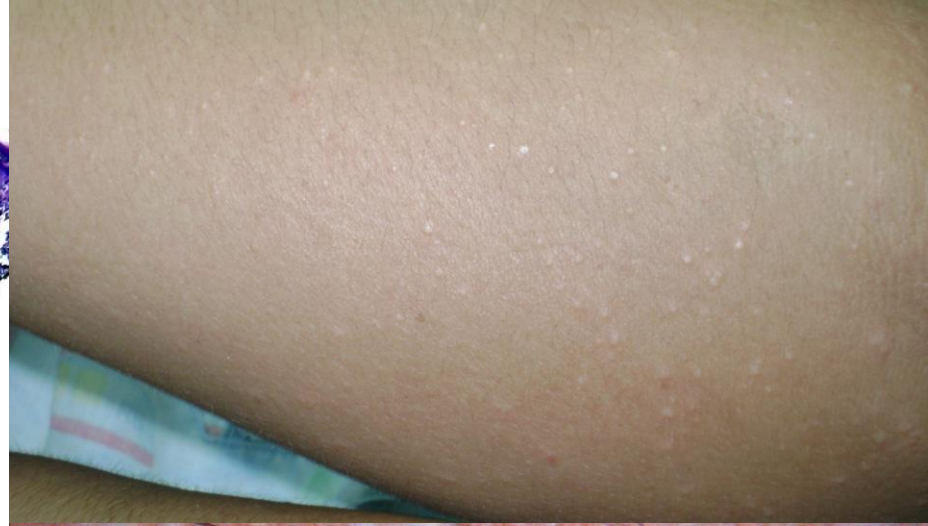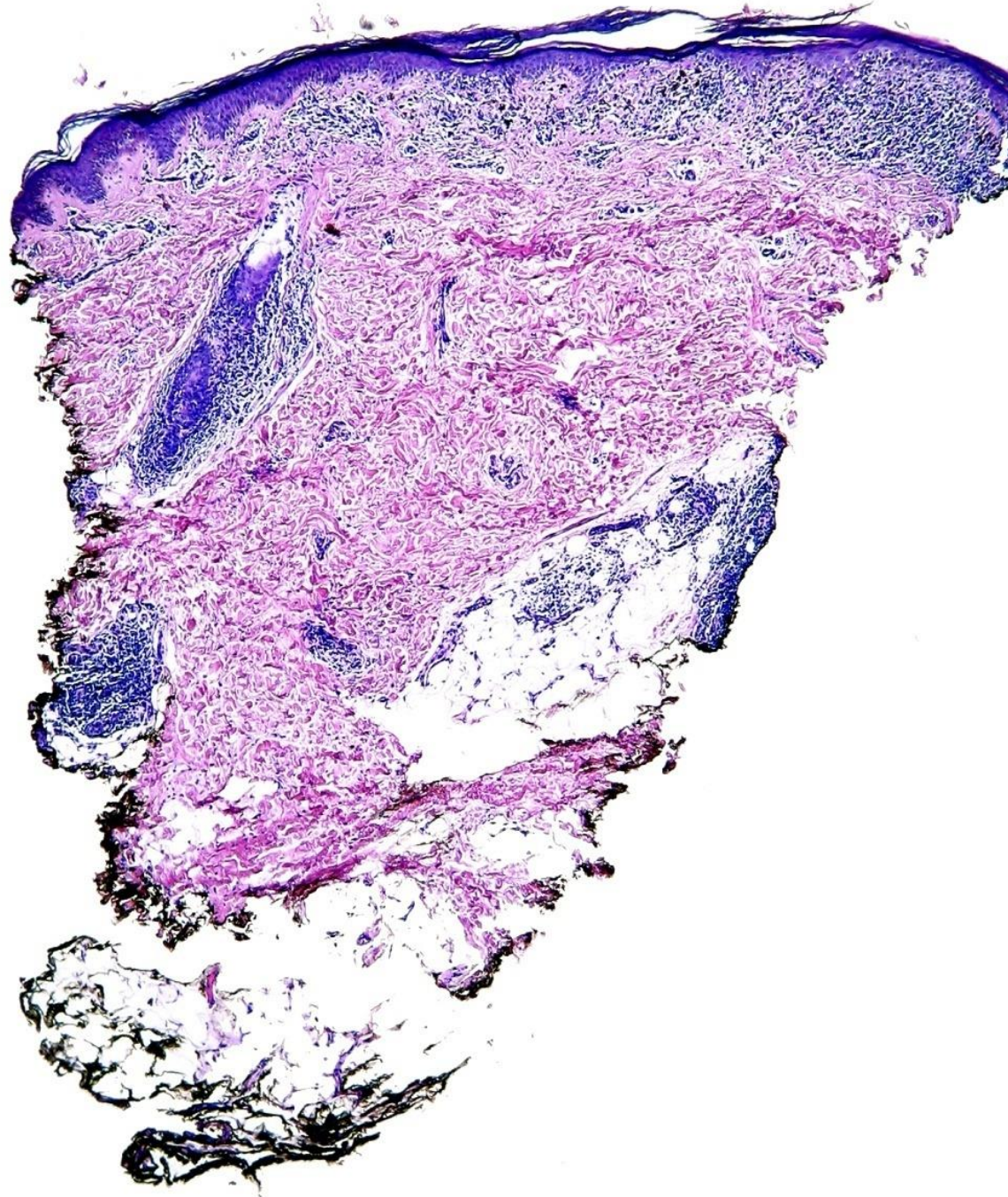




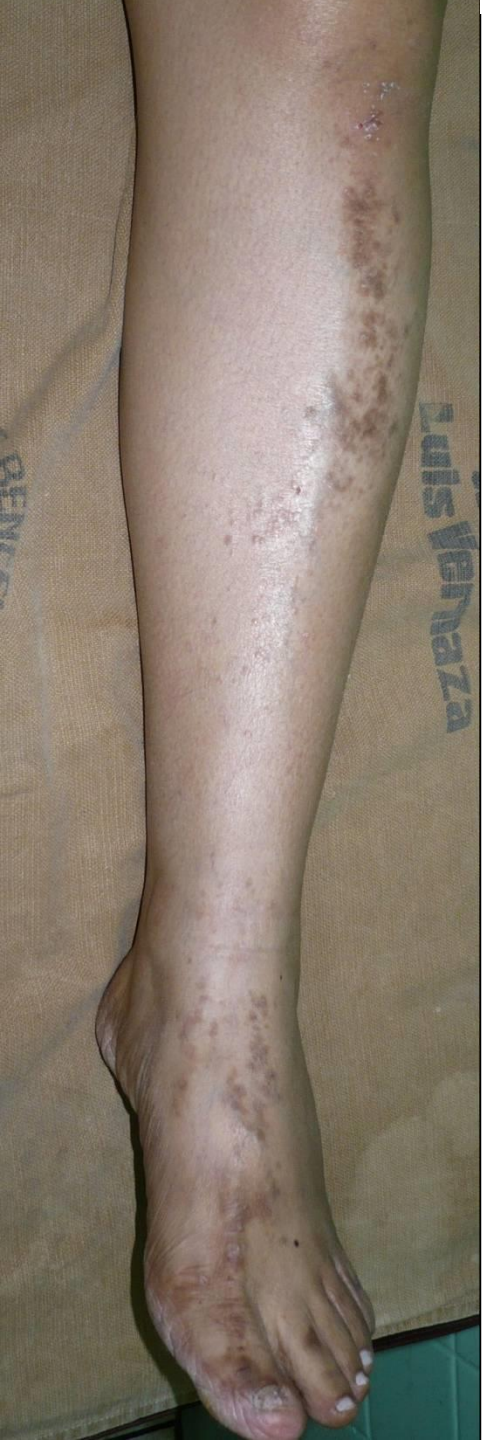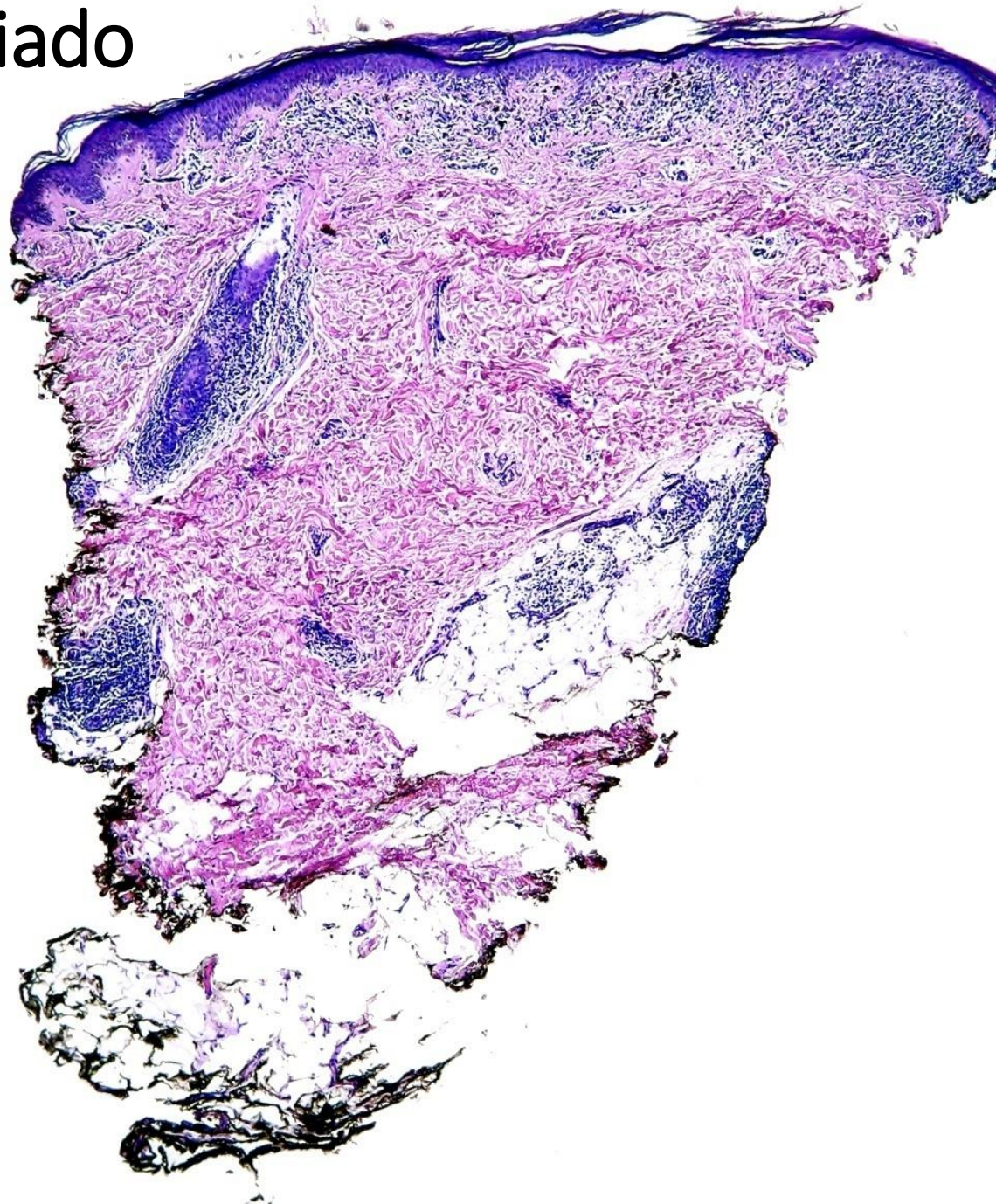
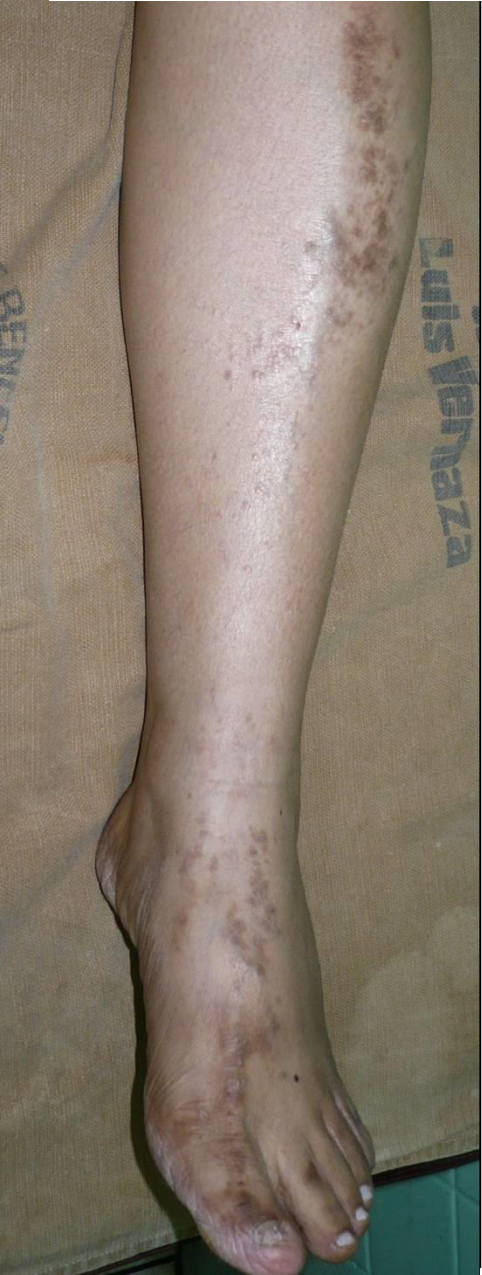SÍFILIS SECUNDARIA



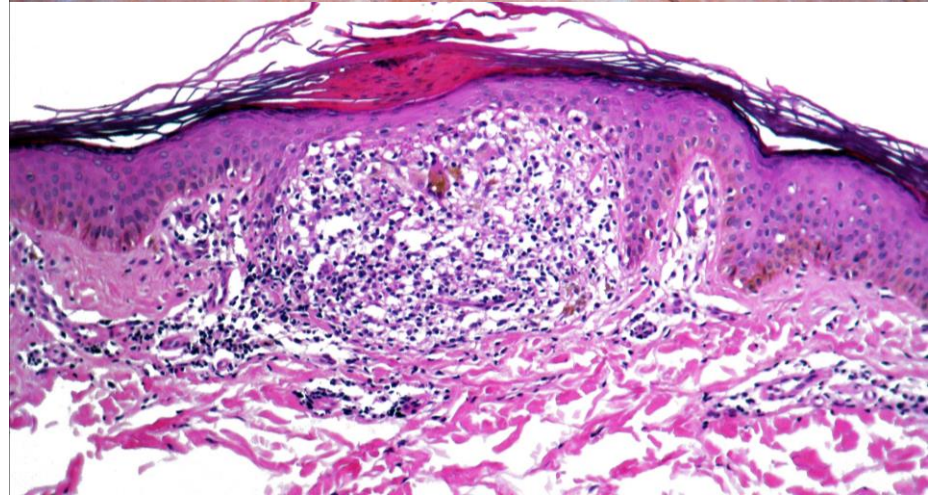
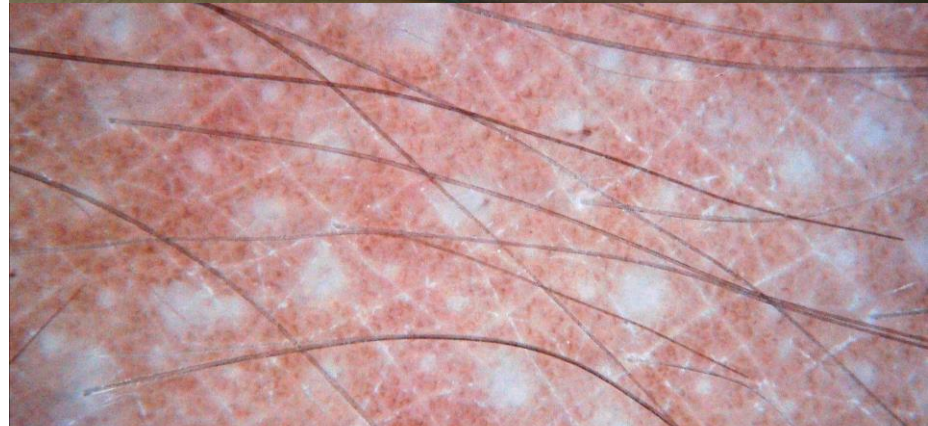
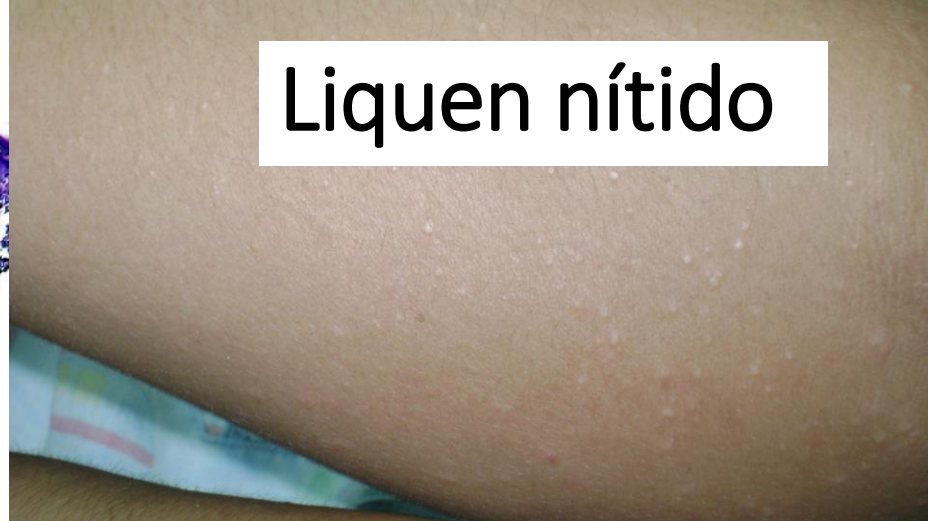



Liquen estriado



Liquen nítido



Interface Dermatitis

A. Neil Crowson, MD; Cynthia M. Magro, MD; Martin C. Mihm, Jr, MD

(*Arch Pathol Lab Med.* 2008;132:652–666)

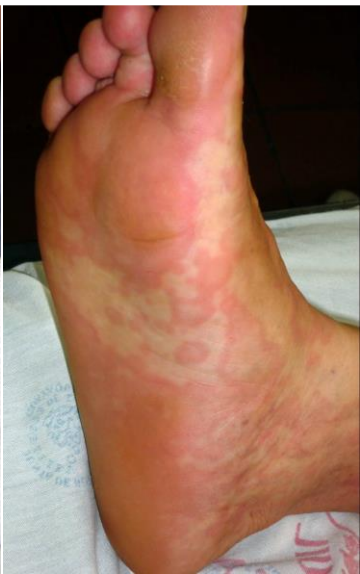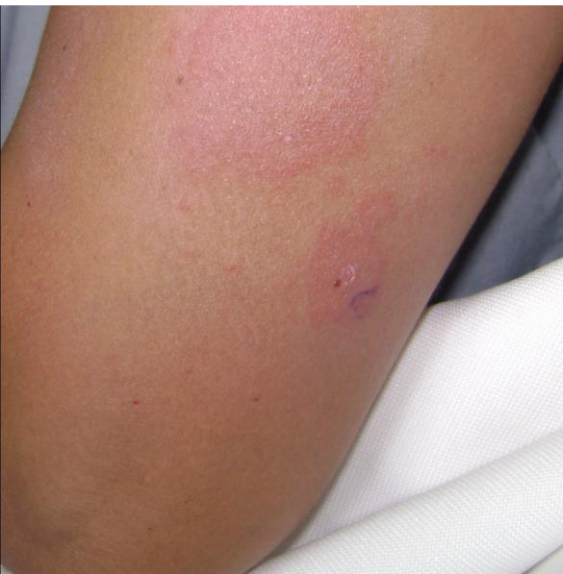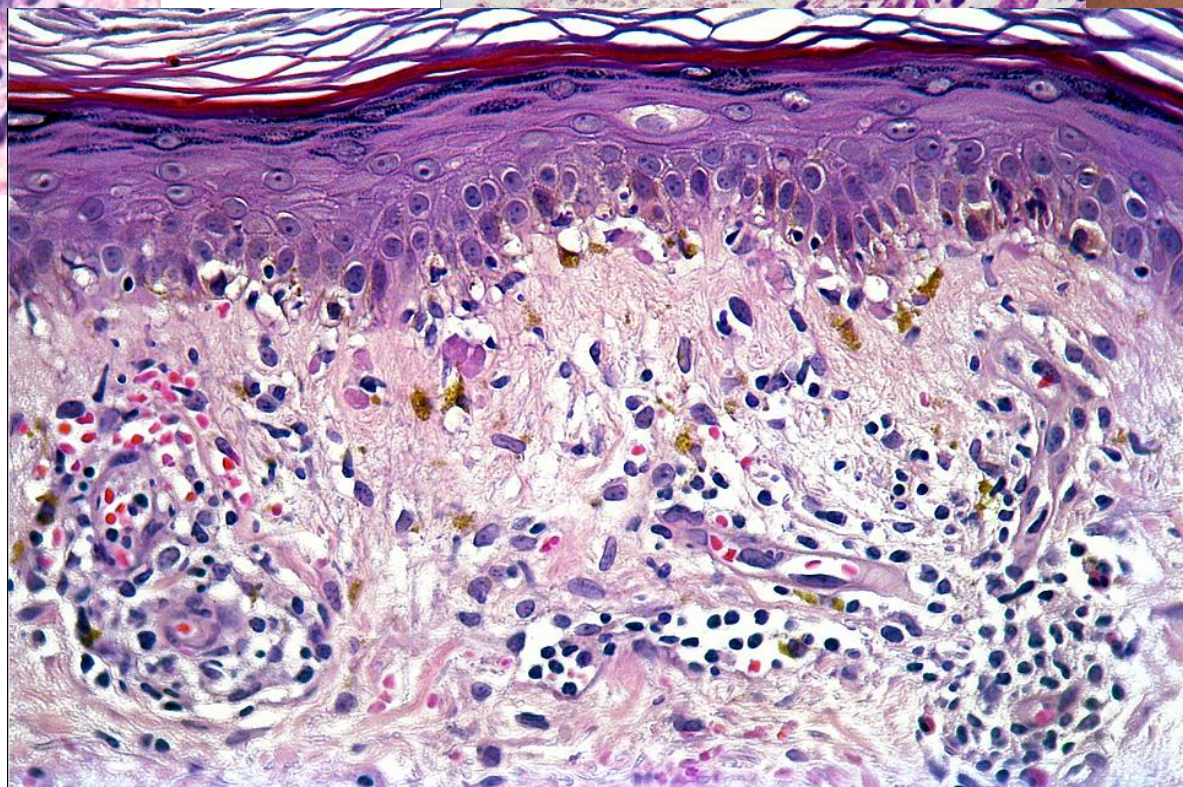
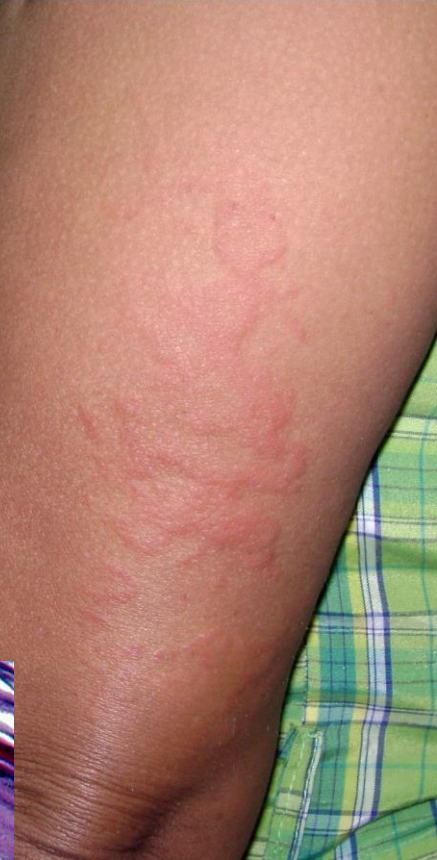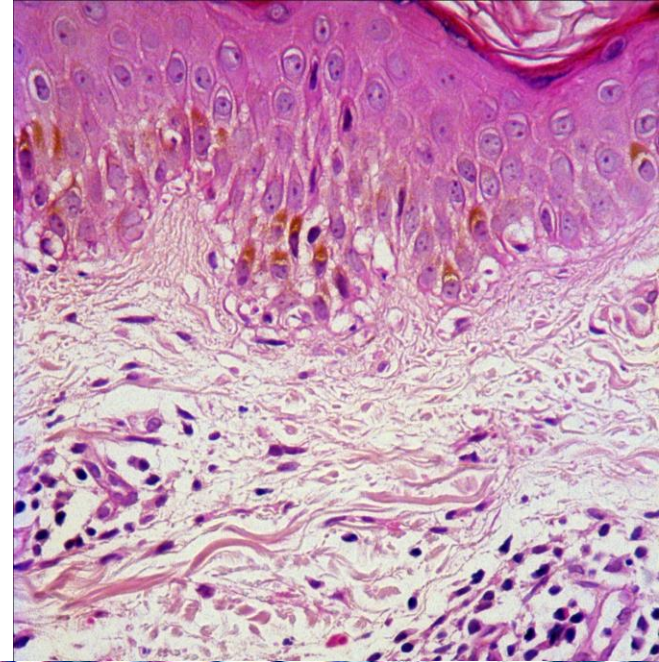
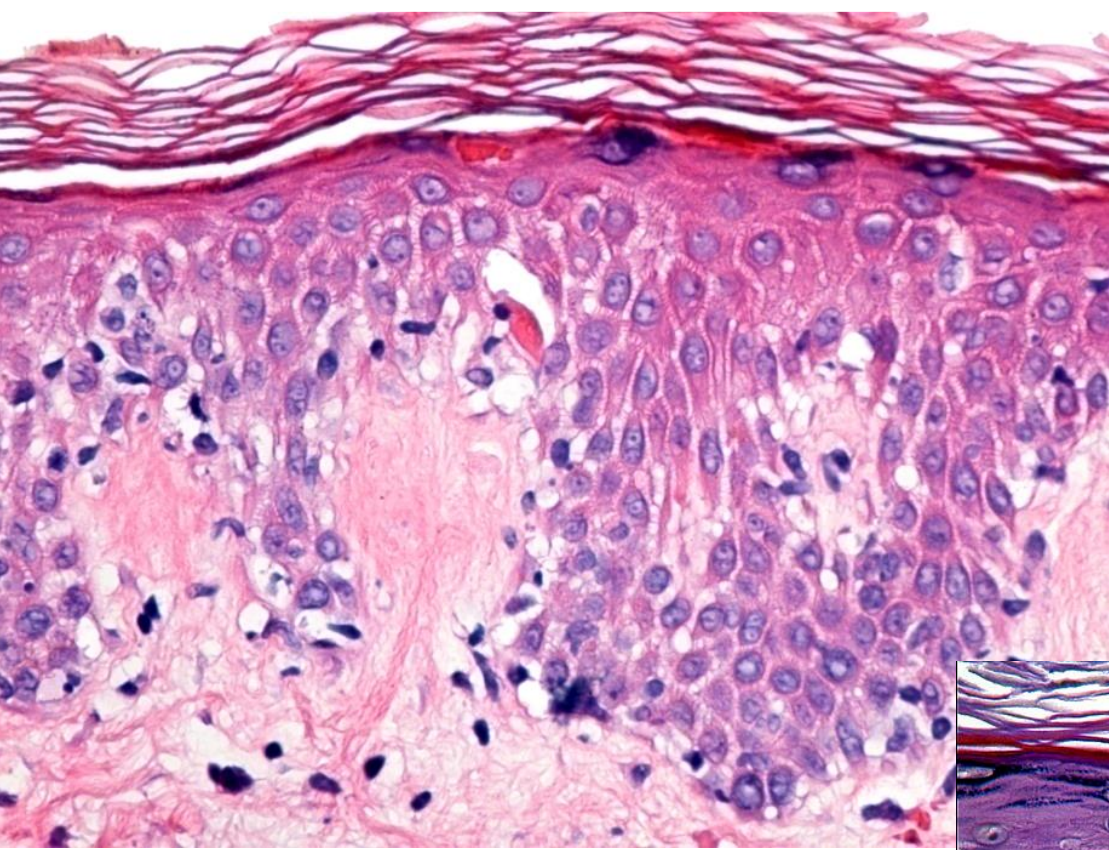
Prototipos

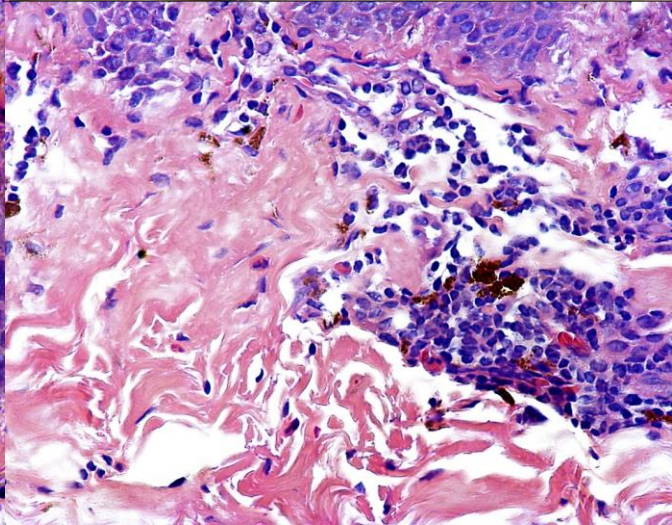
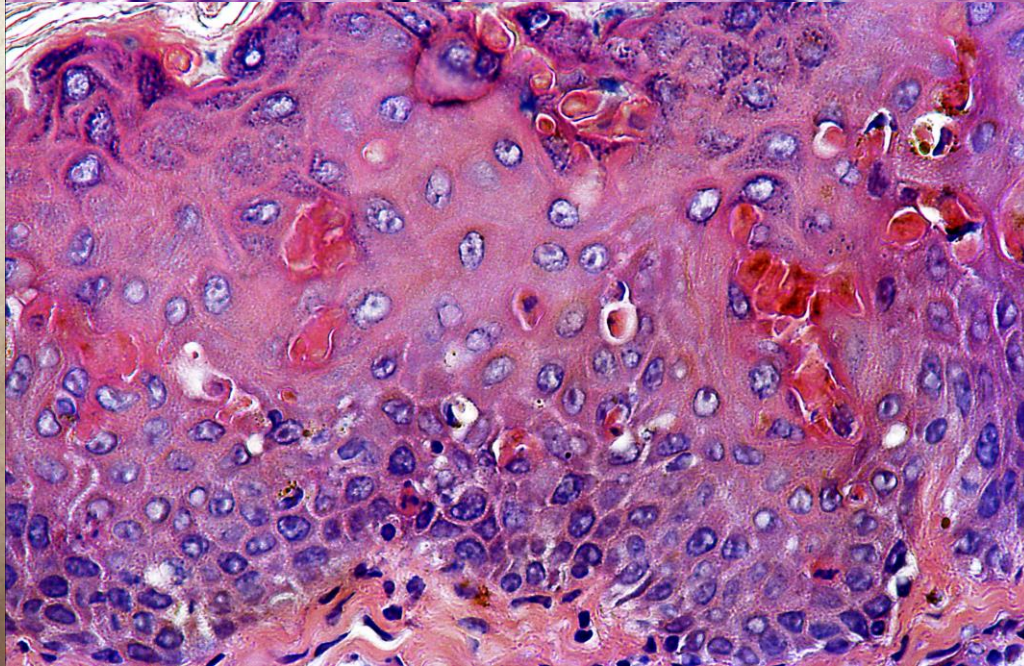
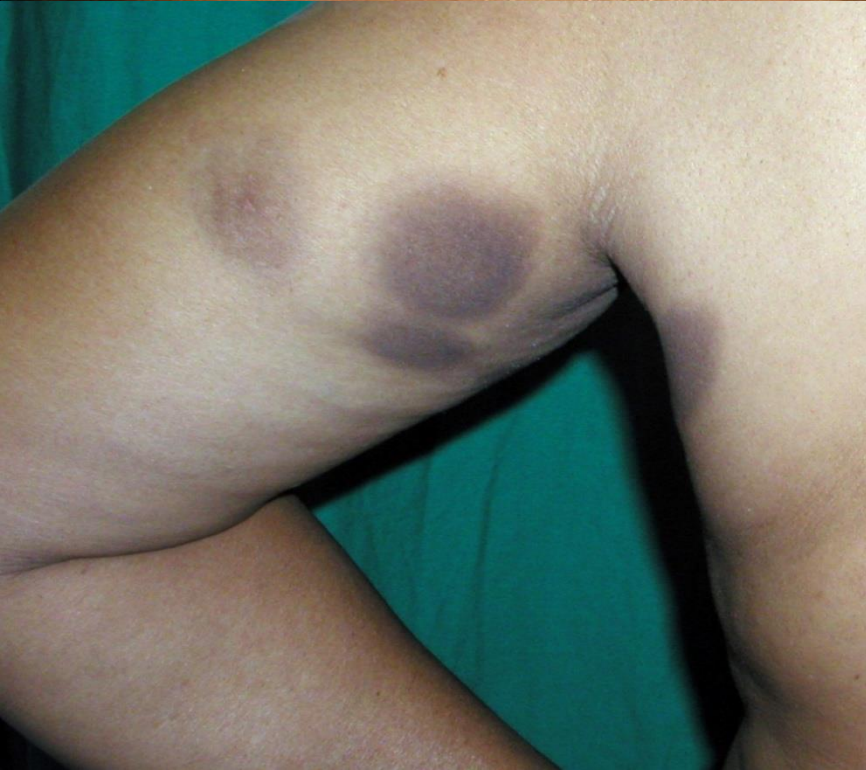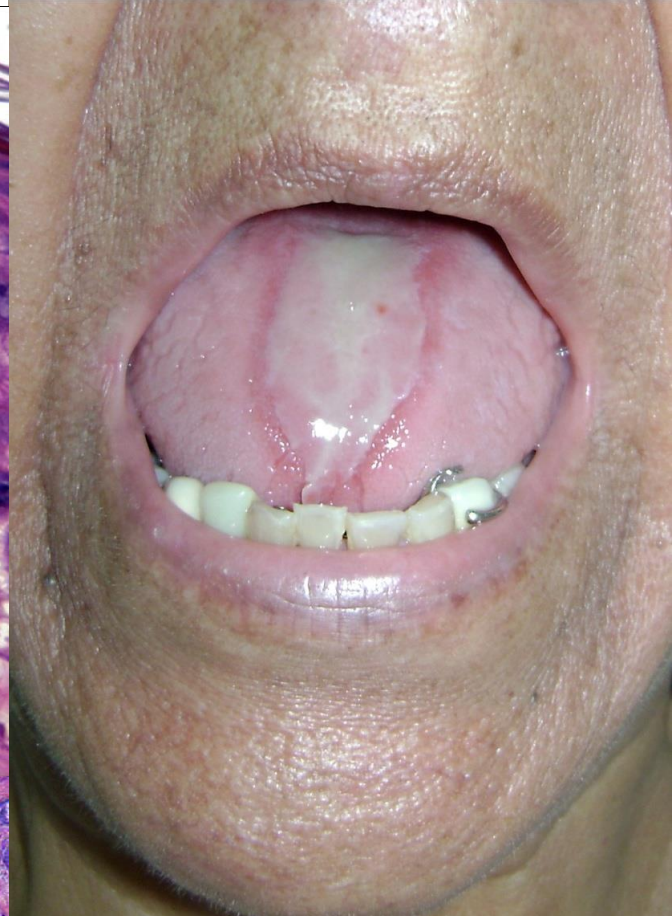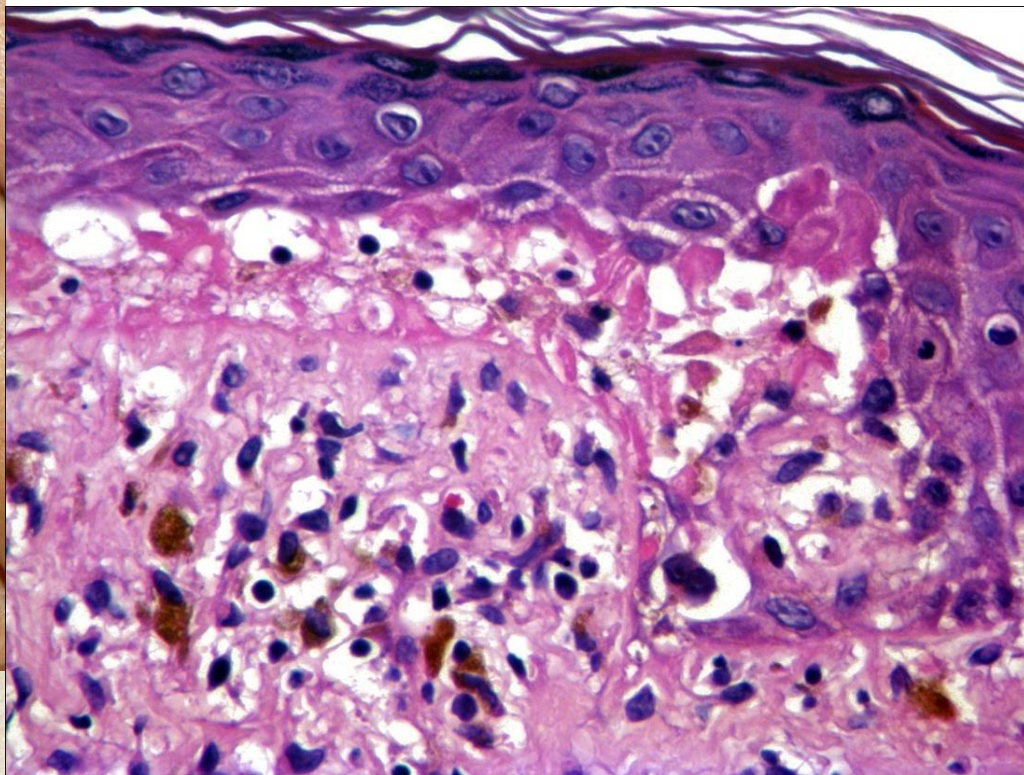
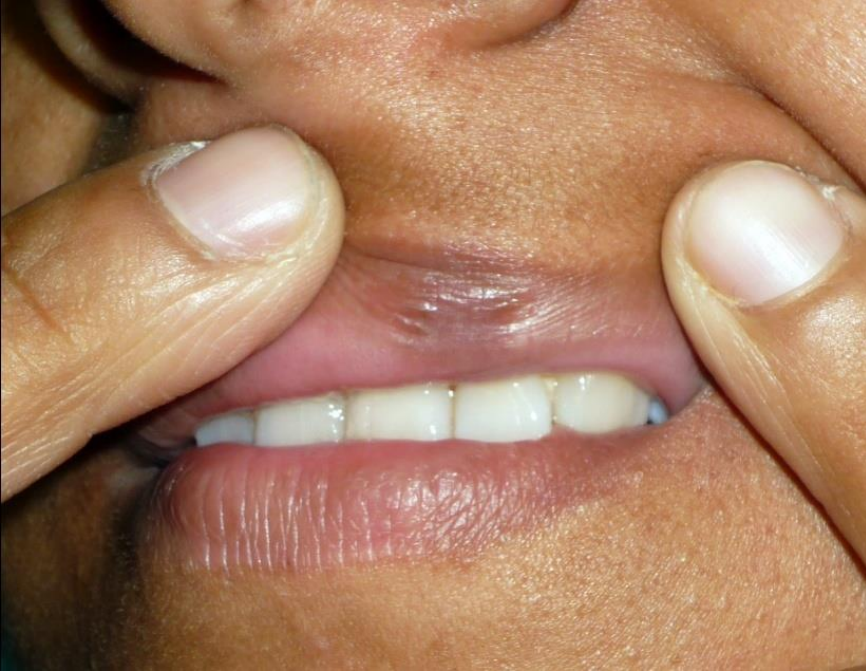Pobre en células

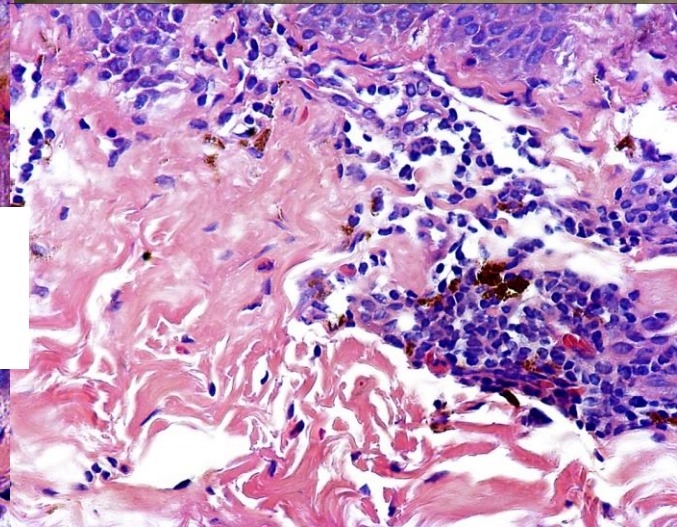
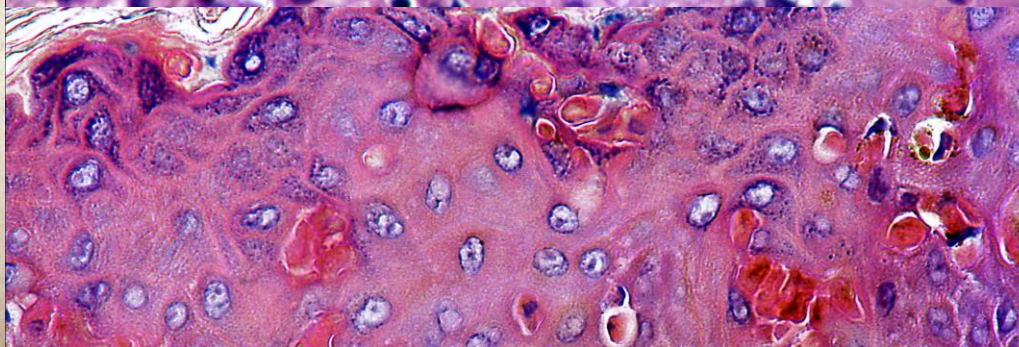
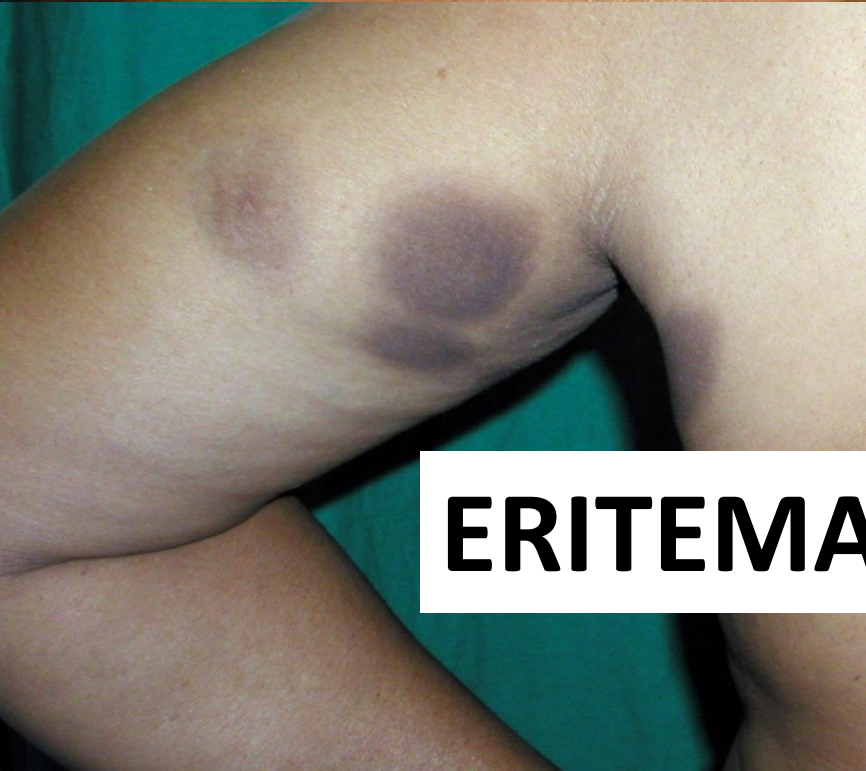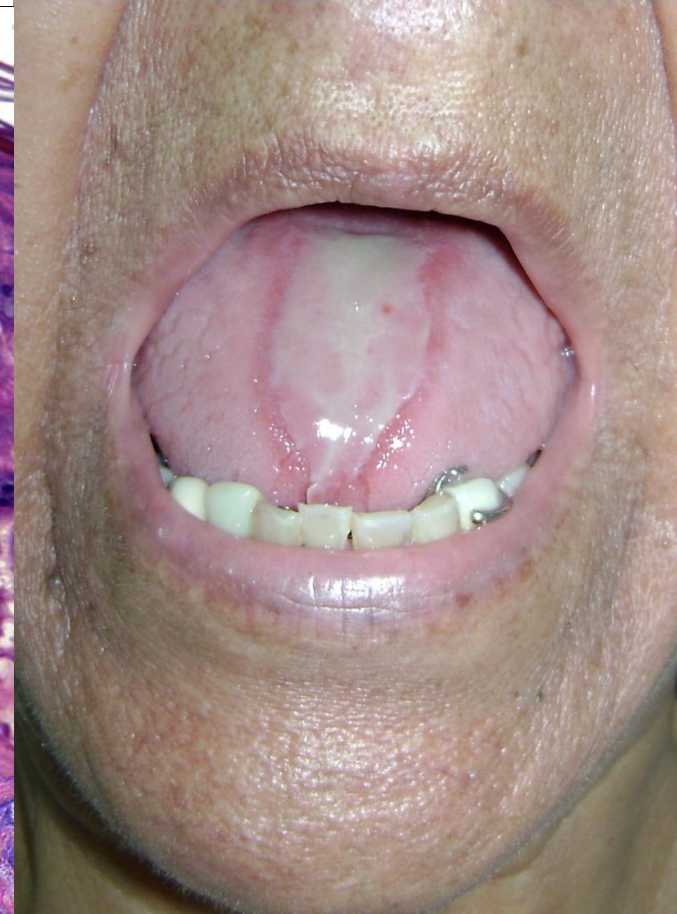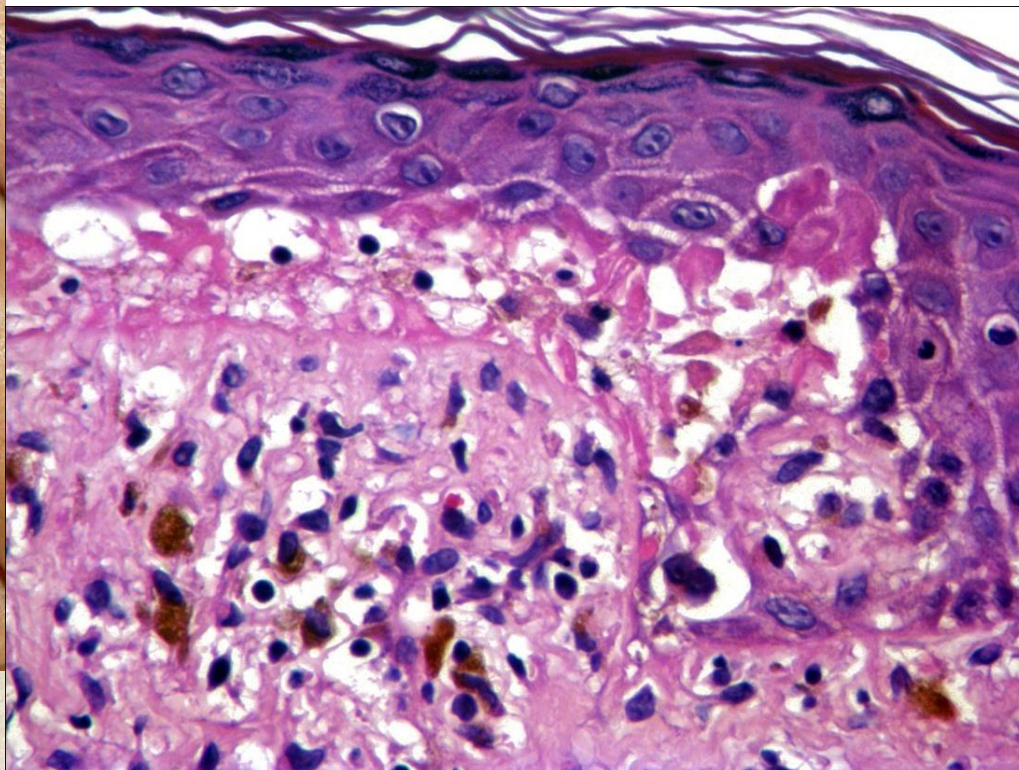
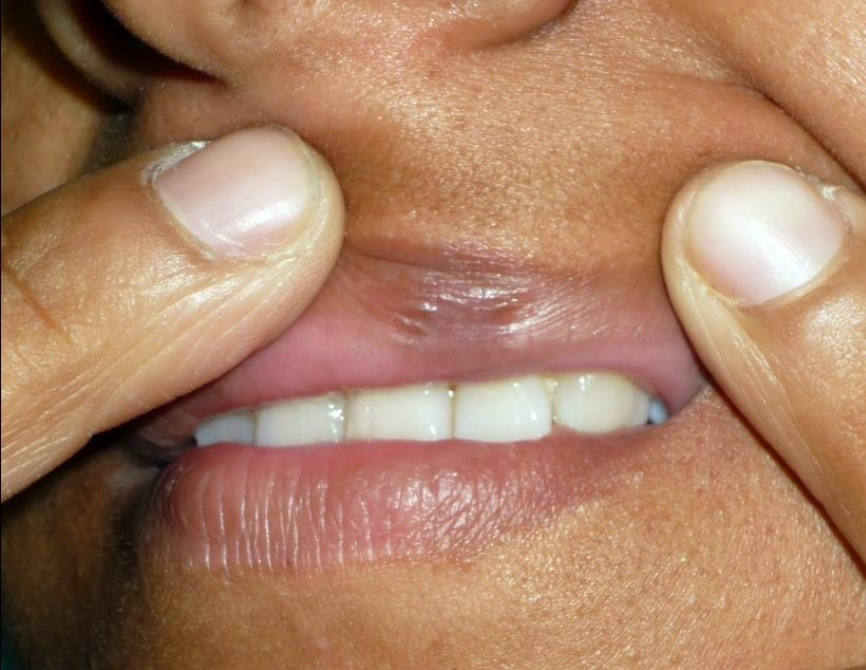Eritema multiforme
Enfermedad de tejido conectivo
LES
Dermatomiositis
EMTC
Enfermedad de injerto contra huésped
Exantema viral morbiliforme
Reacción medicamentosa morbiliforme

Rico en células

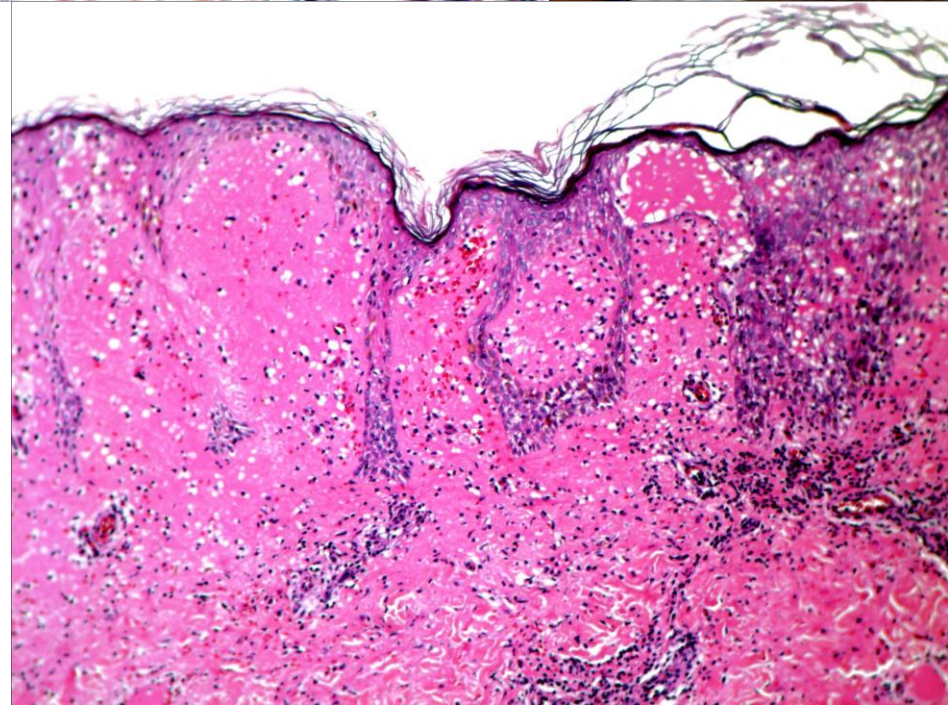
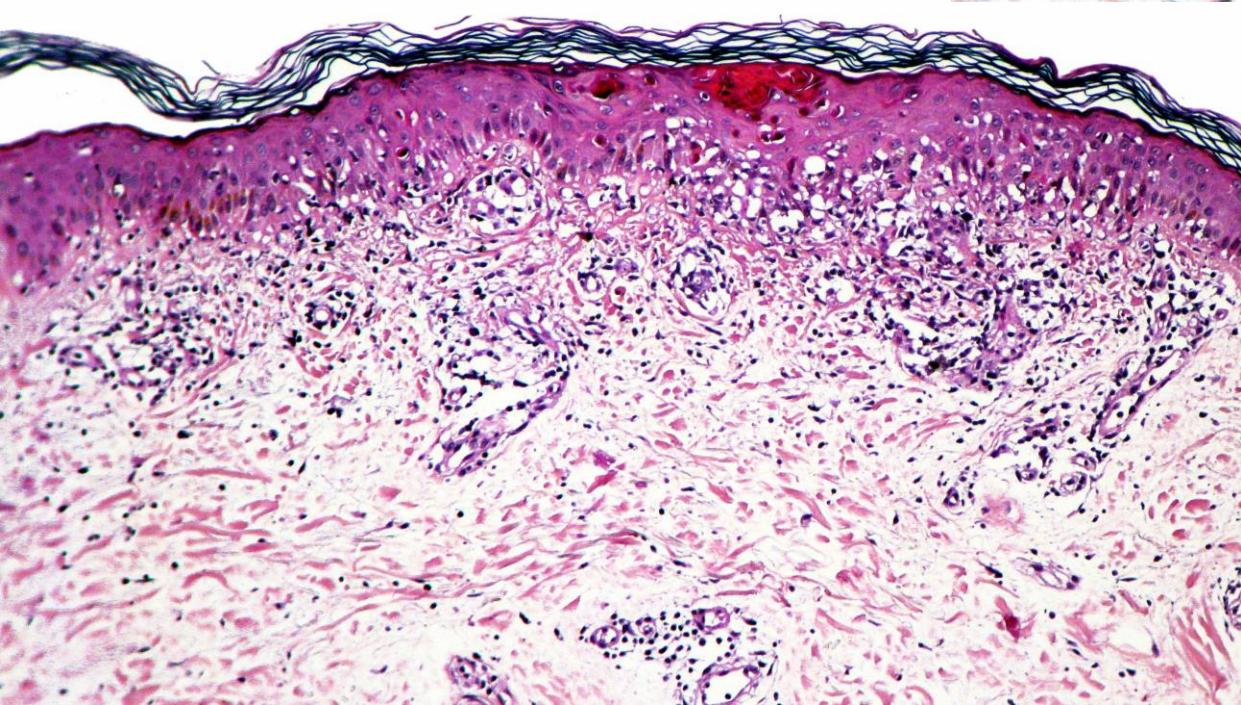
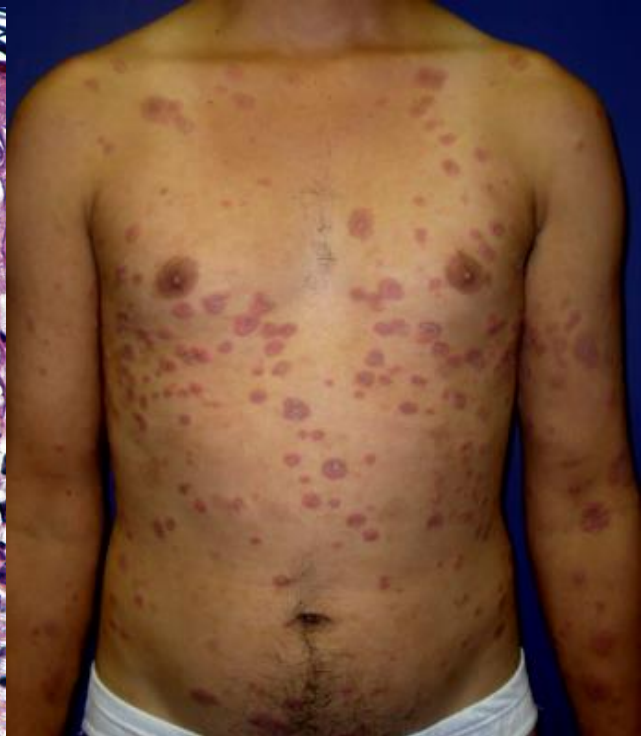
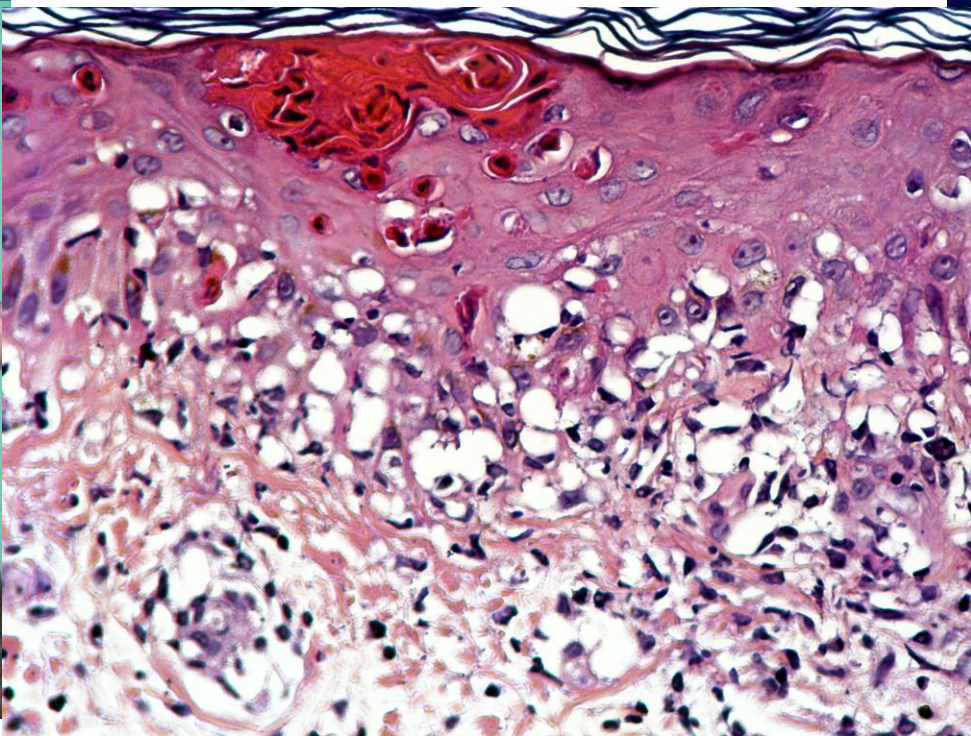
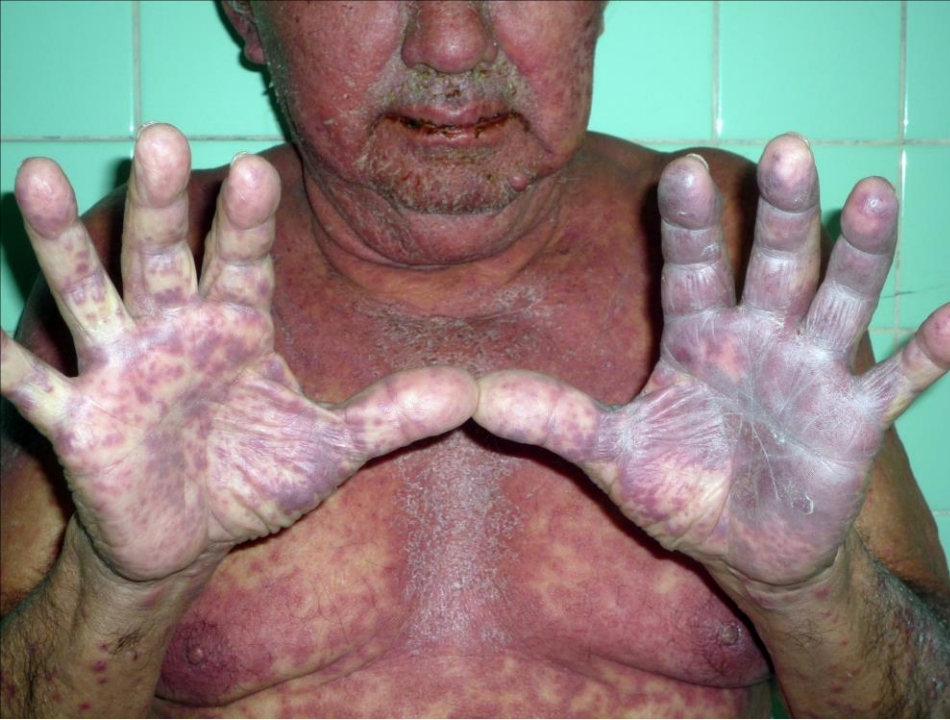Desórdenes liquenoides
idiopáticos
Liquen plano
Liquen estriado
Liquen Nítido
Enfermedad de tejido
conectivo
Lupus Discoide
LES anti RO
EMTC
Púrpura liquenoide
Reacción liquenoide a drogas
y Eritema pigmentado fijo

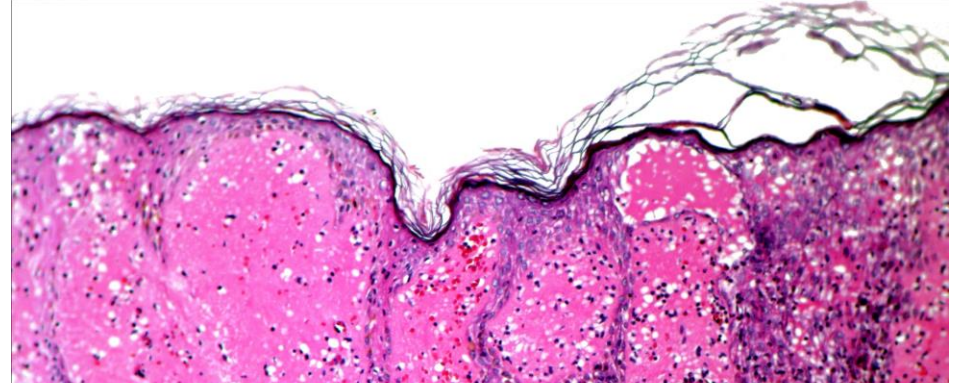
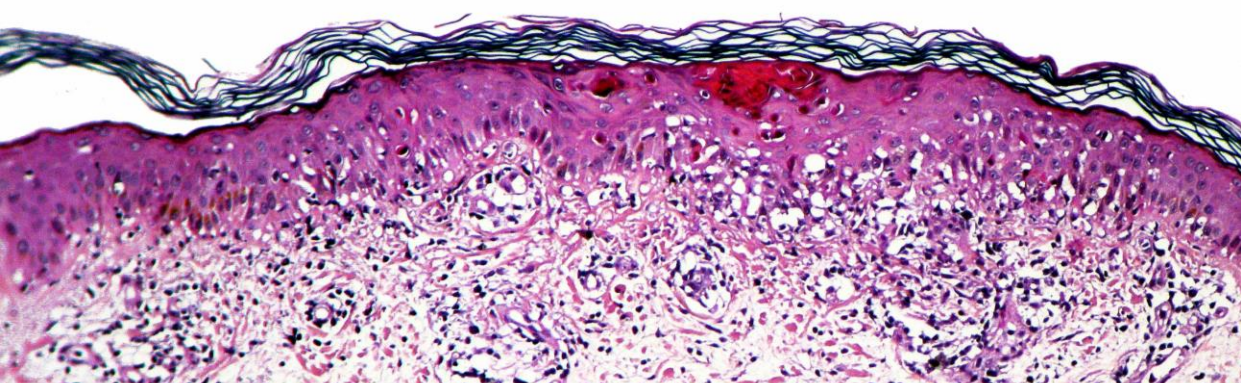
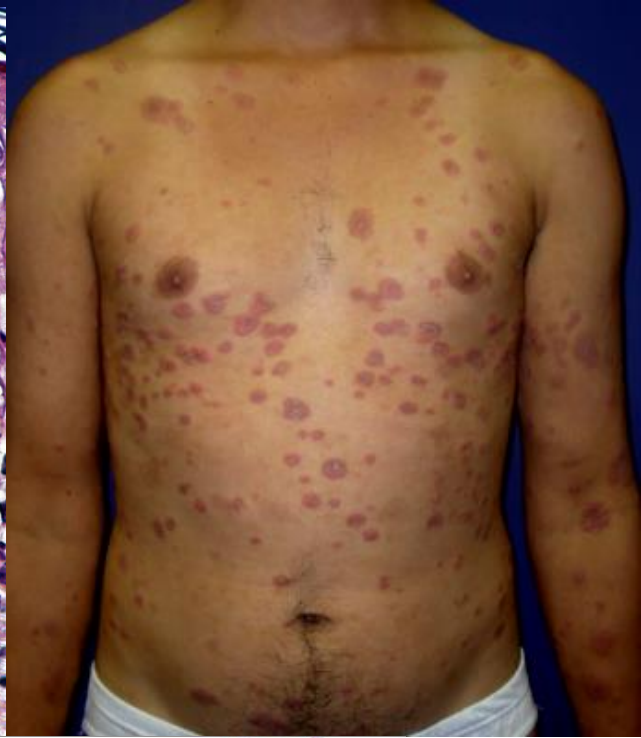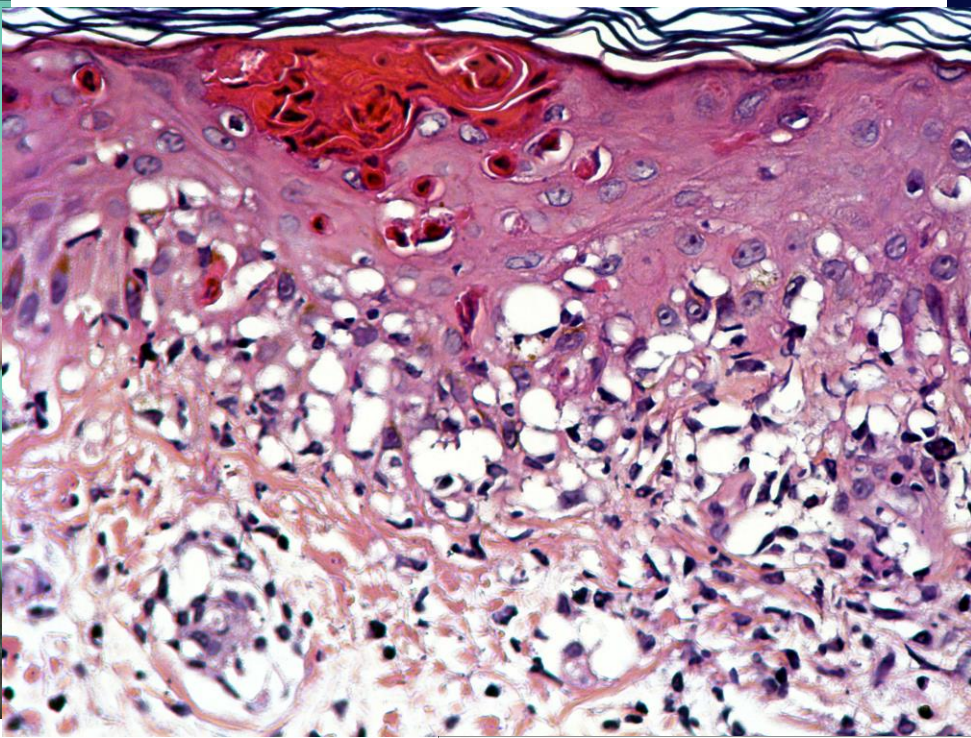




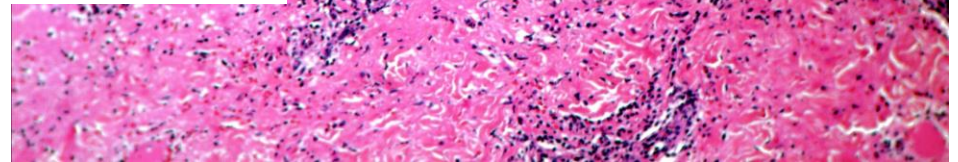
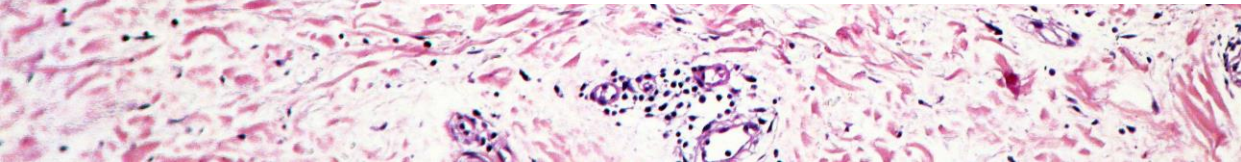


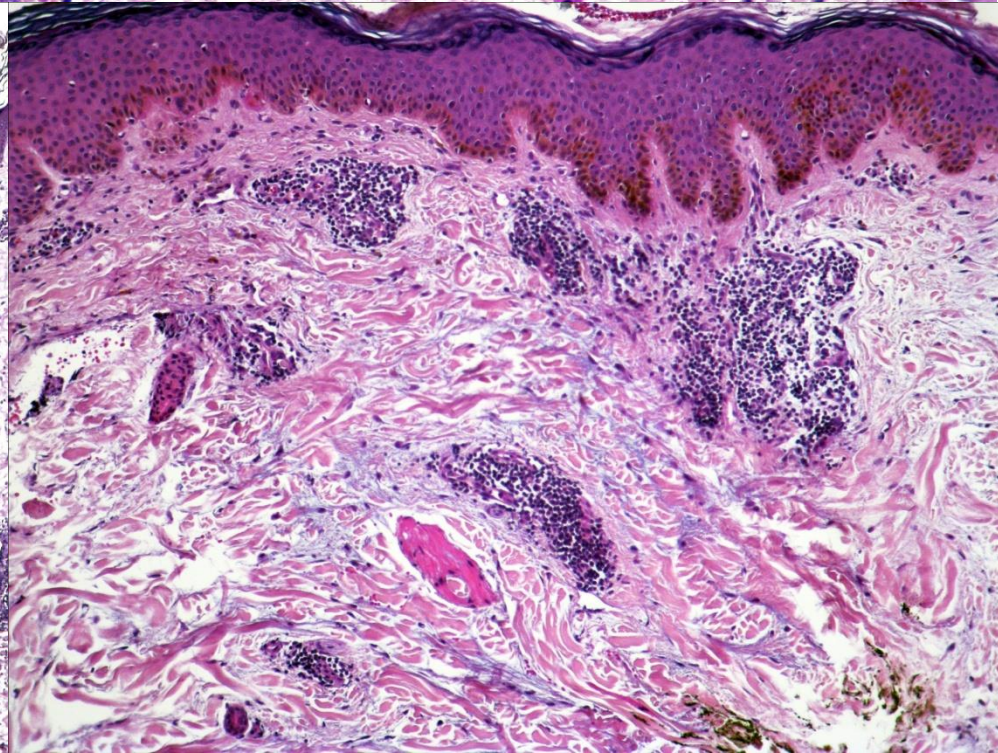
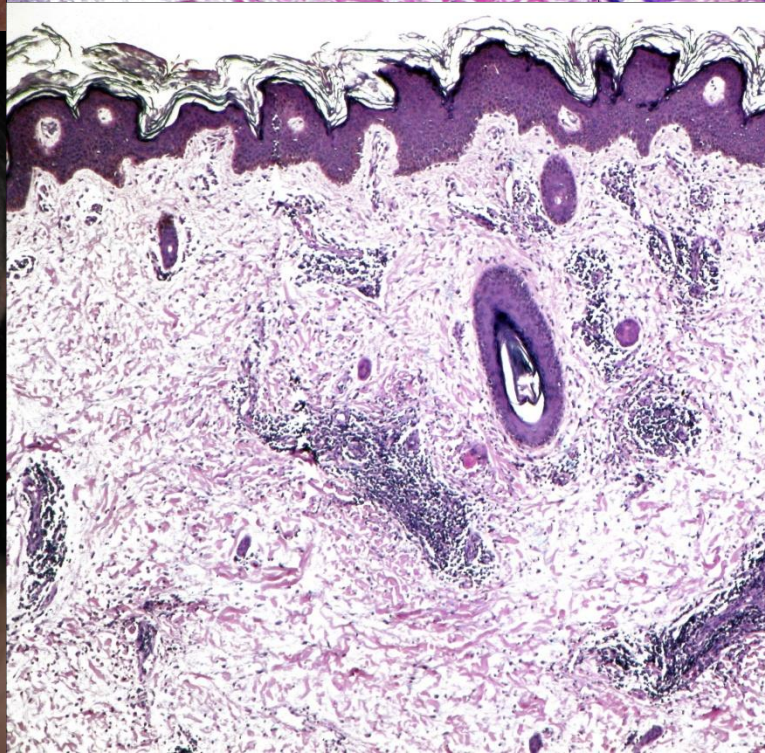
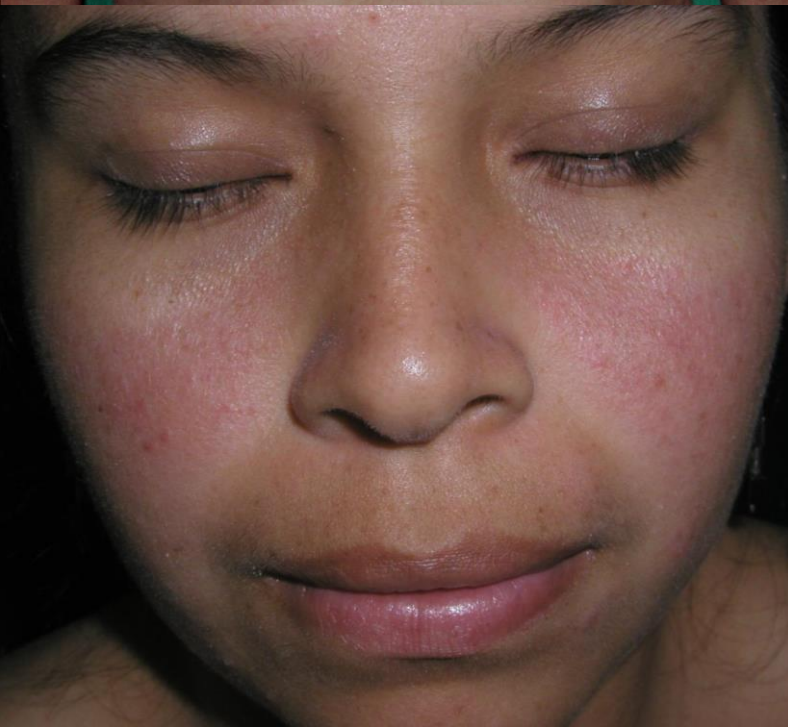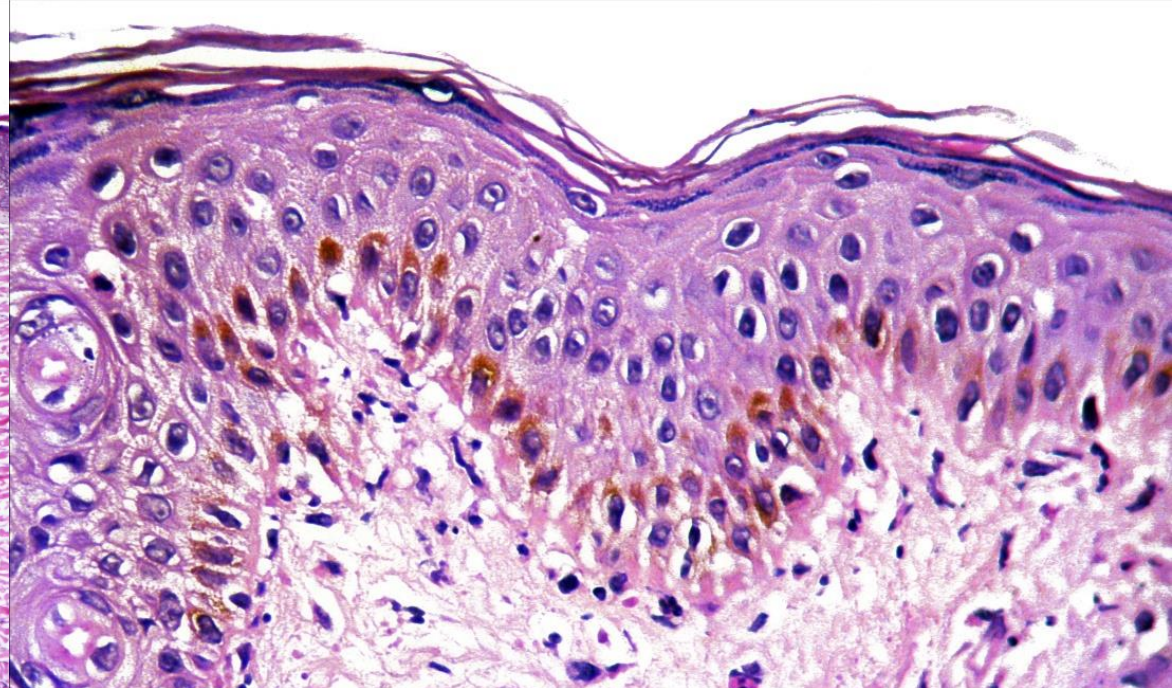
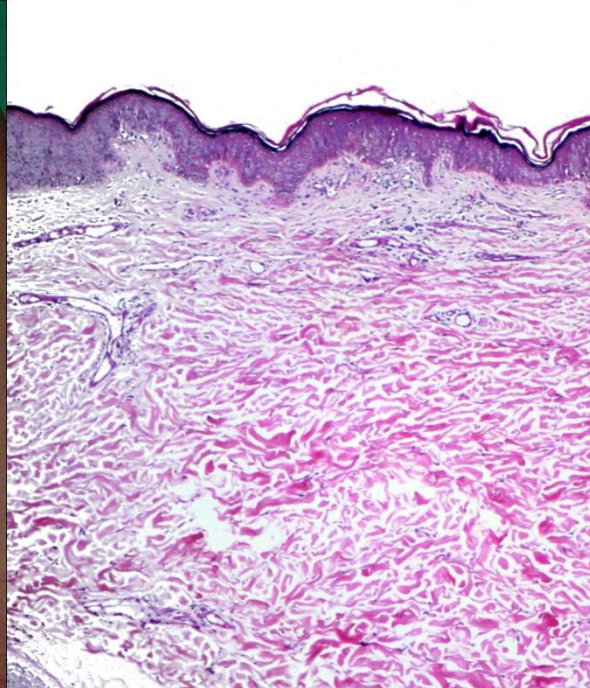
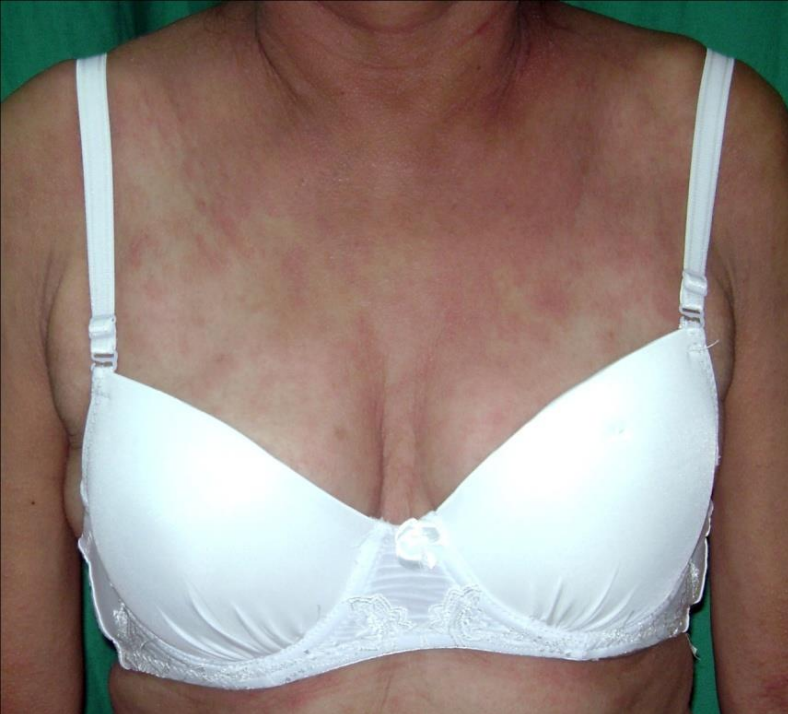ERITEMA PIGMENTADO FIJO

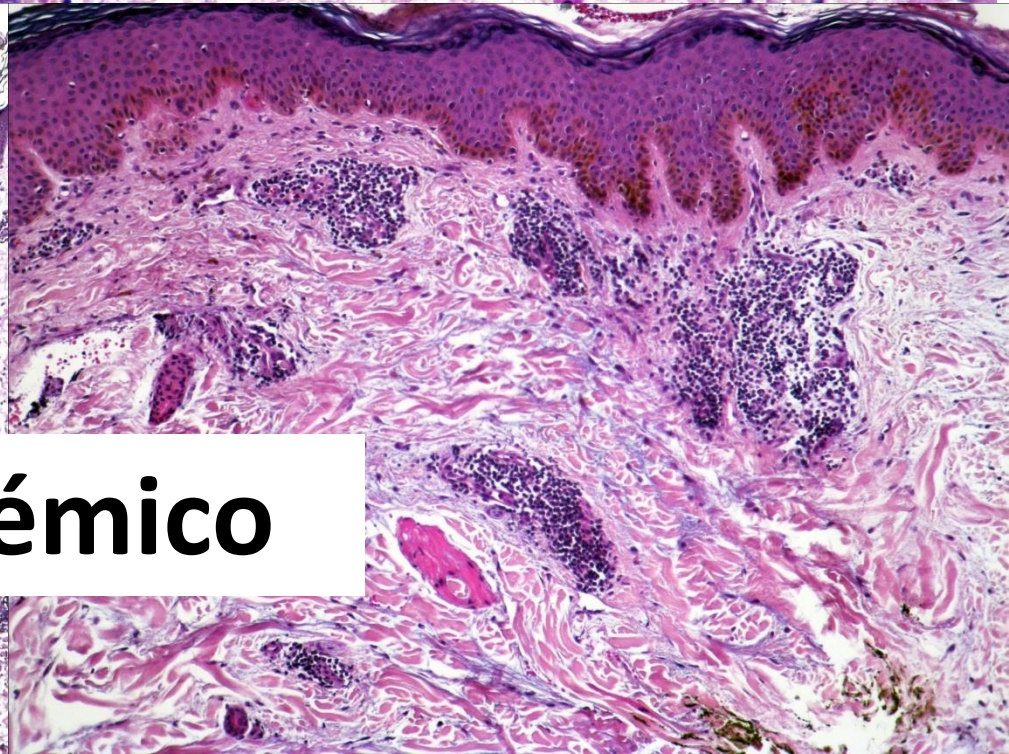
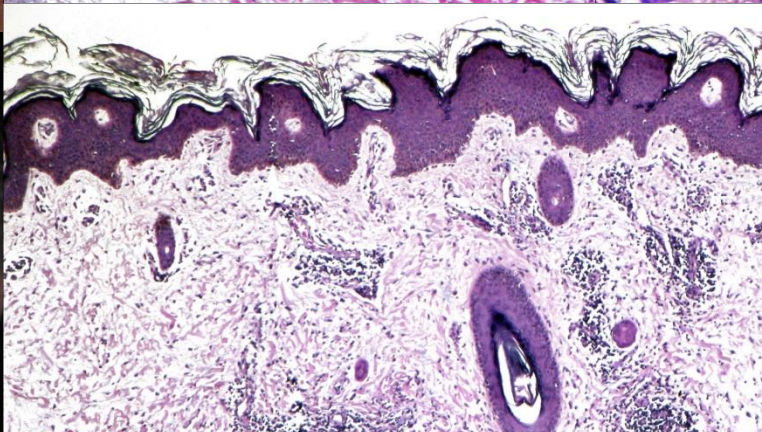
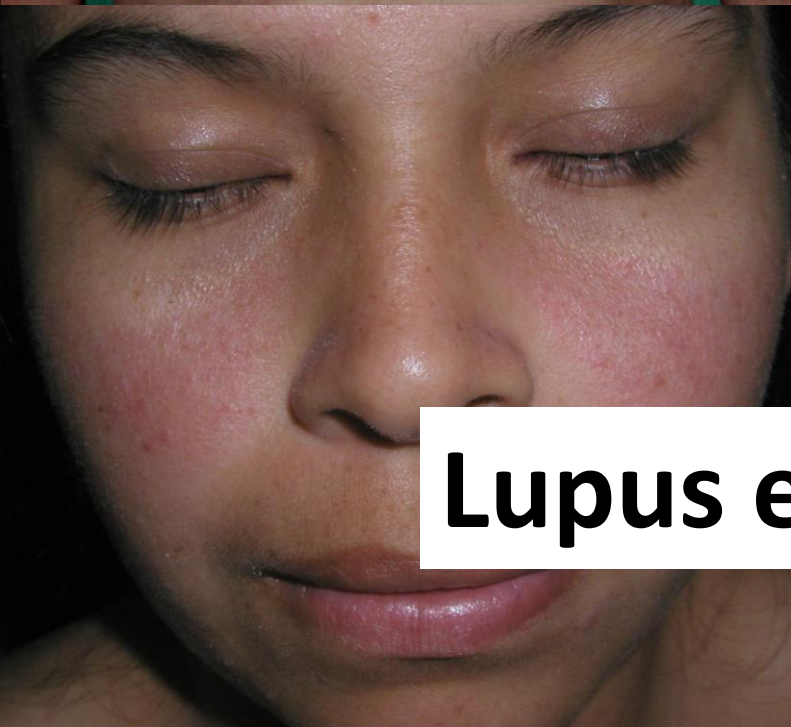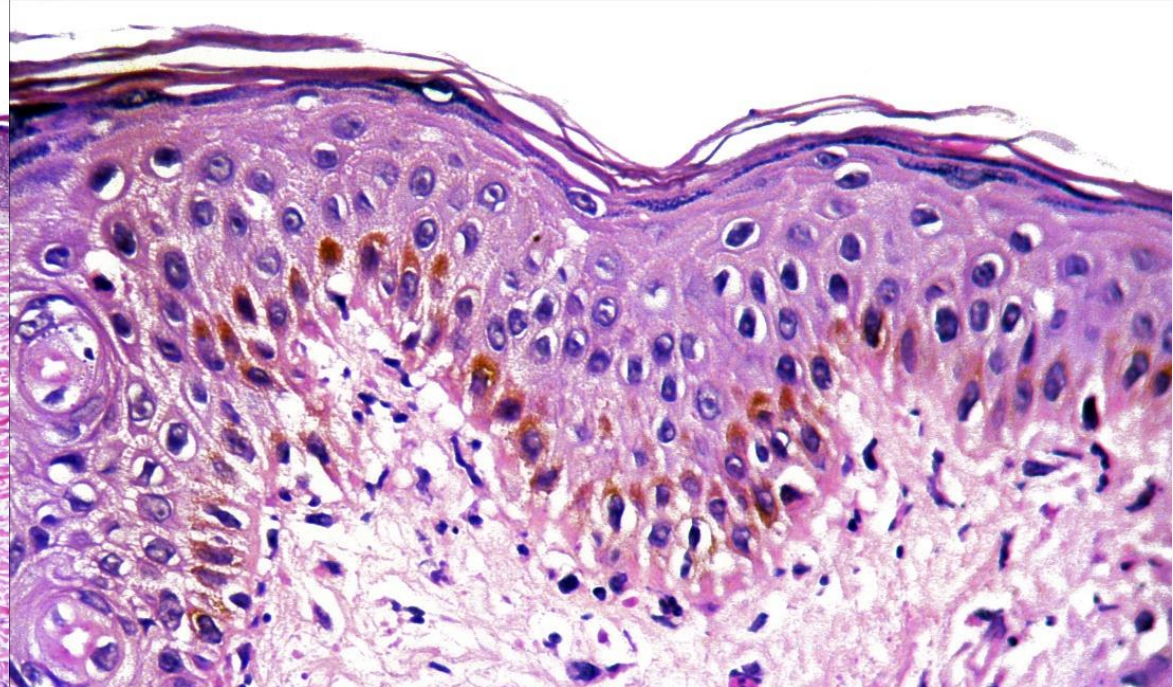
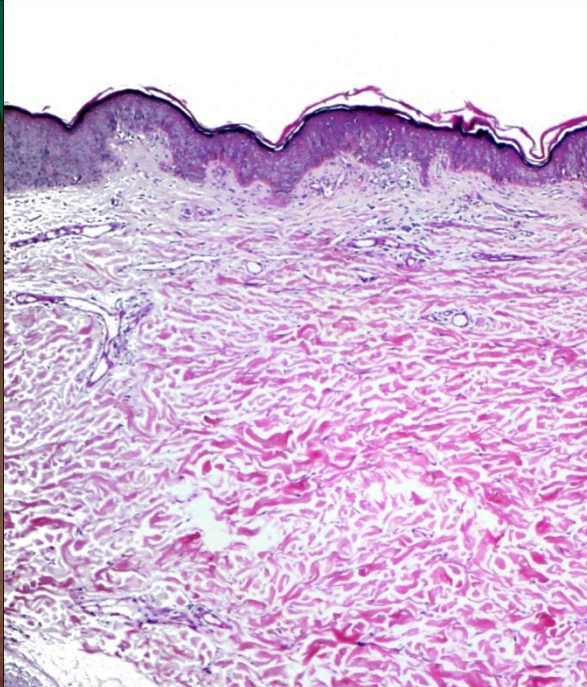

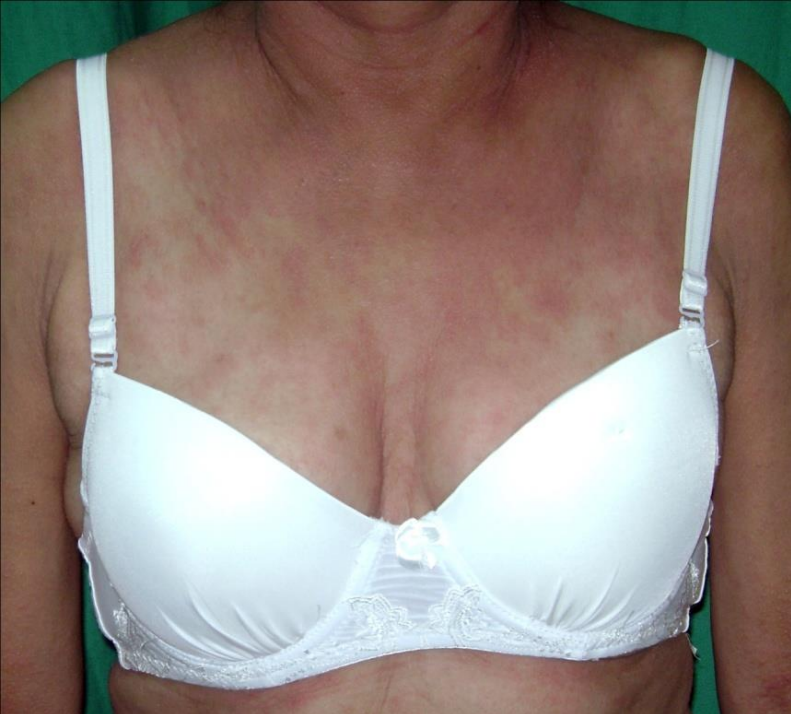


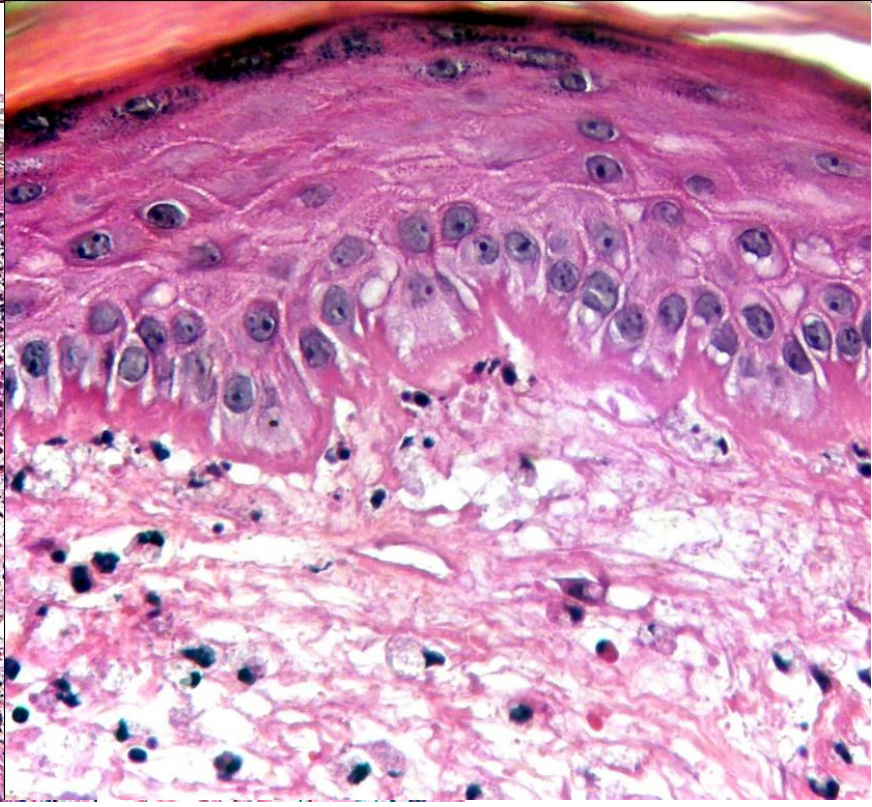
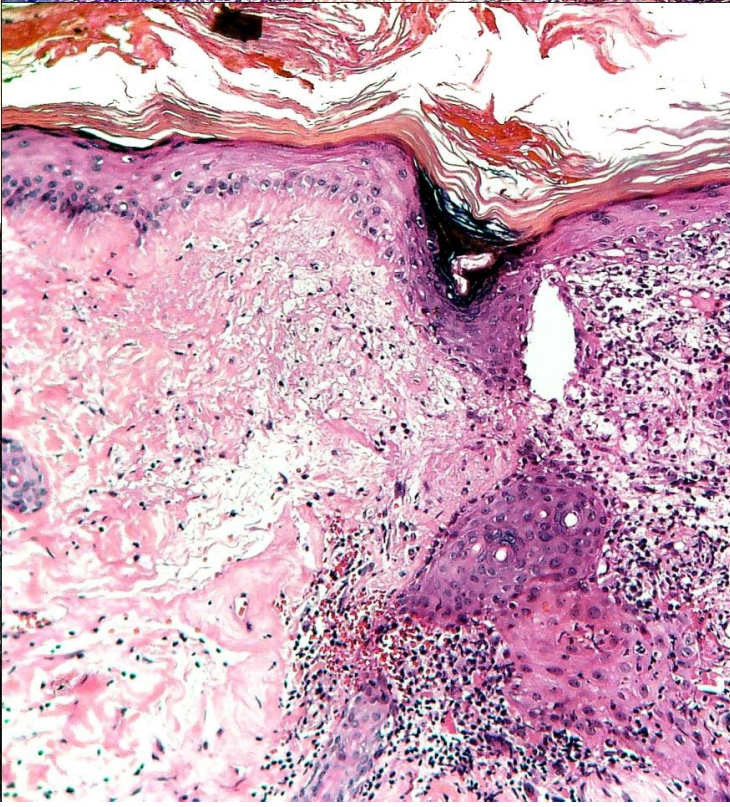
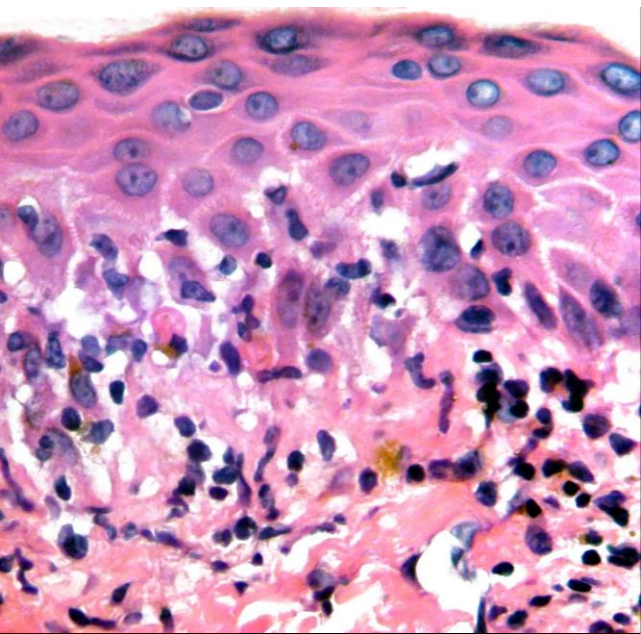
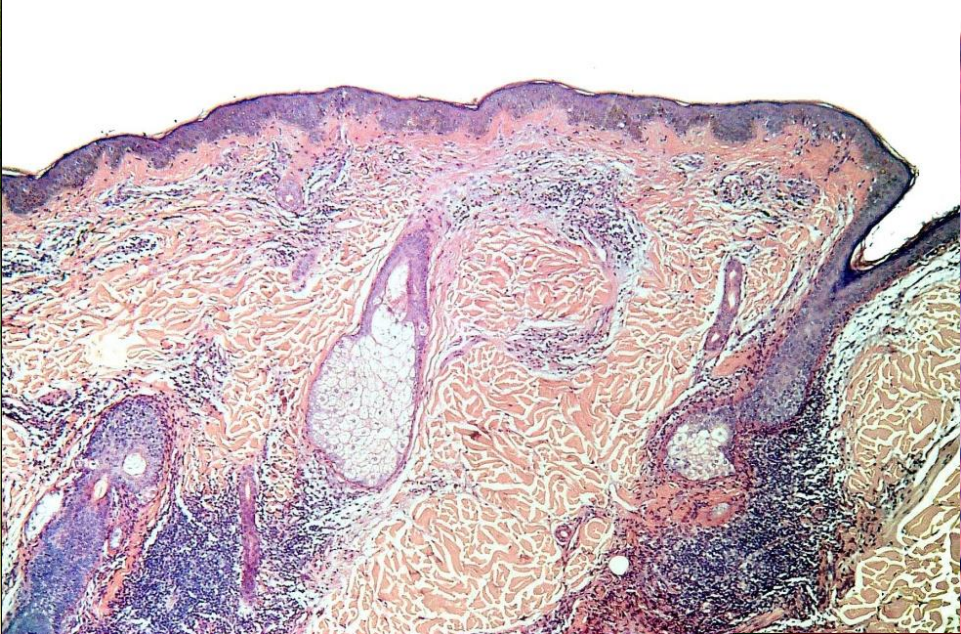
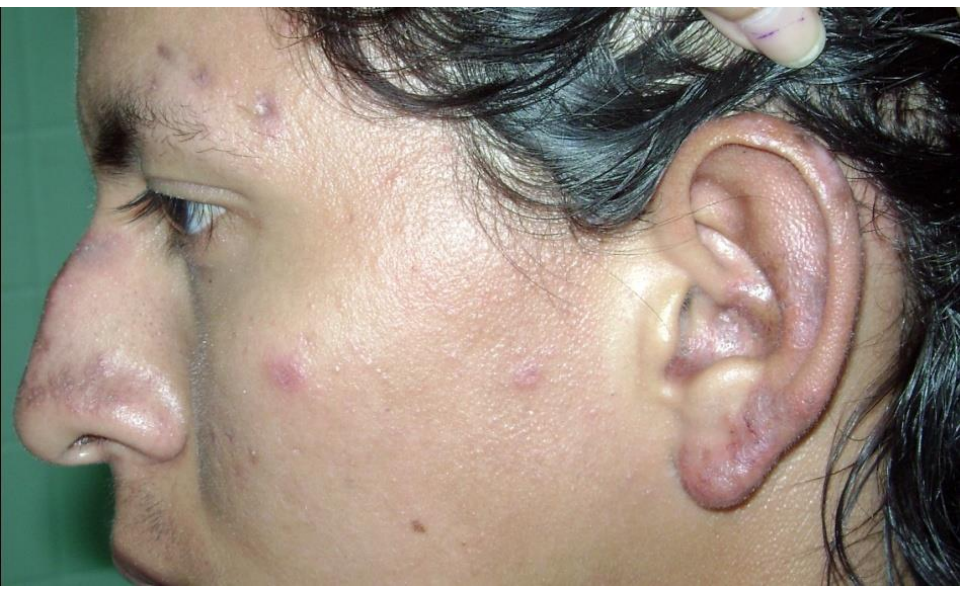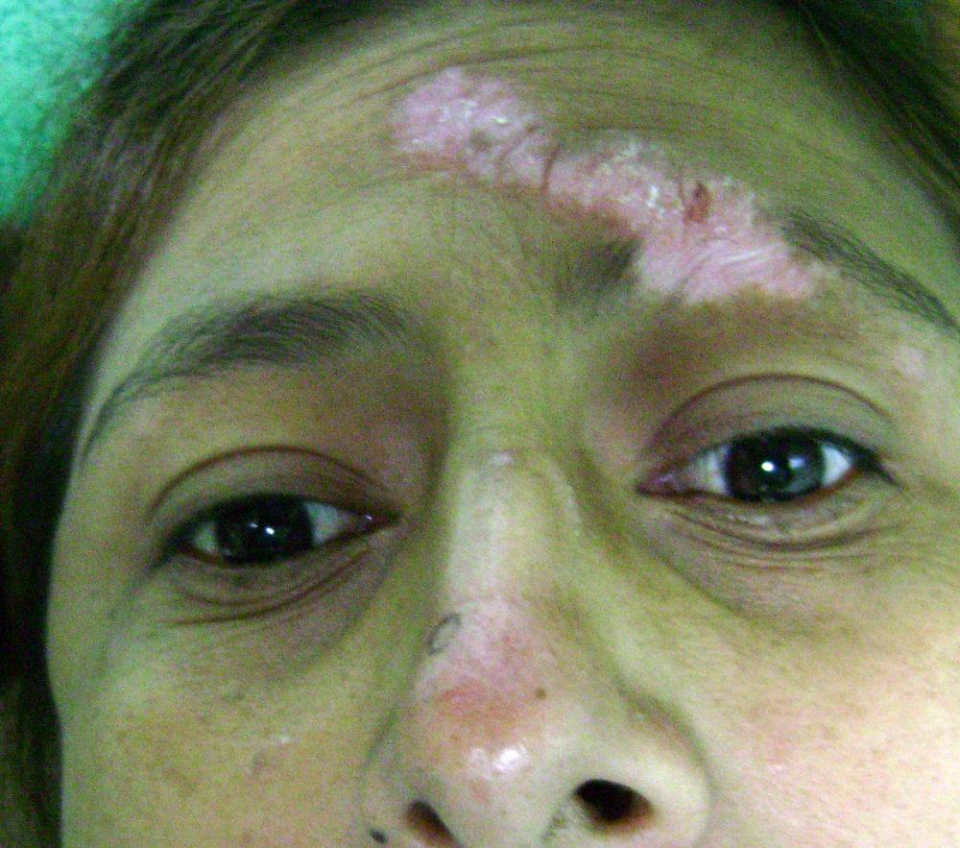ERITEMA MULTIFORME

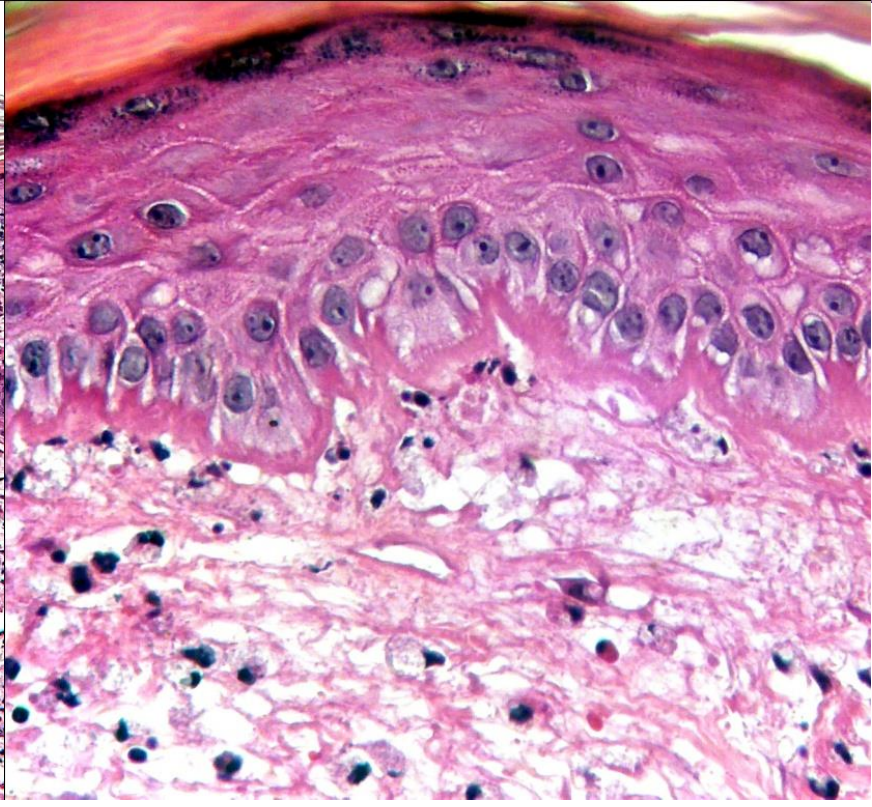
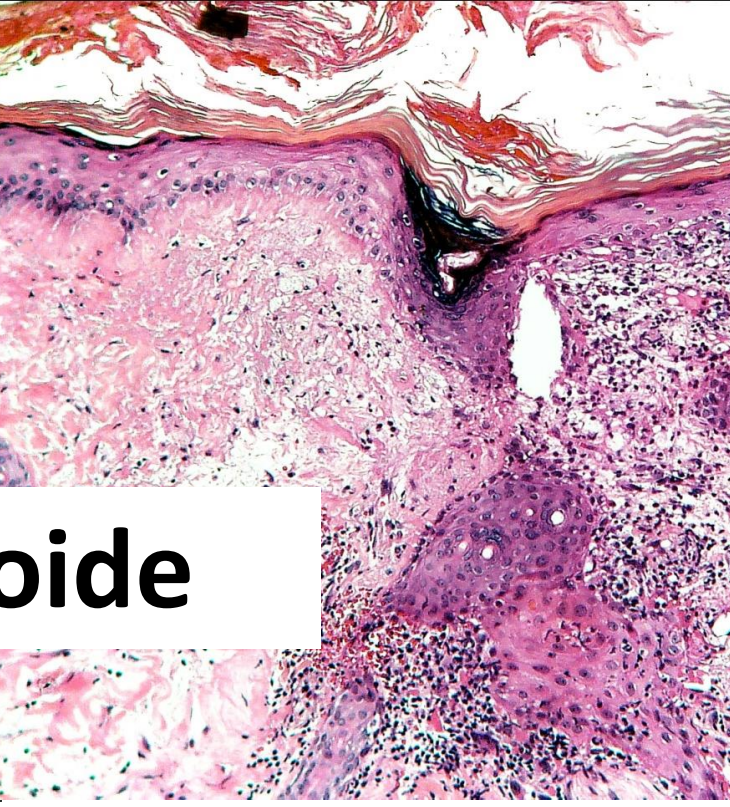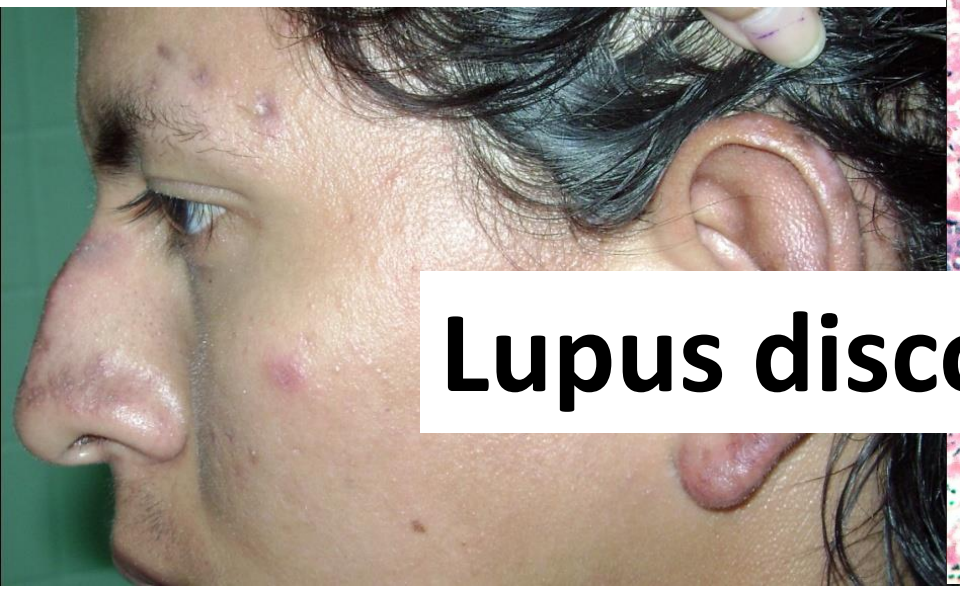
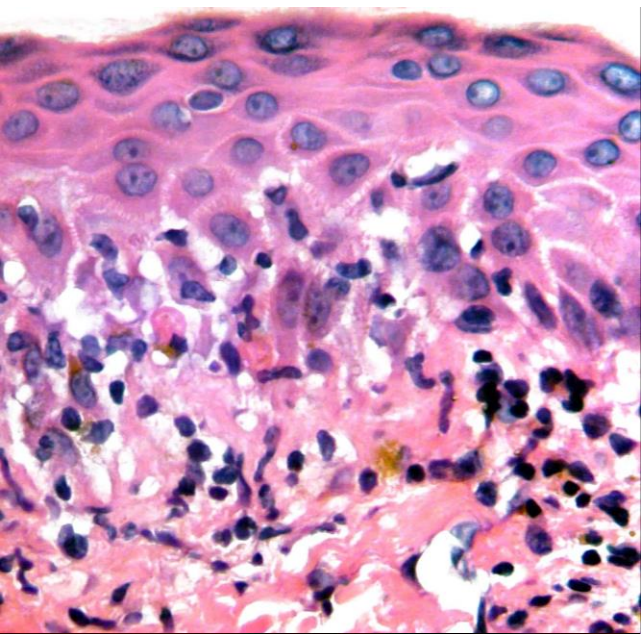
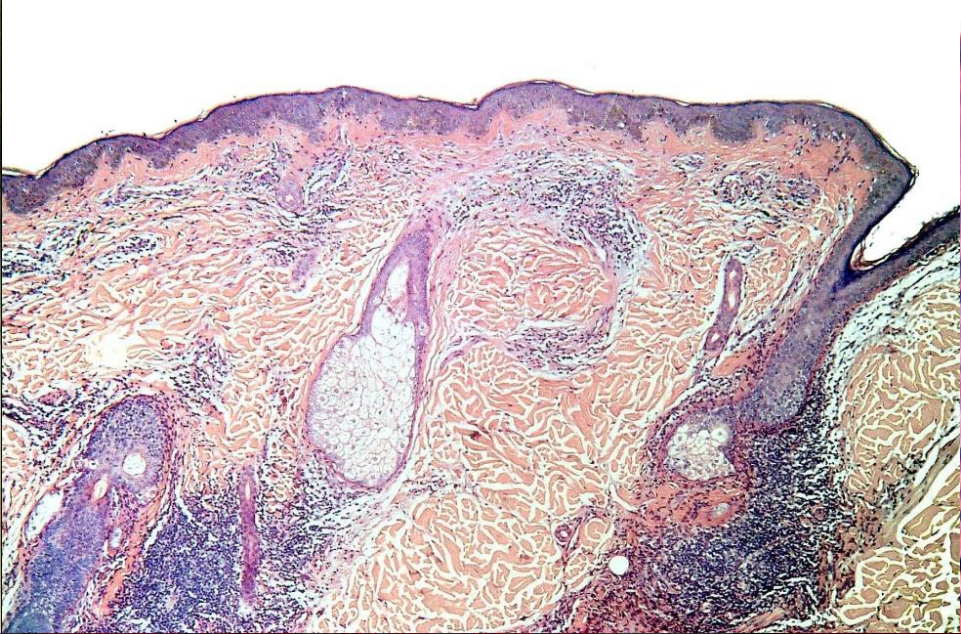

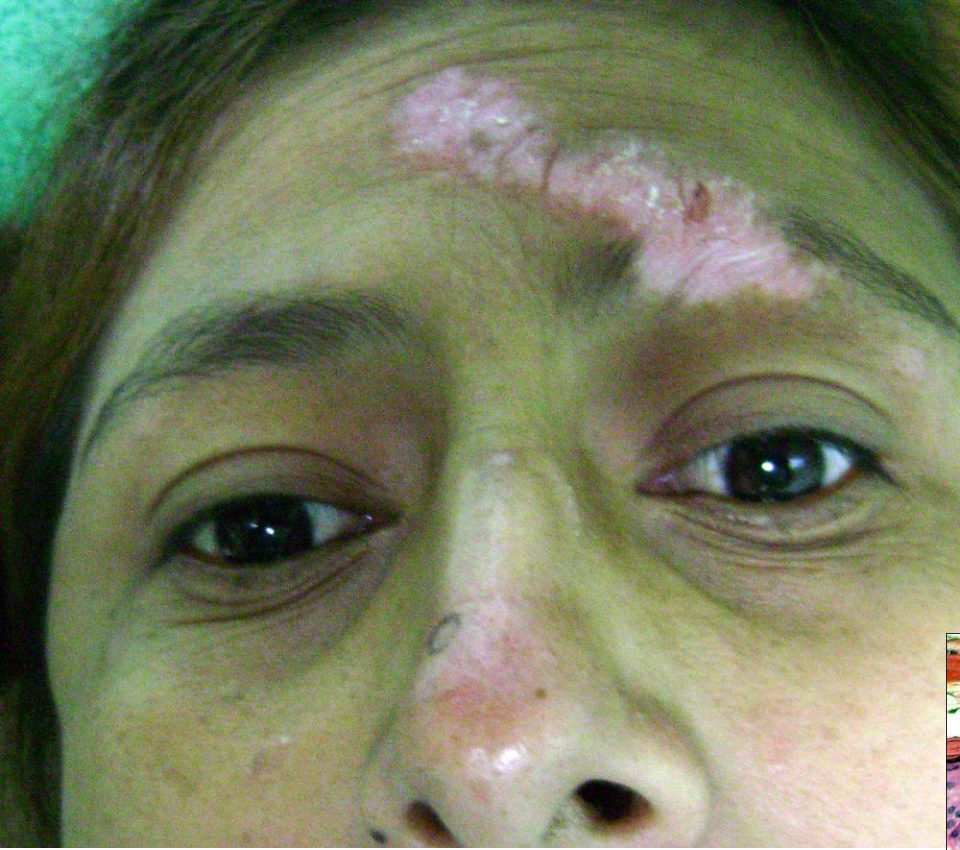


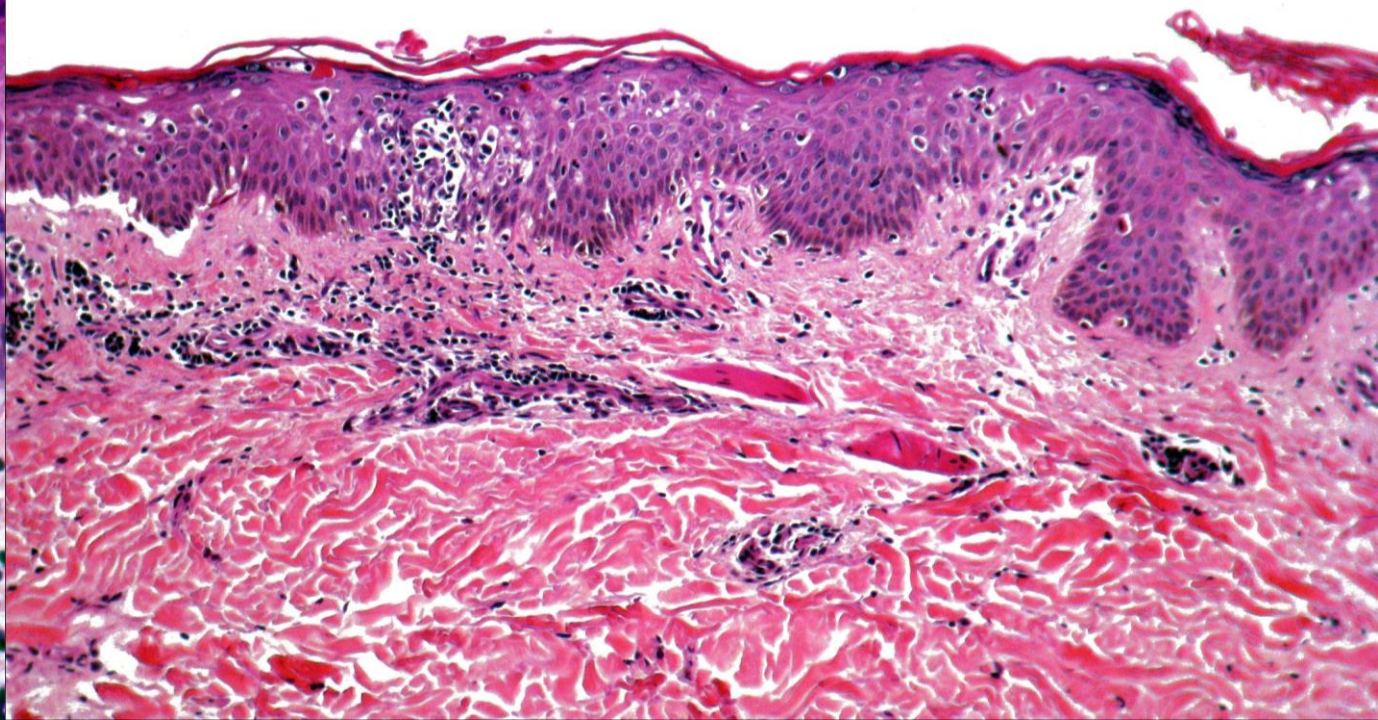
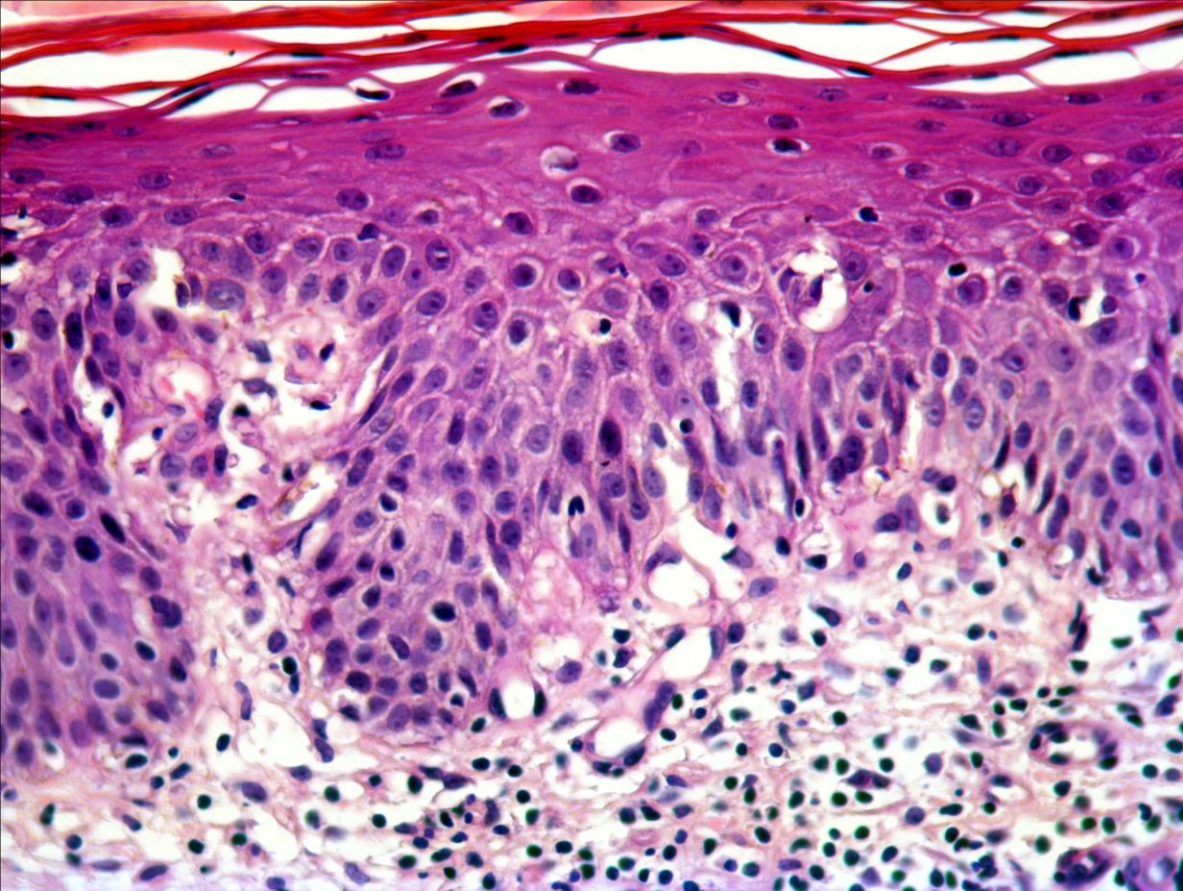
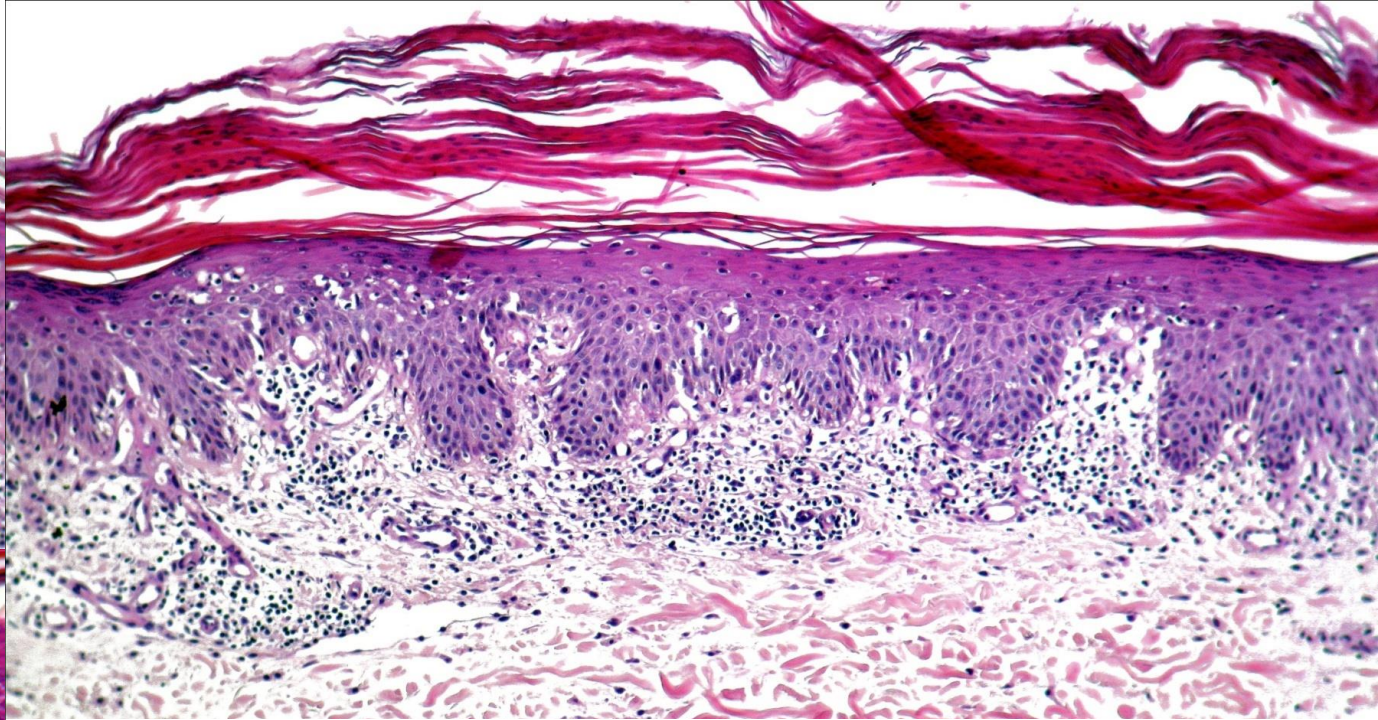
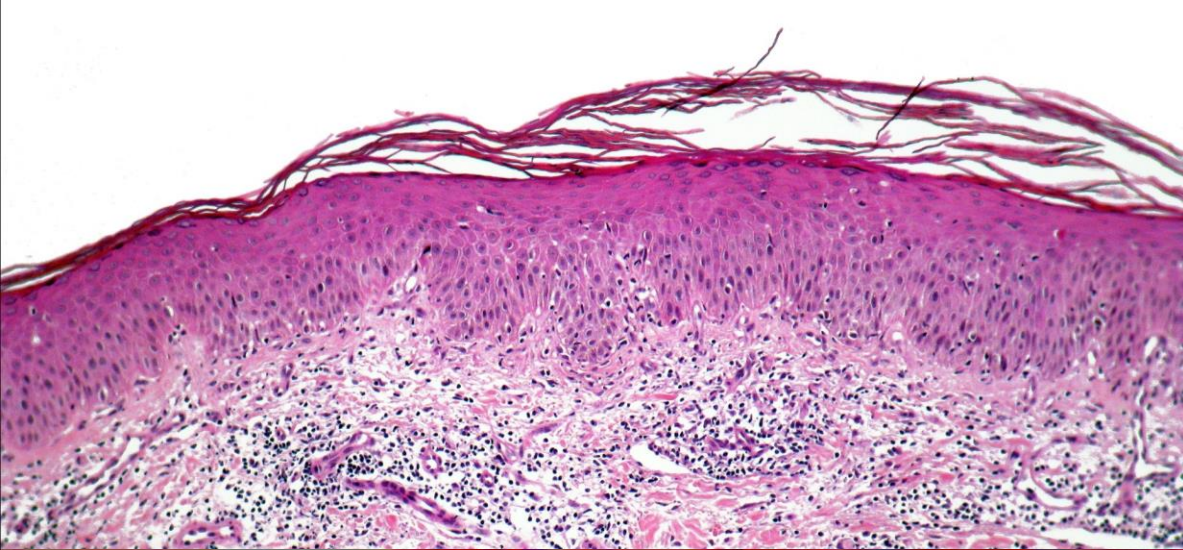


Lupus eritematoso sistémico

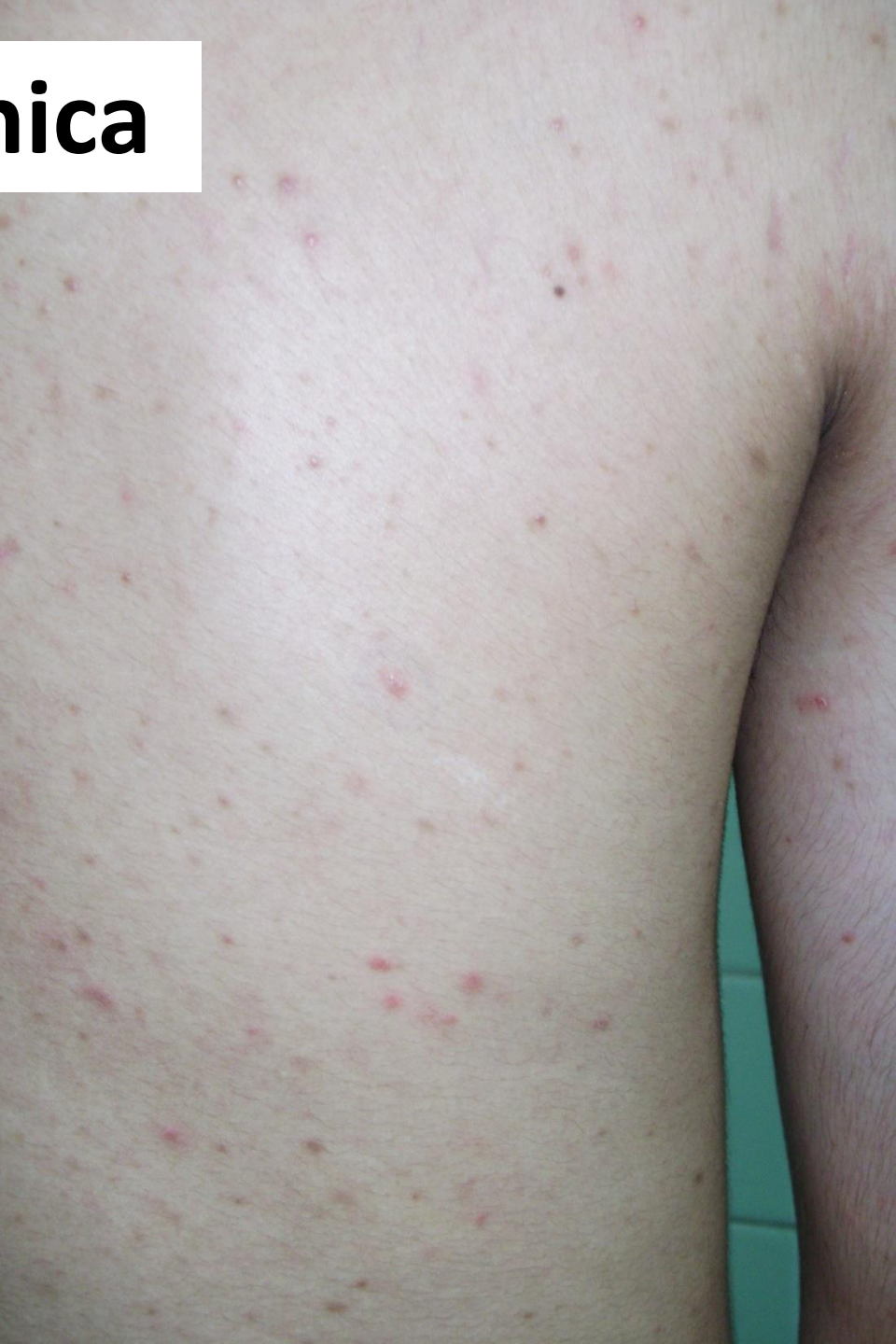
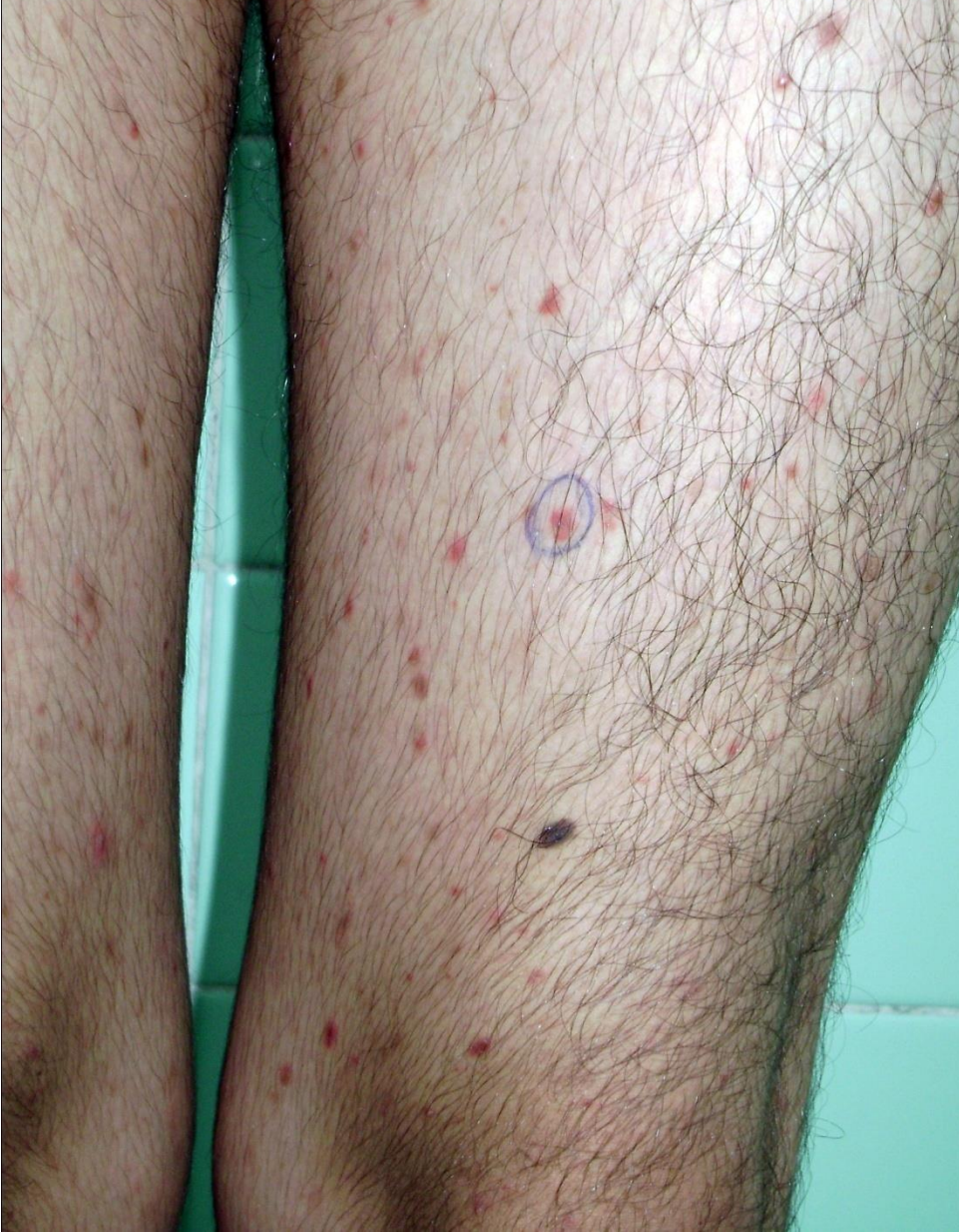



Lupus discoide



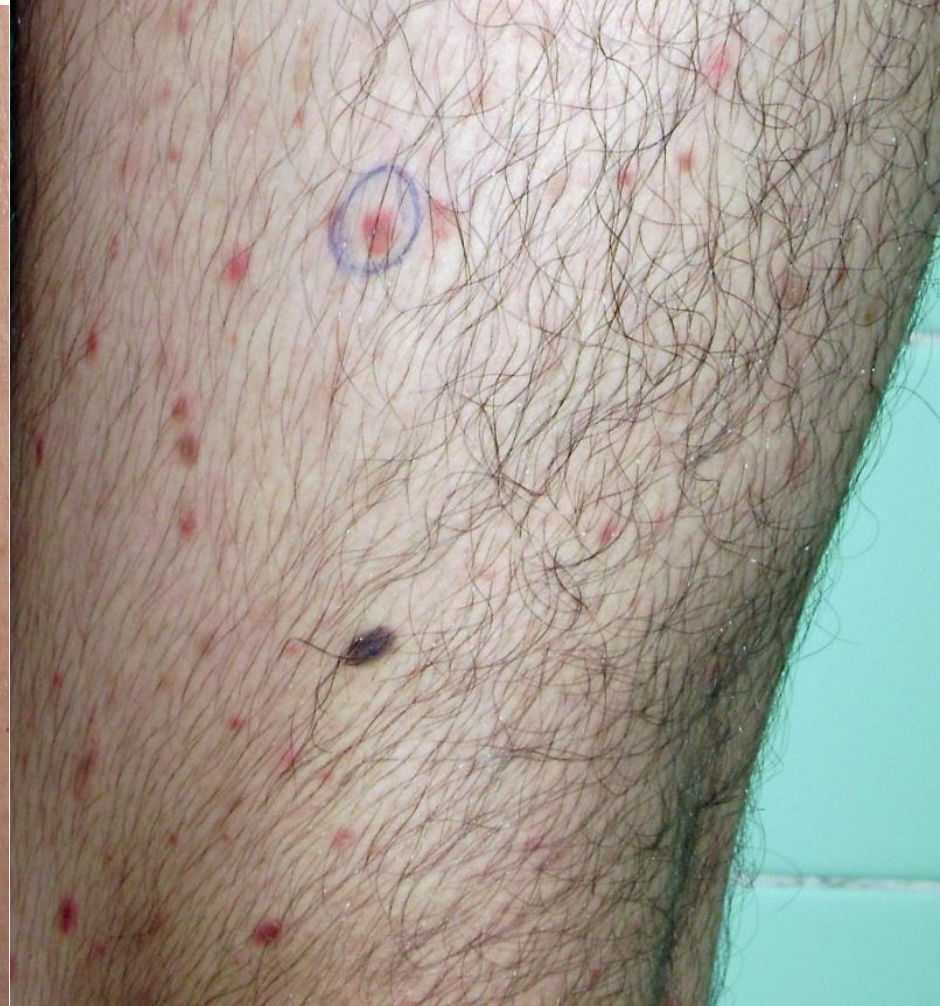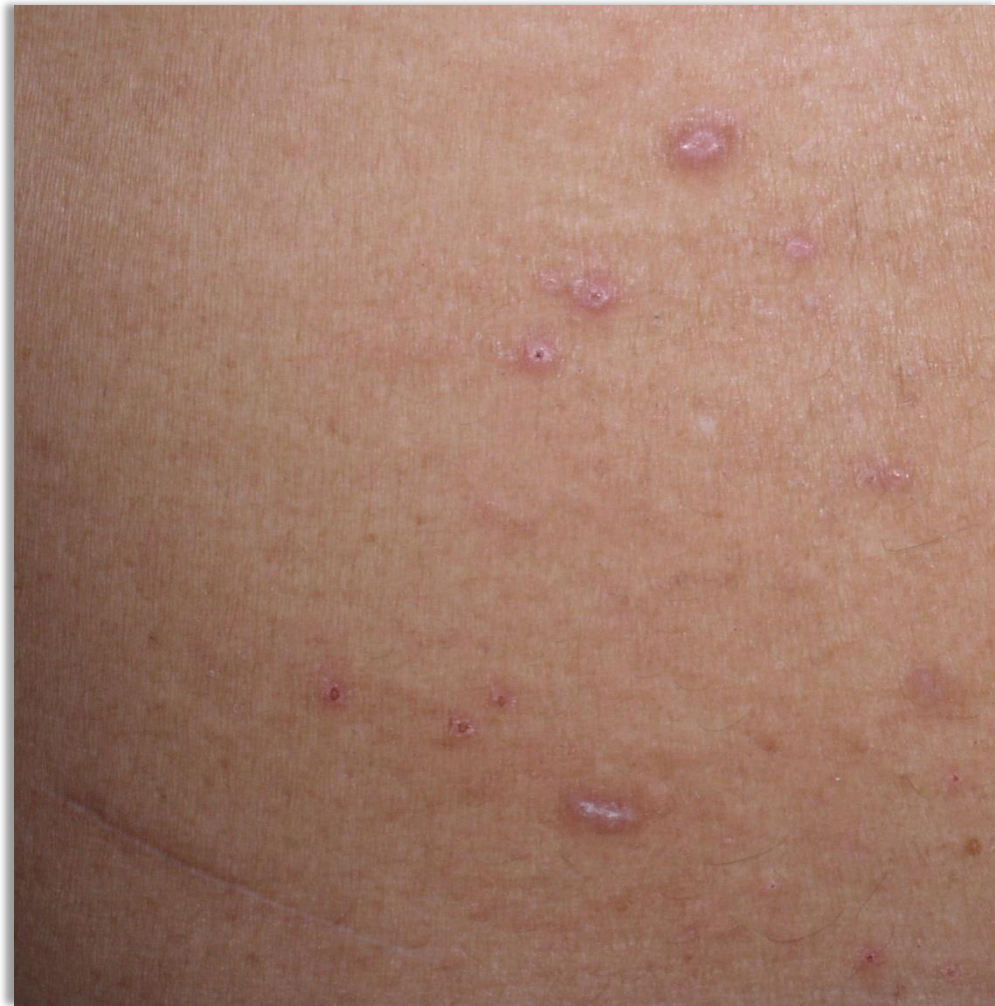Pitiriasis liquenoide crónica

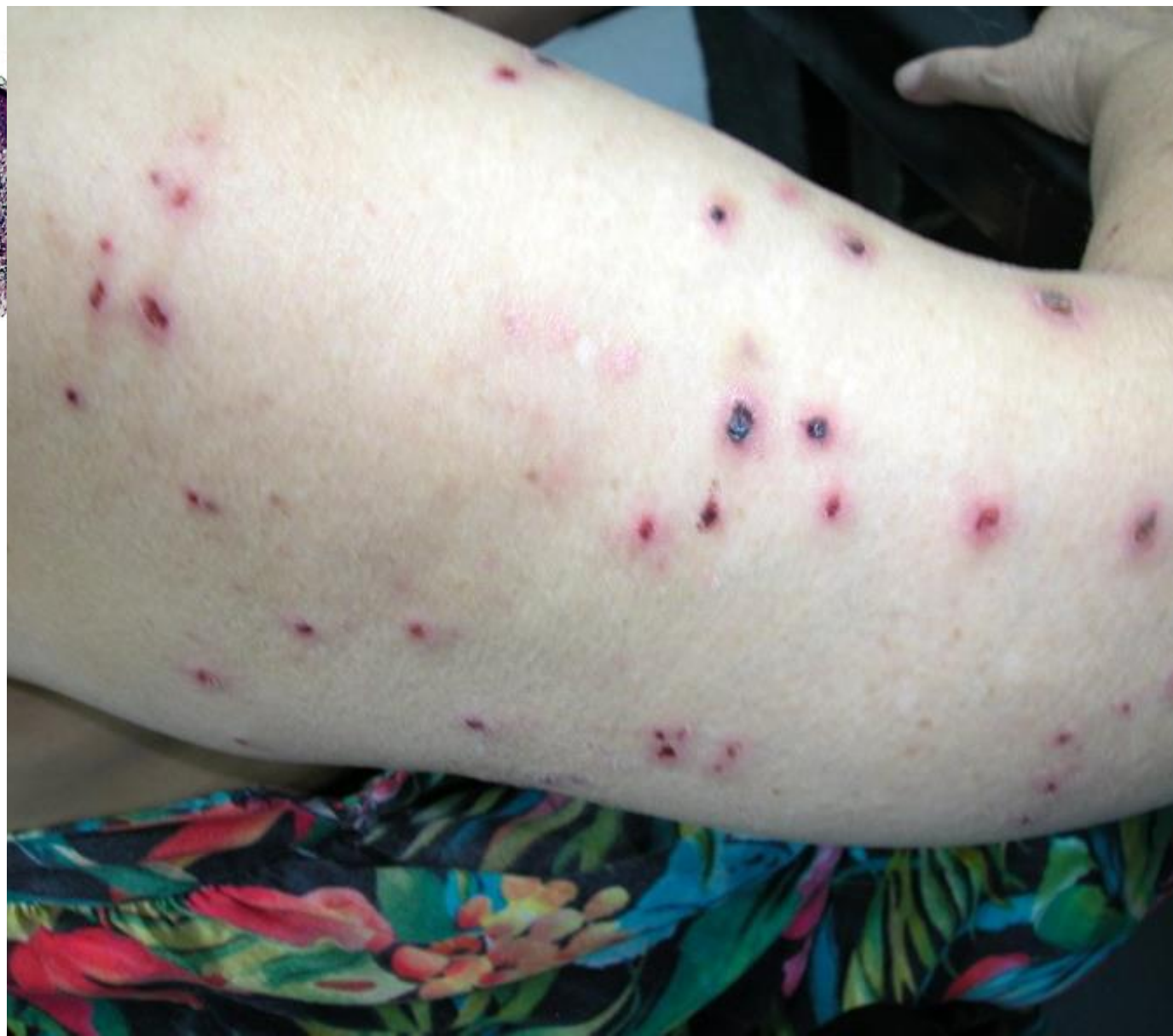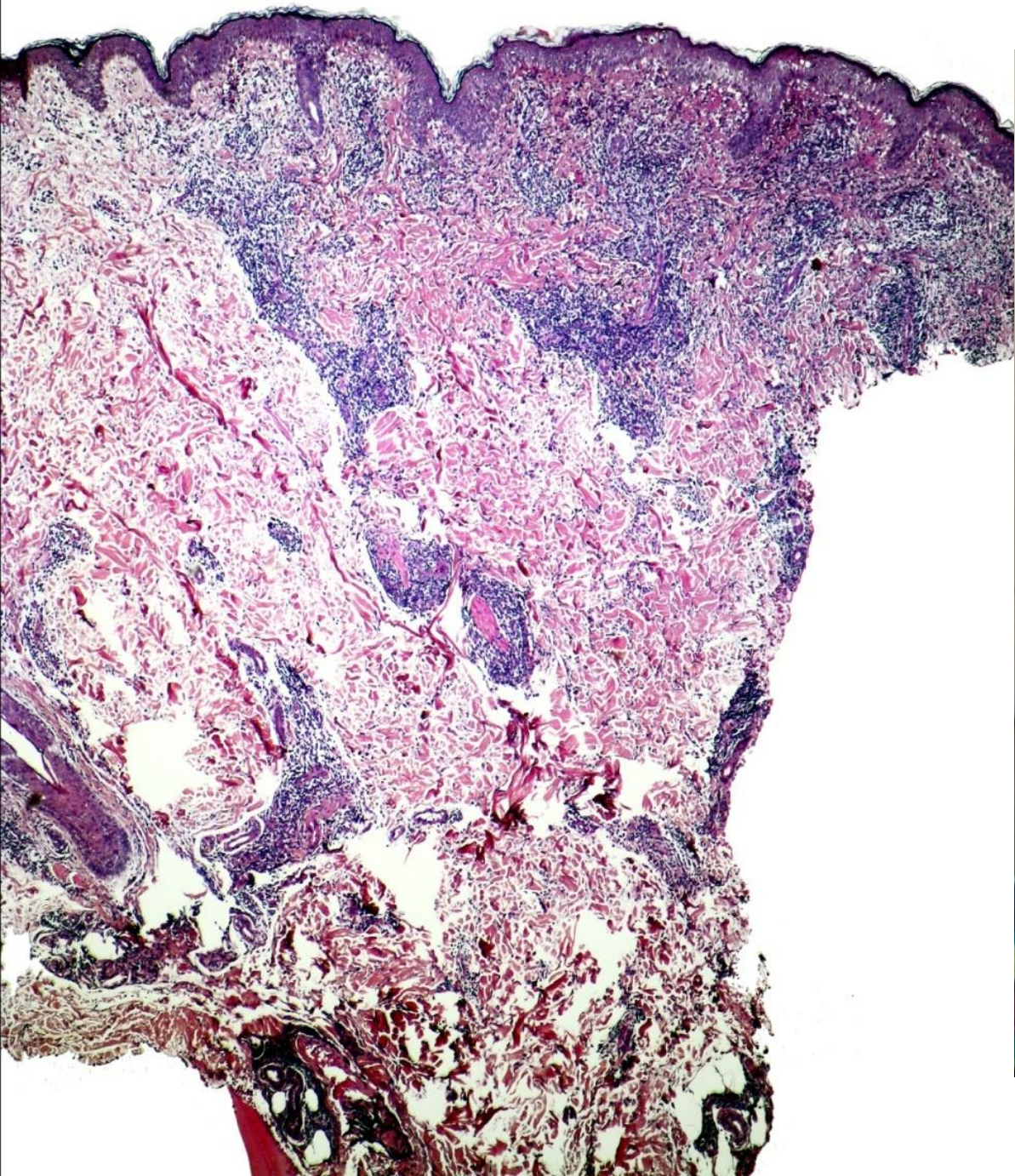


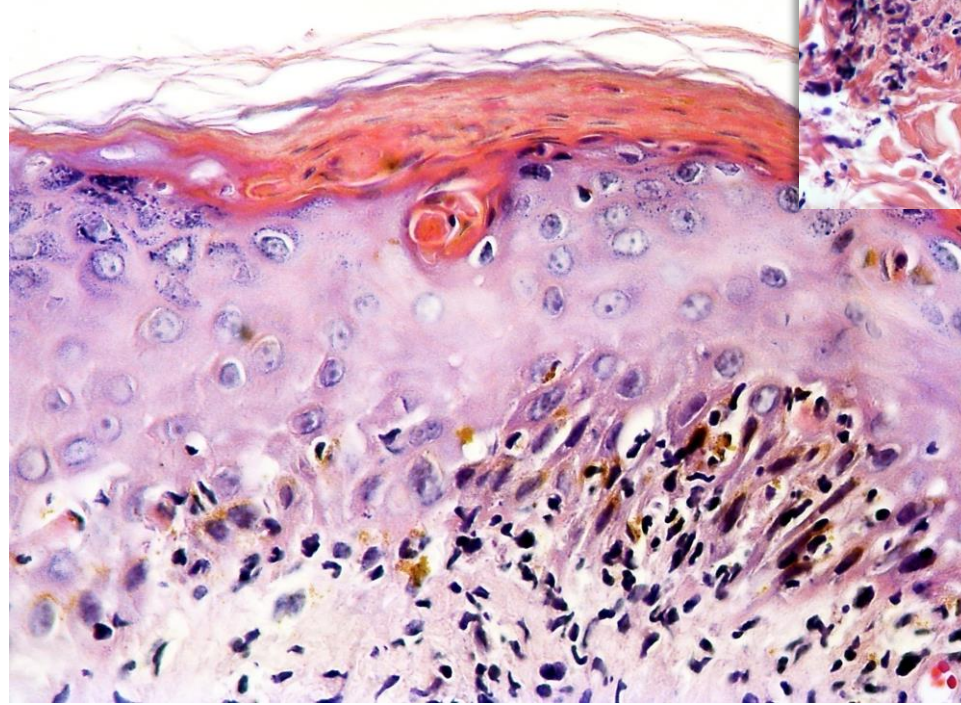
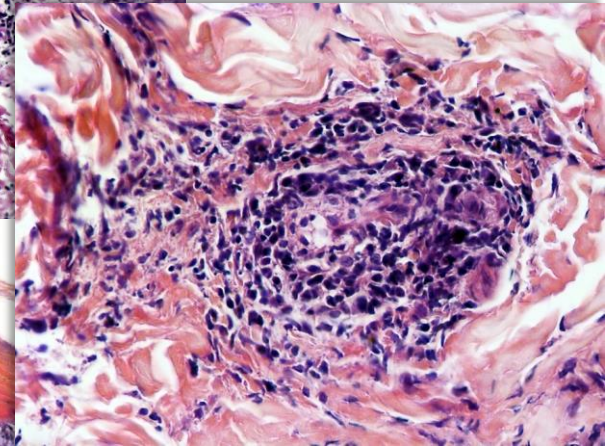
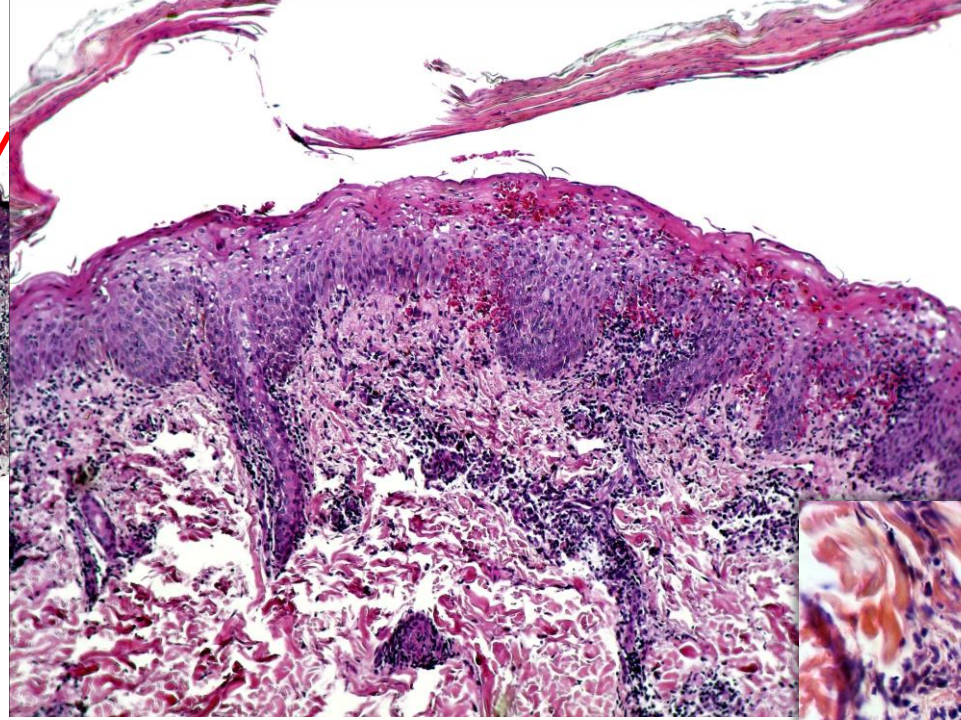
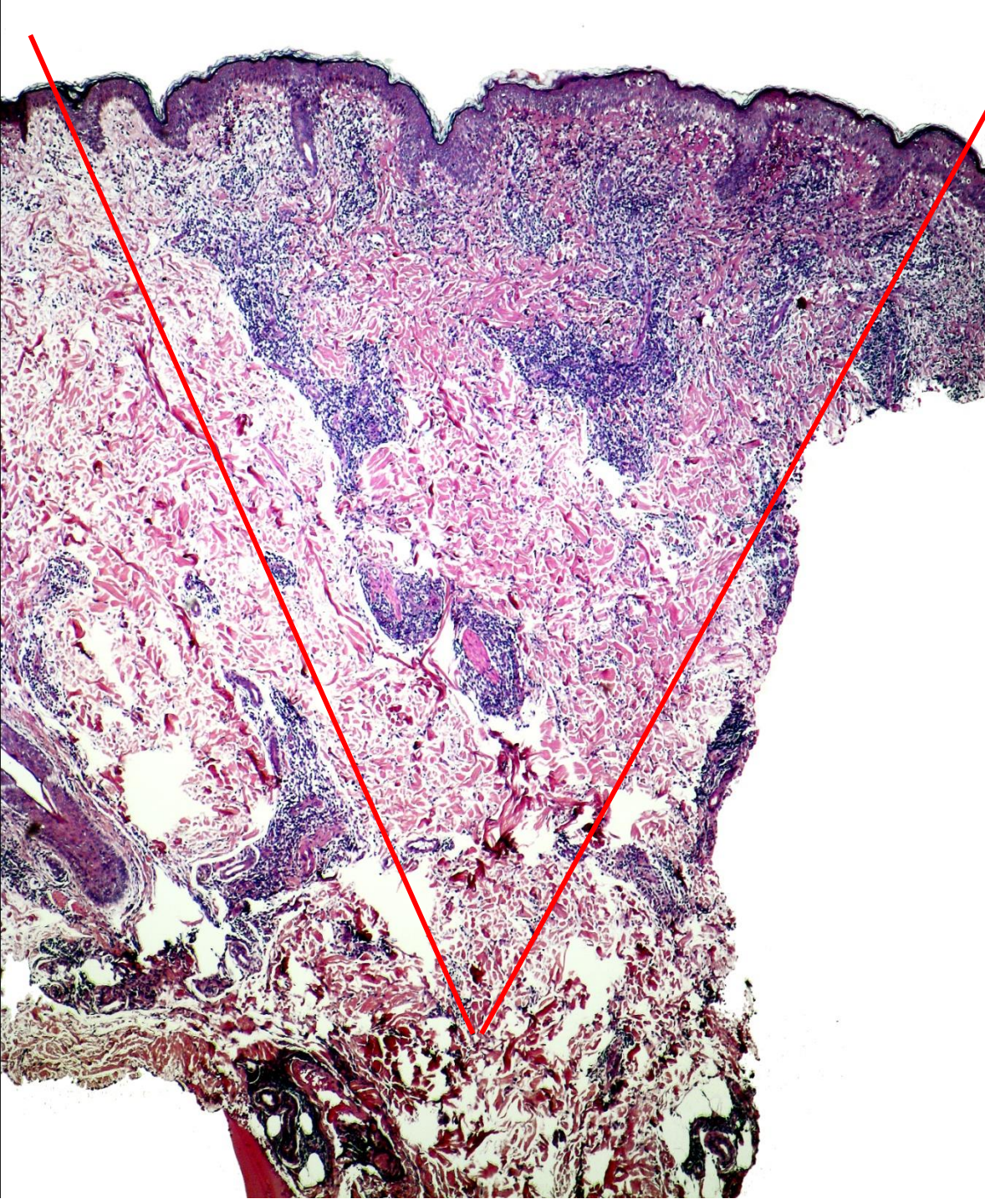
PLEVA

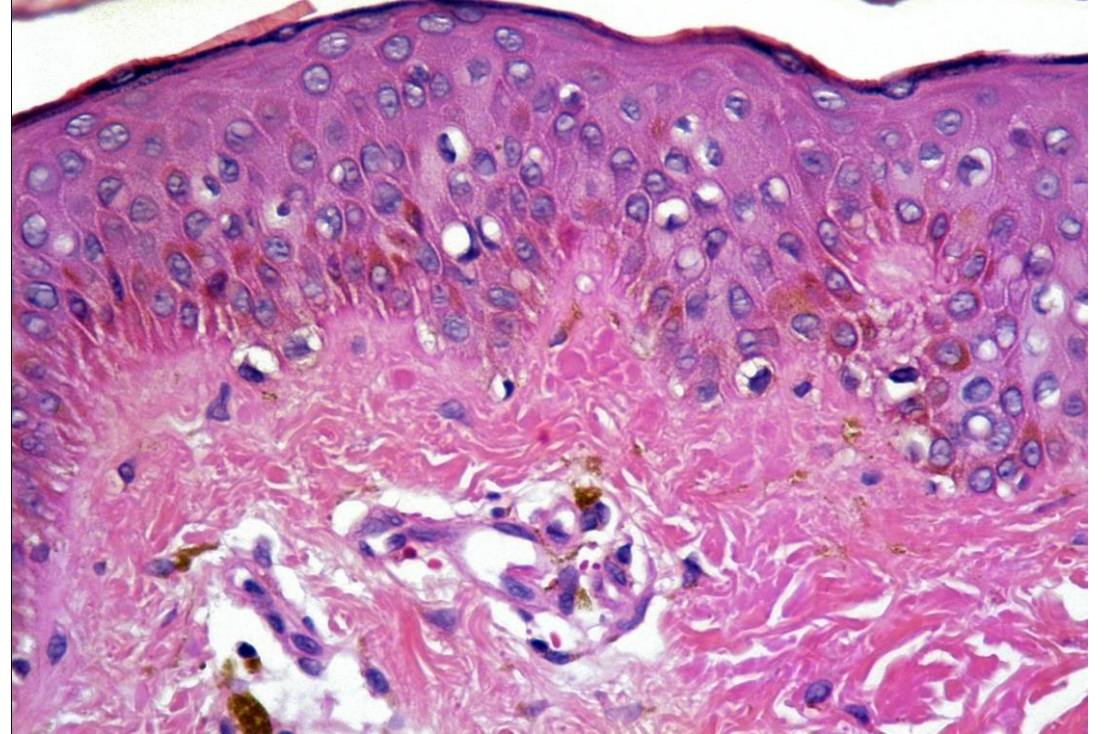
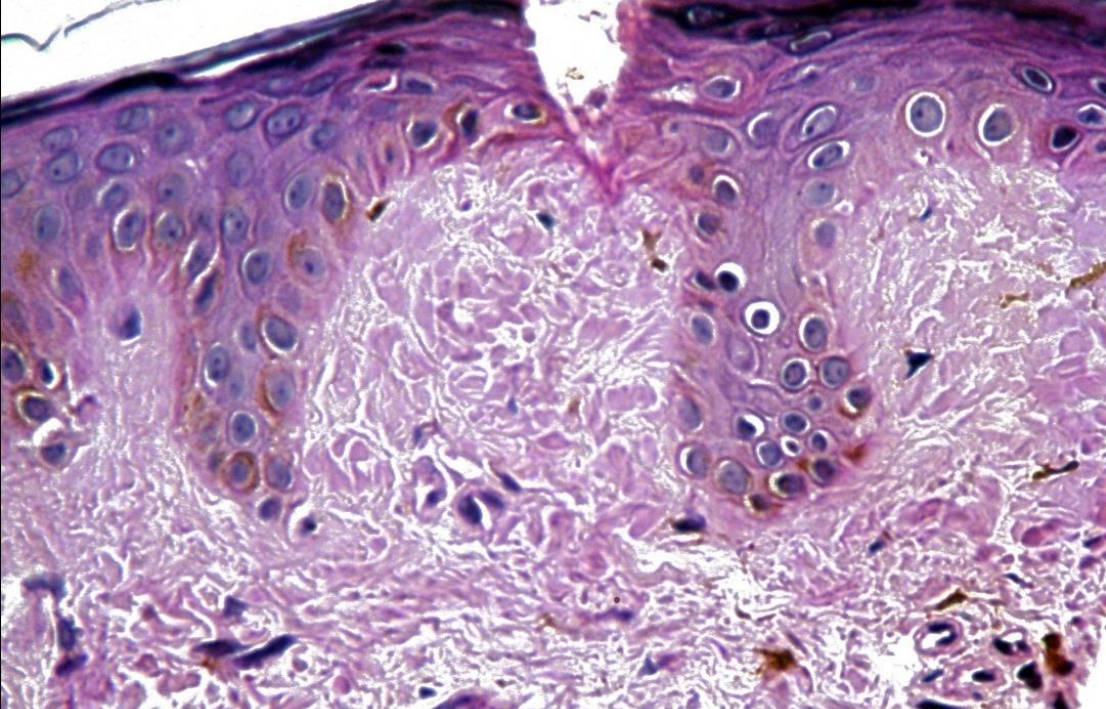
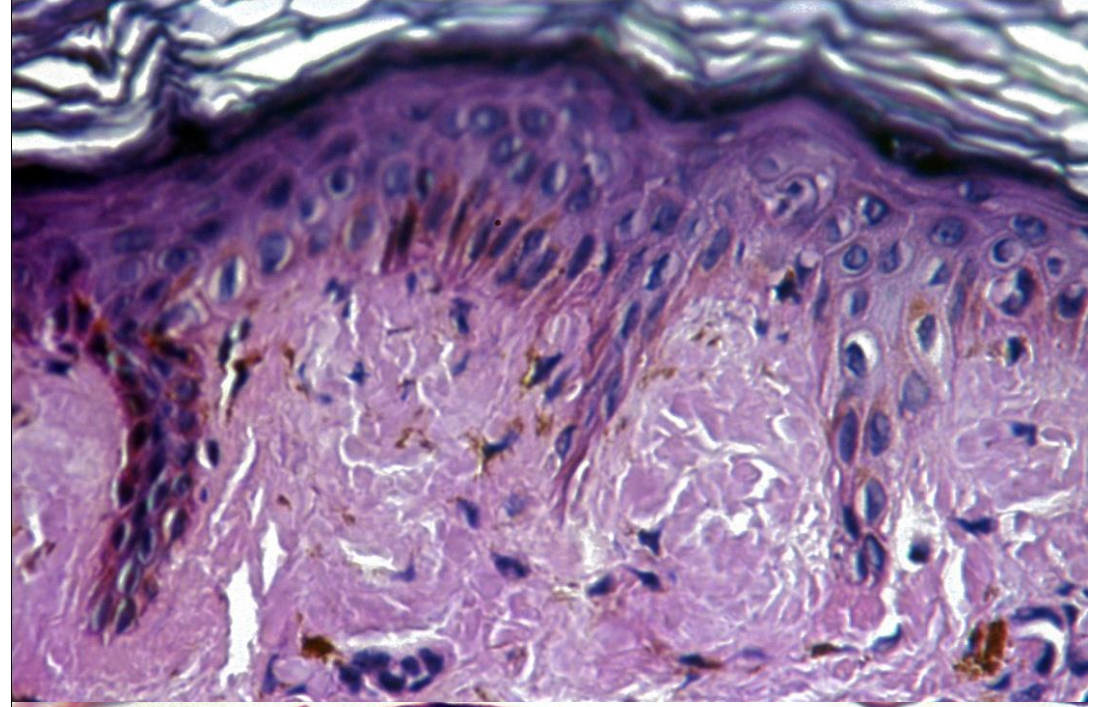
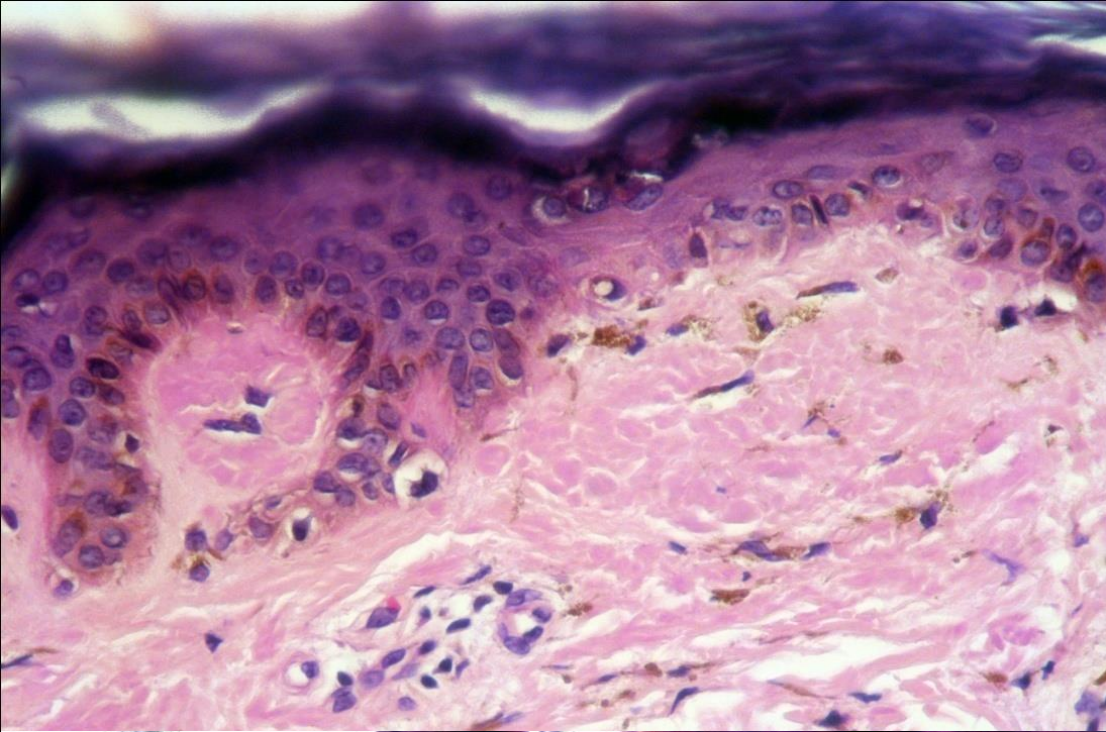


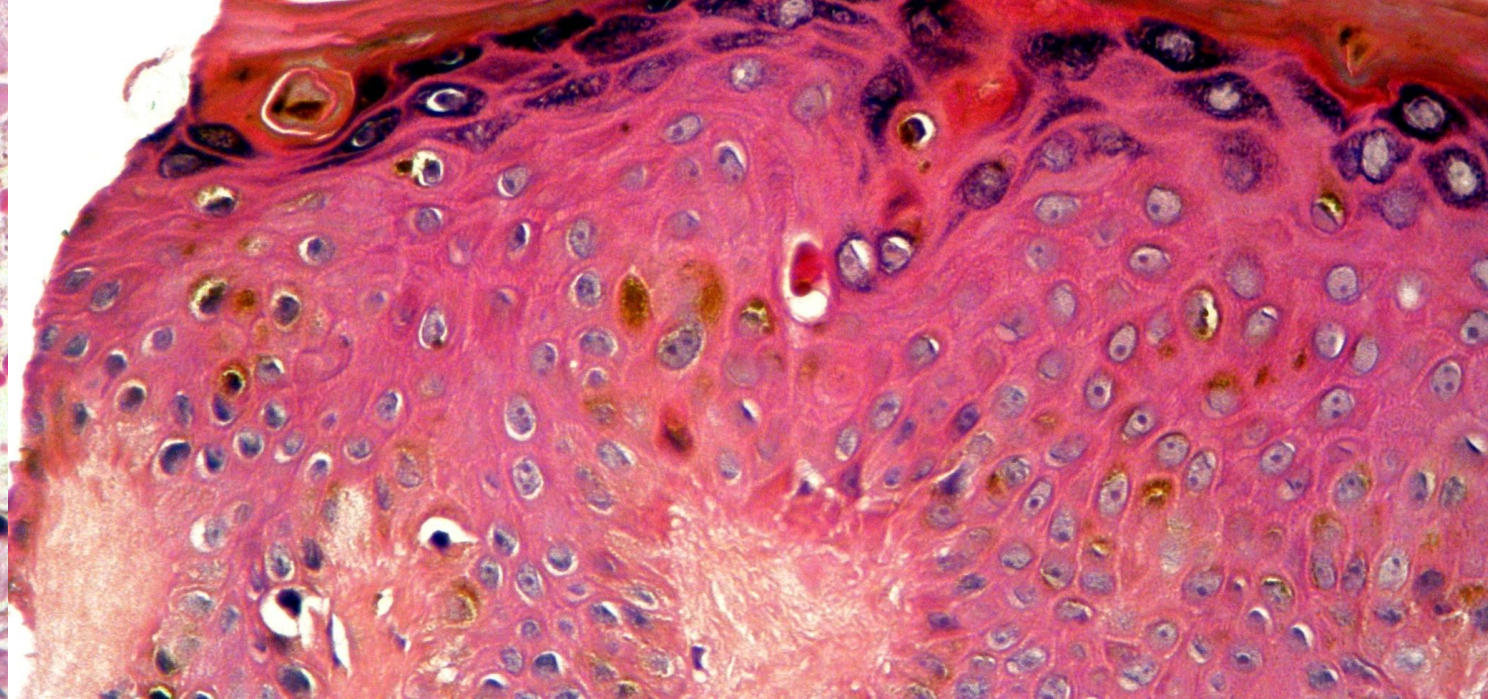
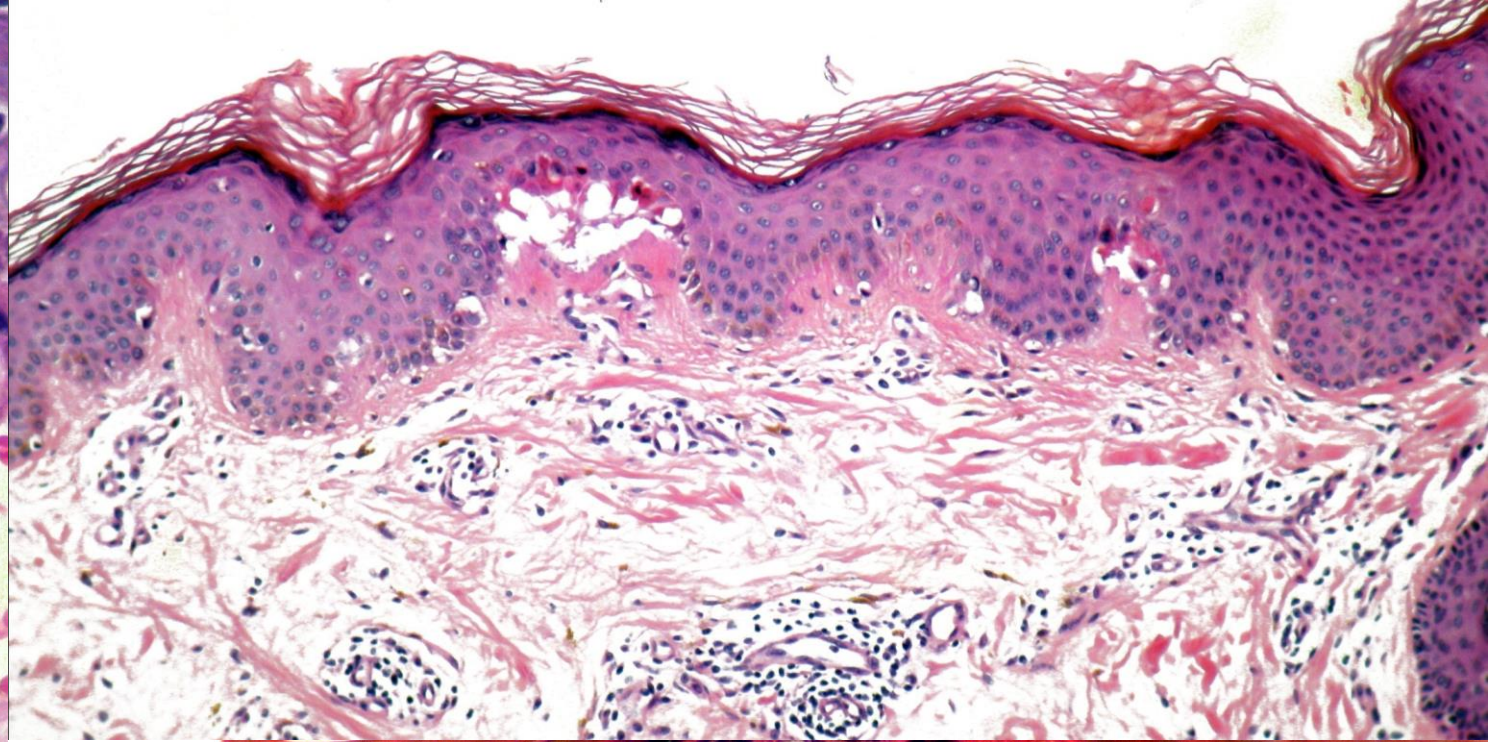
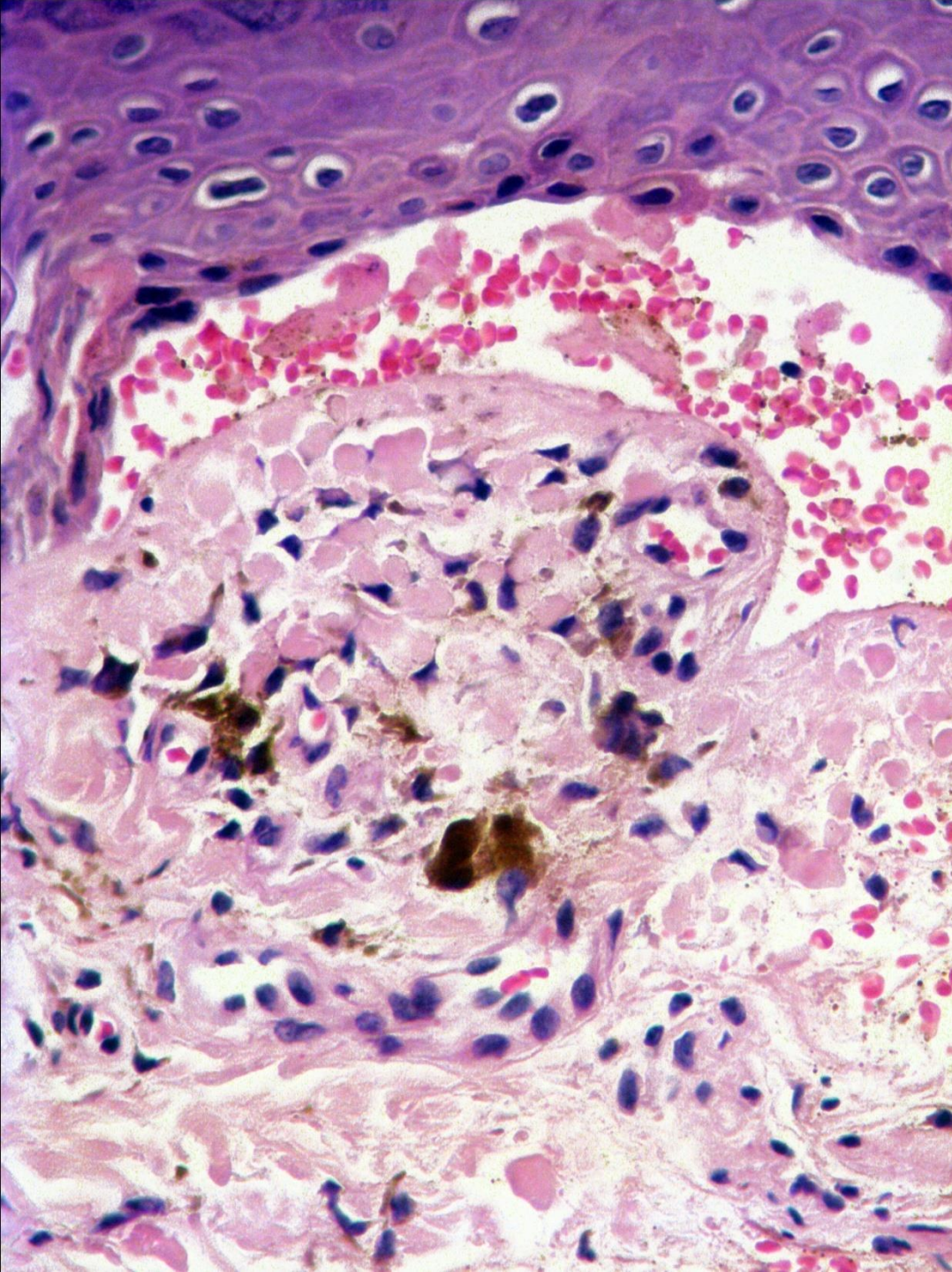
PLC

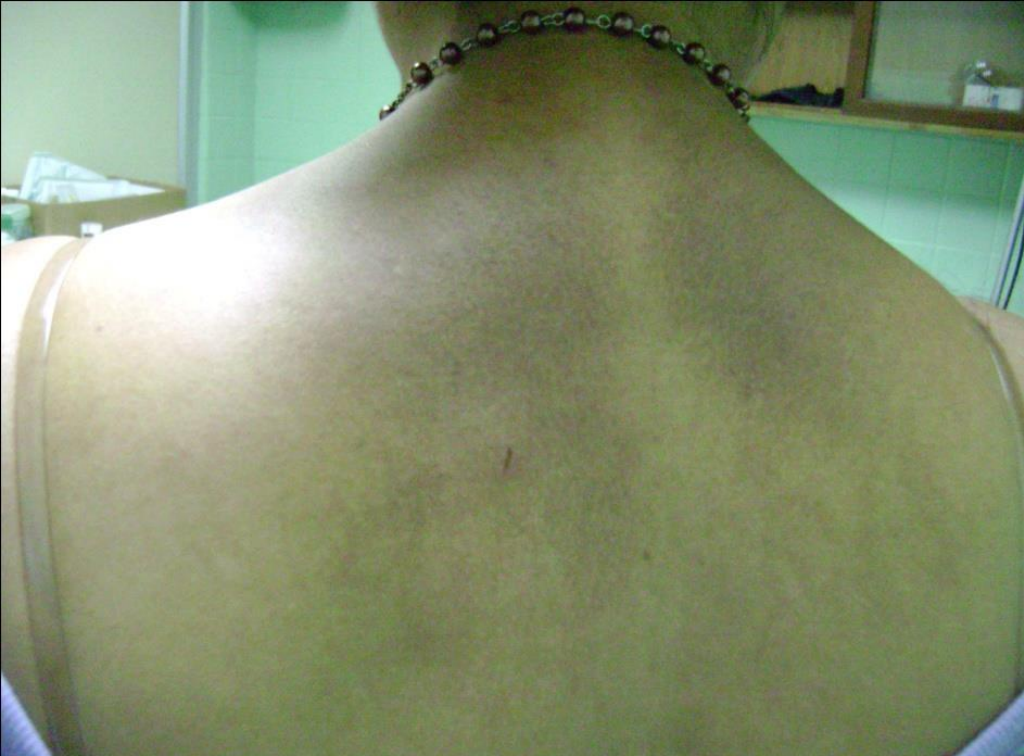











Amiloidosis cutánea primaria

